

## Case Report

# Late recurrence of a papillary thyroid carcinoma 37 years after hemithyroidectomy: Solitary, left cervical lymph node metastasis evident on fluorodeoxyglucose positron-emission tomography/computed tomography images revealing nodular uptake

**ABSTRACT**

In patients with well-differentiated papillary thyroid carcinoma (PTC), late recurrence is very rare. It is unusual that  $^{18}\text{F}$ -fluorodeoxyglucose positron-emission tomography/computed tomography (PET/CT) shows hypermetabolic lesions in patients with well-differentiated PTC metastases. We demonstrate an exceptional case exhibiting a first relapse 37 years after hemithyroidectomy to treat PTC. Recurrent metastasis of a PTC should be considered as a differential diagnosis even if the elapsed time from the initial treatment is great. A left cervical lymphadenopathy, which exceptionally exhibited a hypermetabolic lesion on PET/CT, should be considered a metastatically well-differentiated PTC.

**Keywords:** Late recurrence, papillary thyroid carcinoma, positron-emission tomography/computed tomography

**INTRODUCTION**

A differential diagnosis of left cervical lymphadenopathy may refer to metastases of various primary cancers. Clinicians may be reluctant to consider that left-sided cervical lymphadenopathy may be metastatic papillary thyroid carcinoma (PTC) in a patient who had undergone hemithyroidectomy 37 years ago to treat a PTC, with no intervening history of carcinoma relapse.<sup>[1-5]</sup>  $^{18}\text{F}$ -fluorodeoxyglucose positron-emission tomography/computed tomography (FDG PET/CT) is ineffective for the diagnosis of cervical node metastases of well-differentiated PTCs, being less sensitive in this regard than ultrasound or CT.<sup>[6,7]</sup> Clinicians often assume that left cervical lymphadenopathy revealing nodular uptake cannot be a metastasis of well-differentiated PTC because, in general, PET/CT reveals no hypermetabolic lesion in patients with such prior carcinomas.

**CASE REPORT**

In 2018, a 60-year-old male who had undergone left hemithyroidectomy with node resection to treat a PTC at the age of 23 years in 1981, and who had not received adjuvant therapy such as radioiodine therapy, underwent noncontrast-enhanced CT when he presented with diverticulitis but no neck symptoms. Left cervical lymphadenopathy was incidentally discovered [Figure 1a].

**HIROAKI KUNOGI, YUTAKA NAOI,  
TOSHIHARU MATSUMOTO<sup>1</sup>, YUTAKA OZAKI**

Departments of Radiology and <sup>1</sup>Pathology, Juntendo Nerima Hospital, Tokyo, Japan


**Address for correspondence:** Dr. Hiroaki Kunogi,  
Department of Radiology, Juntendo Nerima Hospital, 3-1-10,  
Takanodai, Nerima-ku, Tokyo 177-8521, Japan.  
E-mail: hkunogi@juntendo.ac.jp

**Submission:** 18-Sep-19, **Accepted:** 16-Nov-19, **Published:** 29-Jan-20

This is an open access journal, and articles are distributed under the terms of the Creative Commons Attribution-NonCommercial-ShareAlike 4.0 License, which allows others to remix, tweak, and build upon the work non-commercially, as long as appropriate credit is given and the new creations are licensed under the identical terms.

**For reprints contact:** reprints@medknow.com

**How to cite this article:** Kunogi H, Naoi Y, Matsumoto T, Ozaki Y. Late recurrence of a papillary thyroid carcinoma 37 years after hemithyroidectomy: Solitary, left cervical lymph node metastasis evident on fluorodeoxyglucose positron-emission tomography/computed tomography images revealing nodular uptake. *World J Nucl Med* 2020;19:155-8.

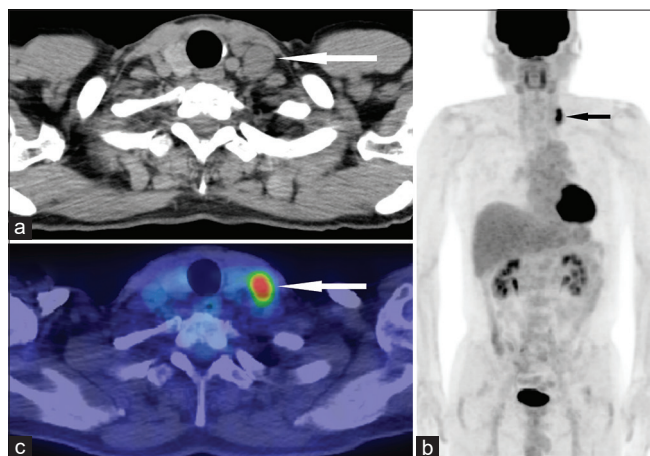
| Access this article online             |   |
|--|---|
| <b>Website:</b><br>www.wjnm.org        | <b>Quick Response Code</b><br> |
| <b>DOI:</b><br>10.4103/wjnm.WJNM_72_19 |   |

In 1981, the primary tumor with no tracheal invasion, which had a maximum diameter of 35 mm (no preoperative imaging result), was an encapsulated well-differentiated thyroid tumor featuring capsular invasion by tumor cells. Palpation and a blood sample (without thyroglobulin (Tg) value/imaging results) were performed semi-annually or annually until 10 years after resection. Follow-up ceased in 1991. From 1991 to 2018, no neck symptom suggesting recurrence was noticed.

In 2018, a blood sample, including thyroid-stimulating hormone (TSH), free triiodothyronine (FT3), free thyroxine (FT4), and Tg, as well as a lymph node (LN) biopsy and whole-body FDG-PET/CT were performed [Figure 1b], because PET/CT should be used for unknown primary tumors.<sup>[8]</sup> Differential diagnosis of the left cervical lymphadenopathy focused more on metastatic lung or head/neck cancer than metastatic PTC, even though the patient had a history of PTC. This was because the time elapsed from initial PTC treatment was very long (37 years), and late PTC recurrence is very rare (although PTC metastases can develop over 20 years after initial presentation). Therefore, PET/CT was the imaging modality of choice and not radioactive iodine scintigraphy. For FDG-PET/CT, after a 12-h fast, 352 MBq of FDG was intravenously injected, and the PET/CT was performed 1 h later, at which time the blood glucose level was 114 mg/dL. A cervical LN exhibited a hypermetabolic lesion with a maximum standardized uptake value of 7.01 [Figure 1c]. No hypermetabolic lesions were apparent in the right lobe of the thyroid, and no other lesion was detected. In other words, metastasis was evident in a left cervical node only,

as revealed by FDG-PET/CT. The serum TSH, FT3, FT4, and Tg values were 2.11  $\mu$ IU/mL, 2.98 pg/mL, 1.23 ng/mL, and 79.2 ng/mL, respectively. The biopsy specimen was pathologically diagnosed as metastatic, well-differentiated, PTC. A radioactive iodine scintigraphy was not performed.

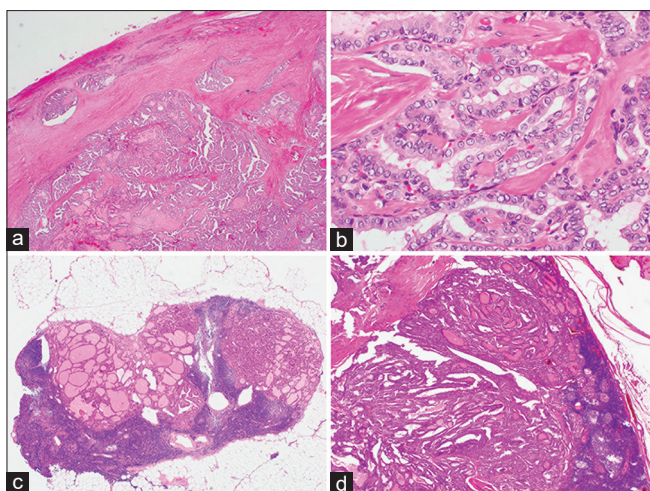
An ultrasound revealed a cyst in the right lobe of the thyroid, and the cyst was found not to be malignant on fine-needle aspiration cytology. The patient was concerned about preservation of thyroid function; we thus performed left neck node dissection with preservation of the right thyroid lobe. A metastatic PTC (3/14) was histologically confirmed. Adjuvant radioactive iodine therapy was not prescribed because this was an exceptional case of first relapse (i.e., a solitary cervical node metastasis 37 years after hemithyroidectomy). Adjuvant radioactive iodine therapy is not necessarily useful in such cases, although it improved the survival of patients with intermediate risk, well-differentiated PTCs after total thyroidectomy (the initial treatment).<sup>[9]</sup> Six months after the node dissection, the patient's TSH, FT3, FT4, and Tg values were 2.33  $\mu$ IU/ml, 3.01 pg/ml, 1.22 ng/ml, and 12.9 ng/ml, respectively. His Tg value had normalized. The pathology findings on both the initially resected thyroid and nodes (thus, the 1981 data) and the secondary resected node (the 2018 data) were reviewed after the secondary LN resection [Figure 2]. A nodal recurrence with no dedifferentiation of the PTC was confirmed. As of July 2019 (the time of the last follow-up), the patient is healthy and no metastatic neck node is palpable 12 months after the nodal resection. His blood Tg level, measured 12 months after the nodal resection, was normal (16.3 ng/ml), although the Tg level may not be a reliable tumor marker when the volume of thyroïdal tissue is very large.



**Figure 1:** Computed tomography (a) revealed no neck symptom, but evidenced left cervical lymphadenopathy (white arrow); we thus performed whole-body 18F-fluorodeoxyglucose positron-emission tomography/computed tomography. On whole-body 18F-fluorodeoxyglucose positron-emission tomography/computed tomography (b), a single hypermetabolic lesion was detected in a left cervical node (black arrow); no other lesion was evident. A single hypermetabolic lesion (white arrow) was identified on the left side of the neck (c)

## DISCUSSION AND CONCLUSIONS

There is no recommendation as to how long patients with a PTC should be followed up after thyroidectomy because late recurrences are very rare. In a study, spanning six decades (1940–1999) that followed PTC patients treated at the Mayo Clinic, the tumor recurrence rates were 11% at 10 years, 13% at 20 years, and 14% at 25 years for a subgroup of 2305 patients with localized disease that was completely excised at the initial surgery.<sup>[10]</sup> Almost all recurrences occurred by 10 years. Nwatsock *et al.* reported a case of renal metastasis revealing follicular variant PTC recurrence 24 years after the initial therapy (total thyroidectomy, LN dissection, and radioiodine therapy).<sup>[11]</sup> Amoako-Tuffour *et al.* demonstrated a nodal recurrent case of PTC 43 years after the initial treatment (total thyroidectomy and radioactive iodine ablation).<sup>[12]</sup> Here, we report the case of a male who



**Figure 2: Histological features of the initially resected thyroid tumor and the lymph node (a-c). (a) An encapsulated thyroid tumor featuring capsular invasion by tumor cells (H and E, ×20). (b) Histology of the papillary carcinoma (original thyroid tumor). Note the papillary structure of the tumor cells, the clarity of the nuclei, and the ground-glass presentation featuring occasional grooves (H and E, ×400). (c) Metastasis of the papillary carcinoma to a lymph node (H and E, ×40) (d) Histology of the lymph node resected 37 years after resection of the thyroid tumor. Note the presence of papillary carcinoma metastasis in the lymph node (H and E, ×40)**

experienced his first relapse 37 years after hemithyroidectomy with no adjuvant therapy.

PET/CT revealed nodular uptake in the present case with a metastatically well-differentiated PTC. PET/CT has been reported to be less sensitive and less effective than ultrasound or CT in terms of PTC detection when used to diagnose cervical node metastases.<sup>[6,7]</sup> In general, PET/CT does not detect hypermetabolic lesions in patients with metastatically well-differentiated PTCs. Hypermetabolism of PTC was an interesting feature of our case.

We describe a first relapse (solitary left cervical node metastasis) incidentally detected by CT 37 years after hemithyroidectomy with node resection performed to treat PTC. The carcinoma may have already metastasized to the current LN in 1981 (37 years previously), because the LN metastatic frequency of papillary thyroid microcarcinomas is high (64.1%).<sup>[13]</sup>

In conclusions, we report an exceptional case exhibiting a first relapse 37 years after hemithyroidectomy to treat PTC. Notably, the metastatically well-differentiated PTC was hypermetabolic. Recurrent metastasis of a PTC should be considered as a differential diagnosis even if the elapsed time from the initial treatment is great (e.g., 37 years). A hypermetabolic lesion (even if PET/CT reveals nodular uptake) should be considered a metastatically well-differentiated PTC, although PET/CT, in general,

does not detect hypermetabolic lesions in patients with well-differentiated PTC metastases.

#### Patient consent for publication

Written informed consent was obtained from the patient for publication of this case report, including accompanying images.

#### Declaration of patient consent

The authors certify that they have obtained all appropriate patient consent forms. In the form, the patient has given his consent for his images and other clinical information to be reported in the journal. The patient understands that name and initials will not be published and due efforts will be made to conceal identity, but anonymity cannot be guaranteed.

#### Financial support and sponsorship

Nil.

#### Conflicts of interest

There are no conflicts of interest.

#### REFERENCES

1. Bilimoria KY, Zanocco K, Sturgeon C. Impact of surgical treatment on outcomes for papillary thyroid cancer. *Adv Surg* 2008;42:1-2.
2. Matsuzo K, Sugino K, Masudo K, Nagahama M, Kitagawa W, Shibuya H, *et al.* Thyroid lobectomy for papillary thyroid cancer: Long-term follow-up study of 1,088 cases. *World J Surg* 2014;38:68-79.
3. Kim MJ, Lee MC, Lee GH, Choi HS, Cho SW, Kim SJ, *et al.* Extent of surgery did not affect recurrence during 7-years follow-up in papillary thyroid cancer sized 1-4 cm: Preliminary results. *Clin Endocrinol* 2017;87:80-6.
4. Sciuto R, Romano L, Rea S, Marandino F, Sperduti I, Maini CL. Natural history and clinical outcome of differentiated thyroid carcinoma: a retrospective analysis of 1503 patients treated at a single institution. *Ann Oncol* 2009;20:1728-35.
5. Takano T. Natural history of thyroid cancer [Review]. *Endocr J* 2017;64:237-44.
6. Ahn JE, Lee JH, Yi JS, Shong YK, Hong SJ, Lee DH, *et al.* Diagnostic accuracy of CT and ultrasonography for evaluating metastatic cervical lymph nodes in patients with thyroid cancer. *World J Surg* 2008;32:1552-8.
7. Choi WH, Chung YA, Han EJ, Sohn HS, Lee SH. Clinical value of integrated [18F] fluoro-2-deoxy-D-glucose positron emission tomography/computed tomography in the preoperative assessment of papillary thyroid carcinoma: Comparison with sonography. *J Ultrasound Med* 2011;30:1267-73.
8. Fletcher JW, Djulbegovic B, Soares HP, Siegel BA, Lowe VJ, Lyman GH, *et al.* Recommendations on the use of 18F-FDG PET in oncology. *J Nucl Med* 2008;49:480-508.
9. Ruel E, Thomas S, Dinan M, Perkins JM, Roman SA, Sosa JA. Adjuvant radioactive iodine therapy is associated with improved survival for patients with intermediate-risk papillary thyroid cancer. *J Clin Endocrinol Metab* 2015;100:1529-36.
10. Hay ID, Thompson GB, Grant CS, Bergstralh EJ, Dvorak CE, Gorman CA, *et al.* Papillary thyroid carcinoma managed at the Mayo Clinic during six decades (1940-1999): temporal trends in initial therapy and long-term outcome in 2444 consecutively treated patients. *World J*

- Surg 2002;26:879-85.
11. Nwatsock JF, Taïeb D, Zok FD, Mundler O. Late Recurrences of Thyroid Carcinoma 24 Years after a Complete Remission: When Monitoring Should be Stopped? *World J Nucl Med* 2012;11:42-3.
  12. Amoako-Tuffour Y, Graham ME, Bullock M, Rigby MH, Trites J, Taylor SM, *et al.* Papillary thyroid cancer recurrence 43 Years following Total Thyroidectomy and radioactive iodine ablation: a case report. *Thyroid Res* 2017;10:8.
  13. Wada N, Duh QY, Sugino K, Iwasaki H, Kameyama K, Mimura T, *et al.* Lymph node metastasis from 259 papillary thyroid microcarcinomas: frequency, pattern of occurrence and recurrence, and optimal strategy for neck dissection. *Ann Surg* 2003;237:399-407.