

## Original Article

# Diagnostic value of sentinel lymph node scintigraphy and 2-[<sup>18</sup>F]-fluoro-2-deoxy-D-glucose positron emission tomography/computed tomography in the detection of metastatic lymph nodes in patients with early-stage cervical cancer

**ABSTRACT**

Cervical cancer is staged clinically using the International Federation of Gynaecology and Obstetrics staging system. Although lymph node status does not form part of the staging, it has important prognostic and potential therapeutic implications. The aim of the study was to evaluate the role of sentinel lymph node (SLN) scintigraphy and 2-[<sup>18</sup>F]-fluoro-2-deoxy-D-glucose positron emission tomography/computed tomography (<sup>18</sup>F-FDG PET/CT) in detecting lymph node metastases in patients with early-stage cervical cancer. Thirty-six patients with early-stage cervical cancer underwent SLN detection during primary operation. Of the 36 patients, 28 patients underwent <sup>18</sup>F-FDG PET/CT before surgery. The <sup>18</sup>F-FDG PET/CT images were analyzed with the histopathological findings as the reference standard. The diagnostic performance of <sup>18</sup>F-FDG PET/CT in the detection of nodal disease was reported in terms of accuracy value. The SLN detection rate was the highest (91.7%) using the combined method (lymphoscintigraphy, intraoperative gamma probe, and blue dye). Seven of the thirty-six patients had lymph node involvement (19.4%), of which five had preoperative <sup>18</sup>F-FDG PET/CT imaging. On overall patient-based analysis, the sensitivity, specificity, positive predictive value, negative predictive value (NPV), and accuracy of <sup>18</sup>F-FDG PET/CT were 40.0%, 78.3%, 28.6%, 85.7%, and 71.4%, respectively. The combination of radiolabeled nanocolloid with blue dye is safe and reliable and allows successful detection of SLNs in patients with early-stage cervical cancer in a population with high prevalence of human immunodeficiency virus. The specificity and NPV of <sup>18</sup>F-FDG PET/CT are high and can be used in conjunction with SLN biopsy.

**Keywords:** 2-[<sup>18</sup>F]-fluoro-2-deoxy-D-glucose, cervical cancer, positron emission tomography/computed tomography, sentinel lymph node

**INTRODUCTION**

Cervical cancer is the fourth most common cancer among women worldwide. In South Africa, it is the second most common cancer with approximately 7735 new cases diagnosed annually (estimations for 2012).<sup>[1]</sup> South Africa has the highest rate of human immunodeficiency virus (HIV) infection worldwide with an estimated 7.52 million people living with HIV in 2018. An estimated fifth of South African women in their reproductive ages (15–49 years) are HIV positive.<sup>[2]</sup> Previous studies have shown that women with HIV

**FLORETTE REYNEKE, LEON CORNELIUS SNYMAN<sup>1</sup>, ISMAHEEL LAWAL, THABO LENGANA, MARIZA VORSTER, MIKE SATHEKGE**

Department of Nuclear Medicine, University of Pretoria and Steve Biko Academic Hospital, <sup>1</sup>Department of Obstetrics and Gynaecology, University of Pretoria and Kalafong Hospital, Pretoria, South Africa

**Address for correspondence:** Prof. Mike Sathekge, Department of Nuclear Medicine, University of Pretoria and Steve Biko Academic Hospital, Private Bag X169, Pretoria 0001, South Africa.  
E-mail: mike.sathekge@up.ac.za

**Submission:** 03-Oct-19, **Accepted:** 07-Nov-19, **Published:** 22-Jul-20

This is an open access journal, and articles are distributed under the terms of the Creative Commons Attribution-NonCommercial-ShareAlike 4.0 License, which allows others to remix, tweak, and build upon the work non-commercially, as long as appropriate credit is given and the new creations are licensed under the identical terms.

**For reprints contact:** WKHLRPMedknow\_reprints@wolterskluwer.com

**How to cite this article:** Reyneke F, Snyman LC, Lawal I, Lengana T, Vorster M, Sathekge M. Diagnostic value of sentinel lymph node scintigraphy and 2-[<sup>18</sup>F]-fluoro-2-deoxy-D-glucose positron emission tomography/computed tomography in the detection of metastatic lymph nodes in patients with early-stage cervical cancer. *World J Nucl Med* 2020;19:240-5.

**Access this article online****Website:**

www.wjnm.org

**DOI:**

10.4103/wjnm.WJNM\_74\_19

**Quick Response Code**

are at an increased risk of developing cervical intra-epithelial neoplasms and cervical cancer.<sup>[3-5]</sup>

Gynecological cancers are staged using the International Federation of Gynaecology and Obstetrics (FIGO) classification. Vulva, endometrial, and ovarian cancers are staged surgically and therefore include lymph node status. Conventionally, cervical cancer was staged clinically; information on metastatic lymph node involvement was not included as part of FIGO staging of disease.<sup>[6]</sup> Lymph node involvement is, however, an important risk factor for disease recurrence and death in cervical cancer patients.<sup>[7]</sup>

Knowledge of metastatic lymph node involvement is crucial to plan optimal treatment strategies in patients with early-stage disease. Radical hysterectomy with pelvic (with or without paraaortic) lymphadenectomy is an essential part of the management in this group of patients as it provides histological information on metastatic involvement of regional lymph nodes. Regardless of the mode of surgery (open or laparoscopic), lymphadenectomy is associated with numerous complications including increased blood loss, prolonged duration of surgery, formation of lymphoceles, nerve or vascular injuries, and lymphedema of the lower limbs.<sup>[8,9]</sup>

In Stage 1B1, the prevalence of lymph node metastases is approximately 15%.<sup>[10]</sup> The majority of patients will therefore not benefit from lymphadenectomy which could potentially be avoided if the lymph node status is known before surgery. To reduce the complications associated with lymphadenectomy, the concept of a sentinel lymph node (SLN) has been developed in 1977 for penile cancer.<sup>[11]</sup> This was subsequently adopted in melanoma patients, breast cancer, and most recently in gynecology.<sup>[12,13]</sup>

With regard to imaging, magnetic resonance imaging (MRI) has improved the definition of the tumor volume, the involvement detection of the parametria, and staging of the disease. The sensitivity of this imaging modality in the detection of nodal metastases is, however, quite low, ranging from 25% to 65% with a specificity of 70%–100%. One of the limitations of MRI (as well as computed tomography [CT]) is the size-based characterization of lymph nodes where metastatic involvement is considered only when the diameter of the short axis is > 1 cm. This leads to well-known false negative and false positive results. Functional imaging with positron emission tomography (PET) using the radiolabeled glucose analog, 2-[<sup>18</sup>F]-fluoro-2-deoxy-D-glucose PET (<sup>18</sup>F-FDG-PET), detects areas of increased glucose metabolism such as seen in malignant tumors.<sup>[14,15]</sup>

This study aimed to evaluate the diagnostic value of SLN scintigraphy and <sup>18</sup>F-FDG PET/CT in the detection of lymph node metastases in early-stage cervical cancer in the setting with high incidence of HIV.

## MATERIALS AND METHODS

### Patients

This prospective study included women with histologically confirmed early-stage cervical (clinically staged as FIGO IA to IIA). A total of 36 consecutive patients were recruited and all patients underwent SLN detection followed by laparoscopic or open radical hysterectomy and pelvic lymphadenectomy. Most women scheduled for surgery underwent preoperative <sup>18</sup>F-FDG PET/CT imaging with the aim of assessing possible metastases to pelvic and paraaortic lymph nodes. The human research ethics committee of our institution approved this study (approval number 434/2014). All participants gave written informed consent to participate in the study and for anonymous publication of their data for research purpose.

### Sentinel lymph node detection Sentinel lymph node scintigraphy

On the day before the surgery, 74–185 MBq (2–5 mCi) of <sup>99m</sup>Tc-nanocolloid was injected peritumorally at a 0.5–1.0 cm depth into intact-appearing cervical epithelium using 26G hypodermic needles. All sentinel lymph scintigraphy studies were performed on a General Electric Hawkeye-1 single-photon emission CT (SPECT)/CT gamma camera (Haifa-Israel) with images acquired into a 128 × 128 matrix using 60 frames at 25 s/frame. The images were displayed on a Xeleris workstation (General Electric, Haifa-Israel) and for SPECT images a count optimized filtered back projection reconstruction was used.

Planar images in the anterior and posterior projections were acquired immediately following injection as well as at 2 h post tracer injection. CT imaging was performed after the SPECT study and this was performed immediately after identifying the SLN on the planar images. Images were registered and fused using fusion software provided on the Xeleris workstation. The planar and SPECT images were interpreted by two experienced nuclear medicine physicians.

### Intraoperative procedure

After induction of general anesthesia, combined superficial and deep cervical injection of blue dye solution (such as Methylene Blue 1%) was injected peritumorally in intact-appearing epithelium of the uterine cervix. Intraoperatively, the pelvic (and paraaortic) lymph nodes were examined for hot and/or blue lymph nodes. The examination started before opening the retro-peritoneal space by looking for possible blue stained lymph nodes/vessels and examination for any hot

nodes. These were defined as nodes with a radioactive count of >5 times the background count *in vivo* and >10 times *ex vivo* using the laparoscopic gamma probe. This was followed by excision of any blue and/or hot nodes. These nodes were sent for histological examination separately with the position and radioactive counts stated.

A complete pelvic lymphadenectomy was performed (including lymphadenectomy of any other site which contained at least one SLN, e.g. presacral). These lymph nodes were sent for histological examination as non-SLN including the site of origin.

### 2-[<sup>18</sup>F]-fluoro-2-deoxy-D-glucose positron emission tomography/computed tomography

Most women scheduled for surgery agreed to undergo preoperative <sup>18</sup>F-FDG PET/CT imaging with the aim of assessing possible metastases to pelvic and paraaortic lymph nodes. Women who did not have <sup>18</sup>F-FDG PET/CT were not excluded from the rest of the study.

The study participants were imaged on a dedicated hybrid Biograph 40 PET/CT scanner (Siemens, Erlangen, Germany) following standard preparation of the Nuclear Medicine Department at Steve Biko Academic Hospital. The participants were requested to fast for a minimum of 4 h prior to the study. Blood glucose was obtained with a portable capillary glucometer with a cutoff for inclusion of <11.0 mmol/L. The activity of FDG injected intravenously was calculated based on the weight of the patient using the formula:  $([\text{body weight}/10] + 1) \times 37 \text{ MBq}$ .

Vertex to mid-thigh imaging started 60 min after injection of the tracer to allow for maximum uptake and background clearance. The images were acquired in a three-dimensional mode with a 3-min emission scan for each of the 9 bed positions. In the absence of contraindications, CT was acquired with intravenous contrast using non-ionic contrast material (Ultravist®, Bayer Vital GmbH) injected at a rate of 2 ml/s. The images were reconstructed with and without attenuation correction (CT based) using ordered subset expectation maximization to yield axial, sagittal, and coronal slices of PET, CT, and PET/CT images. The images were analyzed by two experienced nuclear medicine physicians. Any area of increased <sup>18</sup>F-FDG accumulation which corresponded to a lymph node on CT was considered as abnormal and disagreements were resolved by an independent third reviewer. Findings on the images were verified using histological confirmation.

### Statistical analysis

Simple descriptive statistics (absolute numbers and percentages) were used to report the patient characteristics

and sites of SLN/nodal involvement. The values were reported as means with standard deviations where the data had a normal distribution. Where the data were not normally distributed, the values were reported as median values with ranges.

## RESULTS

Thirty-six women with cervical carcinoma of FIGO Stage IA1 to IIA underwent SLN detection as per the details of which are summarized in Table 1. The median age of the cohort was 46 years (range: 33–77 years). The majority of the women in our study had a tumor smaller than 2 cm, which most likely accounts for the relatively low incidence of nodal involvement (19.4%).

### Sentinel node detection

An SLN was detected using the combined method (lymphoscintigraphy, intraoperative gamma probe, and blue dye) in 33 (91.7%) of the 36 women [Table 2]. Lymphoscintigraphy detected an SLN in 31 (86.1%) of the 36 cases and the gamma probe detected an SLN in 25 (69.4%)

**Table 1: Clinical patient and tumor characteristics**

Characteristic	Report
Total number of women (n)	36
Age, Median, yrs	46 (range, 33-77)
HIV status, n (%)	
Positive	22 (61)
Negative	14 (39)
CD4 count, Median, cells/uL	480 (43-950)
FIGO stages, n (%)	
Stage IA2	1 (3)
Stage IB1	27 (75)
Stage IB2	3 (8)
Stage IIA1	4 (11)
Stage IIA2	1 (3)
Histology, n (%)	
High grade squamous intra-epithelial lesion	8 (22)
Squamous cell carcinoma	25 (69)
Clear cell carcinoma	1 (3)
Adenocarcinoma	1 (3)
Adenosquamous carcinoma	1 (3)
Patients with lymph node metastases	6 (17)
Tumor size, mm	
<20	21 (58)
>20	15 (42)

**Table 2: Sentinel lymph node (SLN) detection**

	No. of patients	Percent
Detection rate of SLN using combined method	33/36	91.7
Detection rate of SLN by lymphoscintigraphy alone	31/36	86.1
Detection rate of SLN by gamma probe alone	25/36	69.4
Presence of blue dye in SLN	25/36	69.4
Unilateral detection of SLN	17/31	54.8
Bilateral detection of SLN	14/31	45.2

of the 36 cases. This was comparable to the visualization of blue dye in the SLN during surgery being found in 25 (69.4%) of the 36 cases. In our study, an SLN was detected unilaterally in 17 (54.8%) women and bilateral SLNs were detected in 14 (45.2%) women.

A total of 61 lymph nodes were detected in the 31 women (mean 1.96 nodes per patient, range, 1–4). The sites for SLN location were the obturator fossa (31.1%), external iliac region (26.2%), the internal iliac region (22.9%), and common iliac region (13.1%). Three of the SLNs were detected in the presacral region (4.9%) and one in the parametrium (1.6%).

Seven patients had lymph node metastases [Table 3]. Three patients showed metastases in SLNs only, two of the three patients in whom no SLNs were detected had pelvic lymph node metastases and two patients had extensive metastases in bulky nonsentinel nodes.

### Positron emission tomography/computed tomography findings

Twenty-eight women of the whole patient group underwent a preoperative <sup>18</sup>F-FDG PET/CT to assess for possible lymph node involvement. In this subgroup of patients, five had lymphatic metastases. PET/CT showed hypermetabolic lymph nodes in seven patients. Two of these had metastases, one detected in the SLN biopsy. Among the five false positive cases, one had tuberculous adenitis with the other four as reactive nodes [Figure 1]. One patient who had a negative PET/CT had micrometastases on histology and the SLN biopsy. On overall patient-based analysis, the sensitivity, specificity, positive predictive value (PPV), negative predictive value (NPV), and accuracy of PET/CT for pelvic LN metastases were 40.0%, 78.3%, 28.6%, 85.7%, and 71.4%, respectively.

### DISCUSSION

The importance of lymph node status in the treatment and prognosis of patients with cervical cancer is well established.<sup>[9,14-17]</sup> In stage IB1 cervical cancer, the prevalence of lymph node involvement is approximately 15% which means that up to 85% of these patients will not benefit

therapeutically from lymphadenectomy.<sup>[10]</sup> SLN biopsy is a diagnostic technique used to identify and examine a targeted lymph node sample instead of having to perform a complete lymphadenectomy. Different mapping techniques have been reported for SLN localization. The most common methods are blue dye and radioisotope labeling using <sup>99m</sup>Tc or a combination of the two. According to published literature, the combined technique is favored in identifying the SLN. In 2008, Altgassen *et al.*, during a multicenter pioneer study, reported a markedly higher detection rate with the combined method (93.5%) compared to blue dye alone (82%).<sup>[16]</sup> More recent studies conducted by Lécuru *et al.* and Cormier *et al.*

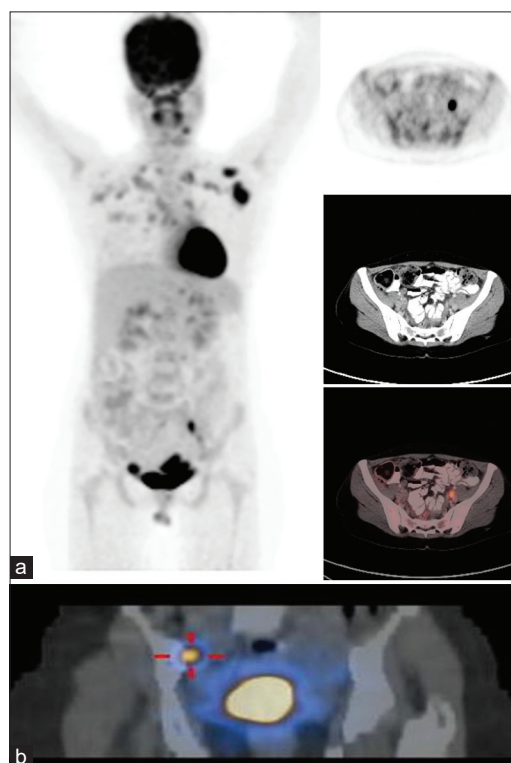


Figure 1: A 39-year-old female patient with cervical cancer (Federation of Gynaecology and Obstetrics Stage I B2). She is retroviral disease (RVD) reactive with a CD4 count of 600 cells/ $\mu$ L. Lymphoscintigraphy done the day before surgery (a) revealed a sentinel lymph node in the right internal iliac region. Preoperative 2-[<sup>18</sup>F]-fluoro-2-deoxy-D-glucose positron emission tomography/computed tomography (b) demonstrated a hypermetabolic left internal iliac lymph node which showed features on histology consistent with tuberculous lymphadenitis

Table 3: Details of patients with lymph node involvement

FIGO stage	Histological Subtype	Tumor Size	Type of +ve LN (number)	LVSI
IB1	Adenocarcinoma	>2cm	SLN (2)	Yes
IB1	Squamous cell carcinoma	<2cm	NSLN (3)	No
IIA1	Squamous cell carcinoma with neuroendocrine differentiation	>2cm	SLN (4)	Yes
IB1	Squamous cell carcinoma	<2cm	NSLN (1)	Yes
IB2	Squamous cell carcinoma	>2cm	NSLN (1)	Yes
IB1	Squamous cell carcinoma	<2cm	NSLN (3)	Yes
IB1	Squamous cell carcinoma	>2cm	SLN (1)	Yes

both showed superior detection rates using the combined method.<sup>[17,18]</sup>

All of the above-mentioned studies were performed in high-resource settings. Yuan *et al.*, in China, performed the only study in a low-resource setting in which the feasibility of only methylene blue injections during laparotomy was explored.<sup>[19]</sup> Using methylene blue, SLNs were successfully detected in 64 (83.1%, 64/77) patients. In our study, blue dye was seen in the SLN in 69.4% of cases. This was comparable to the number of cases detected by gamma probe intraoperatively. In accordance with the aforementioned studies, we found that a combined method using <sup>99m</sup>Tc-nanocolloid lymphoscintigraphy, an intraoperative gamma probe and blue dye yields the best results detecting 91.7% of SLNs.

In most malignancies, the usual method of preoperative assessment of lymph node involvement is done with imaging. <sup>18</sup>F-FDG PET and PET/CT compared to anatomical imaging have been tested in preoperative staging of gynecological cancers. In cervical cancer, these imaging modalities were used in multiple studies to identify patients with nodal metastases. Signorelli *et al.* evaluated 159 patients with early-stage cervical cancer and reported nodal metastases in 18% of their study population. They reported a sensitivity of 32.1%, specificity of 96.9%, PPV of 69.2%, and NPV of 86.9%. They attributed the low sensitivity to the presence of nodal micrometastases.<sup>[20]</sup> In contradiction to this, Chou *et al.* reported a sensitivity of 10%, specificity of 94%, PPV of 25%, and NPV of 84%. They included 60 patients with early-stage cervical cancer and found that <sup>18</sup>F-FDG PET/CT is of little value in the primary staging of nonbulky, early-stage cervical cancer.<sup>[21]</sup>

We also aimed to evaluate the utility of <sup>18</sup>F-FDG PET/CT in the initial staging of early cervical cancer to predict lymph node involvement. Our results showed a low sensitivity of <sup>18</sup>F-FDG PET/CT in identifying patients with nodal involvement in early-stage cervical cancer (40.0%). This is consistent with published literature reporting a sensitivity of 10%–53%.<sup>[20–22]</sup> The discrepancy could be due to the number of patients and the stage of disease included in the different series. In our study, the low sensitivity was most likely due to the presence of nodal micrometastases which are typically found in early-stage cervical cancer combined with the limited spatial resolution of <sup>18</sup>F-FDG PET/CT.

In our series, the absence of metastatic pelvic lymph nodes was correctly diagnosed in 18/28 patients. Nodal metastases were correctly diagnosed in 2/28 patients. In addition to

three false negative <sup>18</sup>F-FDG PET/CT scans of the pelvic lymph nodes, there were five false positive scans. The patient based specificity of <sup>18</sup>F-FDG PET/CT for the identification of pelvic lymph node involvement was 78.3% and the NPV was 85.7%. Although <sup>18</sup>F-FDG PET/CT demonstrated a relatively high specificity, it lacked the sensitivity and predictive value needed to replace pelvic lymphadenectomy.

The limitations of our study were the limited number of patients and the fact that not all of the included patients underwent pre-operative <sup>18</sup>F-FDG PET/CT. With regard to the lymphoscintigraphy, the patients were injected with <sup>99m</sup>Tc-nanocolloid the day before the surgery which could have affected the rate of intraoperative gamma probe detection of the SLN due to the low dose injected and the short half-life of <sup>99m</sup>Tc ( $t_{1/2} = 6$  h) with subsequent radioactive decay. The gynecologists handled the gamma probe intraoperatively and, due to limited experience, could have missed SLNs initially. This however improved toward the end of the study.

## CONCLUSION

The combination of radiolabeled nanocolloid with blue dye is safe and reliable and allows successful detection of SLNs in patients with early-stage cervical cancer in a population with high prevalence of HIV. This may potentially reduce futile pelvic lymphadenectomy with its associated complications. The sensitivity of PET/CT in the lymph node staging of early-stage cervical cancer is low as expected and can therefore not replace SLN biopsy. The specificity and NPV are however high and can be used in conjunction with SLN biopsy.

## Acknowledgments

The authors acknowledge the contributions of members of staff at the department of Nuclear Medicine at Steve Biko academic Hospital, University of Pretoria, South Africa.

## Financial support and sponsorship

Nil.

## Conflicts of interest

There are no conflicts of interest.

## REFERENCES

1. Ferlay J, Soerjomataram I, Ervik M, Dikshit R, Eser M, Mathers C, *et al.* GLOBOCAN 2012 cancer incidence and mortality worldwide: IARC CancerBase No. 11. Lyon: International Agency for Research on Cancer; 2013.
2. Statistics South Africa. Mid-Year Population Estimates, 2018. Stats SA; 23 July, 2018. Available from: <http://www.statssa.gov.za/publications/P0302/P03022018.pdf>. [Last accessed on 2018 Dec 10].
3. Hawes SE, Critchlow CW, Faye NiangMA, Diouf MB, Diop A, Touré P,

- et al.* Increased risk of high-grade cervical squamous intraepithelial lesions and invasive cervical cancer among african women with human immunodeficiency virus type 1 and 2 infections. *J Infect Dis* 2003;188:555-63.
4. Delmas MC, Larsen C, van Benthem B, Hamers FF, Bergeron C, Poveda JD, *et al.* Cervical squamous intraepithelial lesions in HIV-infected women: Prevalence, incidence and regression. European study group on natural history of HIV infection in women. *AIDS* 2000;14:1775-84.
  5. La Ruche G, You B, Mensah-Ado I, Bergeron C, Montcho C, Ramon R, *et al.* Human papillomavirus and human immunodeficiency virus infections: Relation with cervical dysplasia-neoplasia in african women. *Int J Cancer* 1998;76:480-6.
  6. Pecorelli S, Zigliani L, Odicino F. Revised FIGO staging for carcinoma of the cervix. *Int J Gynaecol Obstet* 2009;105:107-8.
  7. Sevin BU, Lu Y, Bloch DA, Nadji M, Koechli OR, Averette HE. Surgically defined prognostic parameters in patients with early cervical carcinoma. A multivariate survival tree analysis. *Cancer* 1996;78:1438-46.
  8. Matsuura Y, Kawagoe T, Toki N, Tanaka M, Kashimura M. Long-standing complications after treatment for cancer of the uterine cervix – Clinical significance of medical examination at 5 years after treatment. *Int J Gynecol Cancer* 2006;16:294-7.
  9. Achouri A, Huchon C, Bats AS, Bensaïd C, Nos C, Lécure F. Complications of lymphadenectomy for gynecologic cancer. *Eur J Surg Oncol* 2013;39:81-6.
  10. Look KY, Brunetto VL, Clarke-Pearson DL, Averette HE, Major FJ, Alvarez RD, *et al.* An analysis of cell type in patients with surgically staged stage IB carcinoma of the cervix: A Gynecologic oncology group study. *Gynecol Oncol* 1996;63:304-11.
  11. Cabanas RM. An approach for the treatment of penile carcinoma. *Cancer* 1977;39:456-66.
  12. Morton DL, Wen DR, Wong JH, Economou JS, Cagle LA, Storm FK, *et al.* Technical details of intraoperative lymphatic mapping for early stage melanoma. *Arch Surg* 1992;127:392-9.
  13. Giuliano AE, Kirgan DM, Guenther JM, Morton DL. Lymphatic mapping and sentinel lymphadenectomy for breast cancer. *Ann Surg* 1994;220:391-8.
  14. Reinhardt MJ, Ehrhrit-Braun C, Vogelgesang D, Ihling C, Högerle S, Mix M, *et al.* Metastatic lymph nodes in patients with cervical cancer: Detection with MR imaging and FDG PET. *Radiology* 2001;218:776-82.
  15. Matsukuma K, Tsukamoto N, Matsuyama T, Ono M, Nakano H. Preoperative CT study of lymph nodes in cervical cancer – Its correlation with histological findings. *Gynecol Oncol* 1989;33:168-71.
  16. Altgassen C, Hertel H, Brandstädt A, Köhler C, Dürst M, Schneider A. Multicenter validation study of the sentinel lymph node concept in cervical cancer: AGO study group. *J Clin Oncol* 2008;26:2943-51.
  17. Cormier B, Diaz JP, Shih K, Sampson RM, Sonoda Y, Park KJ, *et al.* Establishing a sentinel lymph node mapping algorithm for the treatment of early cervical cancer. *Gynecol Oncol* 2011;122:275-80.
  18. Lécure F, Mathevet P, Querleu D, Leblanc E, Morice P, Daraï E, *et al.* Bilateral negative sentinel nodes accurately predict absence of lymph node metastasis in early cervical cancer: Results of the SENTICOL study. *J Clin Oncol* 2011;29:1686-91.
  19. Yuan SH, Xiong Y, Wei M, Yan XJ, Zhang HZ, Zeng YX, *et al.* Sentinel lymph node detection using methylene blue in patients with early stage cervical cancer. *Gynecol Oncol* 2007;106:147-52.
  20. Signorelli M, Guerra L, Montanelli L, Crivellaro C, Buda A, Dell'Anna T, *et al.* Preoperative staging of cervical cancer: Is 18-FDG-PET/CT really effective in patients with early stage disease? *Gynecol Oncol* 2011;123:236-40.
  21. Chou HH, Chang TC, Yen TC, Ng KK, Hsueh S, Ma SY, *et al.* Low value of [18F]-fluoro-2-deoxy-D-glucose positron emission tomography in primary staging of early-stage cervical cancer before radical hysterectomy. *J Clin Oncol* 2006;24:123-8.
  22. Wright JD, Dehdashti F, Herzog TJ, Mutch DG, Huettner PC, Rader JS, *et al.* Preoperative lymph node staging of early-stage cervical carcinoma by [18F]-fluoro-2-deoxy-D-glucose-positron emission tomography. *Cancer* 2005;104:2484-91.