

Case Report

Precise localization of biliary leak post laparoscopic cholecystectomy with hepatobiliary scintigraphy and adjunct single-photon emission tomography/computed tomography fusion imaging

ABSTRACT

Laparoscopic cholecystectomy is commonly performed as the treatment of choice for symptomatic gallstone diseases. Bile leak is a potential complication of this procedure and the cystic duct stump is the most common site of leakage. Early diagnosis and treatment of bile leak is crucial in decreasing the morbidity and mortality related to this complication. We present a case of biliary leak following laparoscopic cholecystectomy, diagnosis of active biliary leak, and accurate localization of the site of biliary leak on hepatobiliary scintigraphy and adjunct single-photon emission computed tomography/computed tomography fusion imaging.

Keywords: ^{99m}Tc -mebrofenin hepatobiliary scintigraphy, biliary leak, endoscopic retrograde cholangiopancreatography, single-photon emission computed tomography/computed tomography fusion imaging

INTRODUCTION

Postsurgical bile leaks can be associated with significant morbidity and even mortality, if not identified and treated at an early phase. Hepatobiliary scintigraphy (HBS) scan is an important test for the detection of bile leaks in the postoperative abdomen. However, the lack of anatomical details on planar images can make interpretation difficult, especially in the setting of altered postsurgical anatomy. Familiarity with the expected postoperative appearance on HBS scan and correlation with single-photon emission computed tomography/computed tomography (SPECT/CT) or other imaging modalities when available are very important.

A 37-year-old female underwent laparoscopic cholecystectomy for cholelithiasis with cholecystitis and had uneventful recovery. The drainage tube kept postoperatively was removed next day before the discharge.

The patient was readmitted on the 3rd day with complaining of abdominal pain; her white blood cell was 19, C-reactive

protein 39.2, serum glutamic-oxaloacetic transaminase 63, serum glutamic-pyruvic transaminase 90, and direct bilirubin 10.2.


CT scan of the abdomen with contrast was performed and showed free fluid within the peritoneal cavity, more prominent in the dependent portion of the abdomen (pelvic cavity). The operated cholecystectomy site appeared normal with surgical clip *in situ*. No intra- or extrahepatic biliary dilatation was seen. The above findings were similar to those seen in the previous magnetic resonance imaging examination.

SHEKHAR VINOD SHIKARE, AHMED EL HAKEEM¹

Departments of Nuclear Medicine and ¹Surgery, Al Zahra Hospital, Sharjah, United Arab Emirates

Address for correspondence: Dr. Shekhar Vinod Shikare, Al Zahra Hospital, P.O. Box 3499, Sharjah, UAE.
E-mail: shikare@gmail.com

Submission: 07-Nov-19, **Accepted:** 12-Dec-19, **Published:** 22-Jul-20

Access this article online	
Website: www.wjnm.org	Quick Response Code 
DOI: 10.4103/wjnm.WJNM_80_19	

This is an open access journal, and articles are distributed under the terms of the Creative Commons Attribution-NonCommercial-ShareAlike 4.0 License, which allows others to remix, tweak, and build upon the work non-commercially, as long as appropriate credit is given and the new creations are licensed under the identical terms.

For reprints contact: WKHLRPMedknow_reprints@wolterskluwer.com

How to cite this article: Shikare SV, El Hakeem A. Precise localization of biliary leak post laparoscopic cholecystectomy with hepatobiliary scintigraphy and adjunct single-photon emission tomography/computed tomography fusion imaging. World J Nucl Med 2020;19:284-7.




Figure 1: Hepatobiliary scintigraphy dynamic images showing active biliary leak (arrows)

Ultrasound of the abdomen

Mild free fluid was seen, right adnexal, paracolic, and hepatic regions.

^{99m}Tc-mebrofenin hepatobiliary scan

After intravenous administration of ^{99m}Tc-mebrofenin, sequential a) dynamic abdominal images were obtained over 60 min b) static images were obtained at 60 min & 120 min and SPECT-CT FUSED images at 60 minutes. It shows good hepatocytic function by the liver and non-obstructive biliary to bowel tracer transit.

Abnormal tracer leak started seeing approximately from the confluence of cystic and common hepatic duct region [Figures 1 and 2] arrows, moving to the gall bladder fossa and then moving downwards from the inferior border of the liver [Figure 2] arrow and accumulating in peri-hepatic, infra diaphragmatic, right para-colic, left para colic region and eventually throughout the abdomen [Figure 2].

Adjunct SPECT/CT was performed at sixty minutes selectively for precise anatomical localization and it showed active site of the biliary leak approximately at the confluence of cystic and common hepatic duct region [Figures 3 and 4] arrows.

Diagnostic laparoscopy was performed post HBS and 2 mm biliary leak point was identified approximately at confluence of cystic duct and common hepatic duct region, which is most probably due to burn injury.

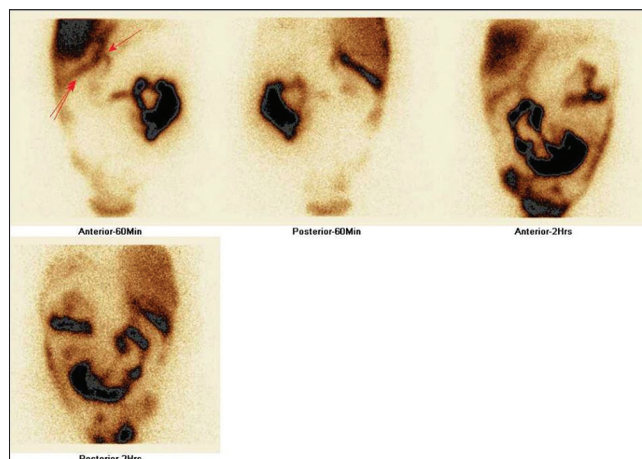


Figure 2: Hepatobiliary scintigraphy static 60 min and 2 h images showing site of the leak (single arrow) and then through the inferior border of the liver (two arrows)

Endoscopic retrograde cholangiopancreatography was performed with stenting of the common bile duct and the patient settled and the stent was removed after 6 weeks.

DISCUSSION

Bile leaks can occur after laparoscopic cholecystectomy and the incidence of injuries to the common bile duct was 0.1%–0.6%.^[1-3]

Imaging modalities used to detect bile leaks are CT, endoscopic retrograde cholangiopancreatography, MR

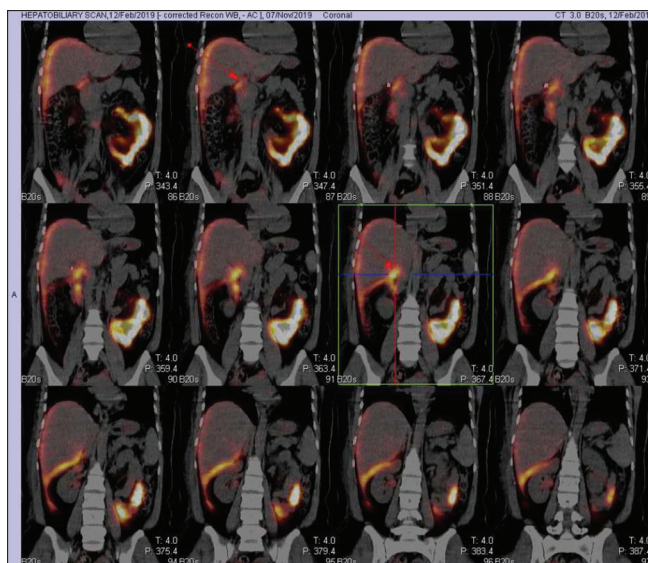


Figure 3: Hepatobiliary scintigraphy single-photon emission computed tomography/computed tomography fusion images showing site of the biliary leak (arrows)

cholangiopancreatography (MRCP), ultrasound, and HBS. Among these, only HBS and MRCP, noninvasive studies, can identify abnormal fluid collection as bile. However, there are limitations to emergency MRCP, including lack of readily available MR imaging equipment, technologists, personnel experienced with interpreting MRCP, and higher cost.^[4] Therefore, HBS is the commonly used modality to diagnose biliary injury.^[5]

HBS is a highly sensitive imaging modality and useful for early diagnosis of bile leaks. HBS can determine whether a fluid collection seen on ultrasound or CT is of biliary origin.^[5,6] HBS can determine the rate of leakage and can be used as a follow-up tool.^[5,6] A common finding of a bile leak is the radiopharmaceutical's progressive accumulation outside the biliary system, either localized (bilomas) or diffuse.

An accurate localization of a bile leak is possible by HBS along with adjunct use of SPECT/CT imaging to get anatomical information. This localization is important because of the shift in management strategy from very invasive to minimally invasive.^[7]

This case demonstrates a direct bile leakage sign; this direct sign leads to recognition of an exact bile-leaking site at the confluence of cystic and common hepatic duct region.

Determination of type of injury based on Nagano classification is useful in deciding the optimal management and the likelihood of success with conservative measures. While most intrahepatic bile duct leaks (Nagano Type A) are self-limiting and respond to external drainage, some major leaks (Nagano

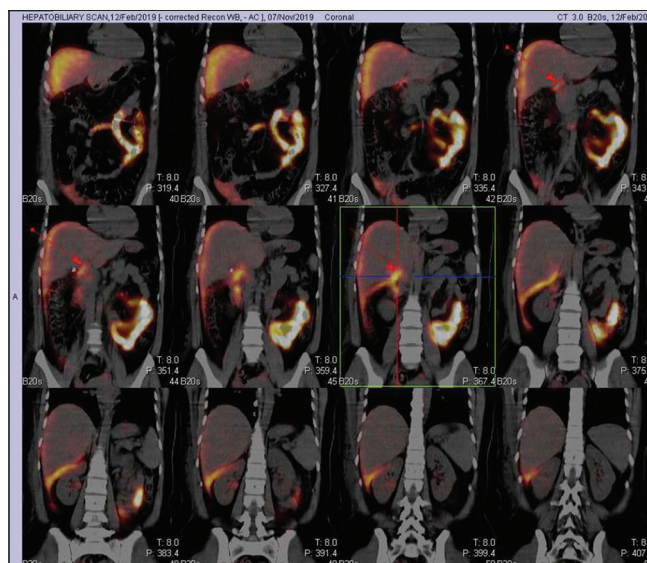


Figure 4: Hepatobiliary scintigraphy single-photon emission computed tomography/computed tomography fusion images showing site of the biliary leak (arrows)

Types B and C) often require ERCP and stent placement in the common bile duct and a select few patients with Nagano Type D injury require surgical management in the form of bilioenteric anastomoses or liver resection.^[8]

Accurate localization of the site of bile leak through a direct sign can be obtained with HBS and HBS SPECT/CT as shown in this case. The HBS SPECT/CT provides both anatomic and functional information and overcomes the lack of specificity of CT alone or detailed anatomic information of HBS alone.^[8]

Declaration of patient consent

The authors certify that they have obtained all appropriate patient consent forms. In the form the patient(s) has/have given his/her/their consent for his/her/their images and other clinical information to be reported in the journal. The patients understand that their names and initials will not be published and due efforts will be made to conceal their identity, but anonymity cannot be guaranteed.

CONCLUSION

The precise site of a bile leak is possible with HBS noninvasive techniques as demonstrated in this case. Knowledge of the bile leak site will increase opportunities to detect the direct sign of a bile leak in advanced HBS with SPECT/CT. This has given the change in approach regarding management of a bile leak from less invasive to more invasive.

Financial support and sponsorship

Nil.

Conflicts of interest

There are no conflicts of interest.

REFERENCES

1. Frilling A, Li J, Weber F, Frühauf NR, Engel J, Beckebaum S, *et al.* Major bile duct injuries after laparoscopic cholecystectomy: A tertiary center experience. *J Gastrointest Surg* 2004;8:679-85.
2. Singh K, Ohri A. Anatomic landmarks: Their usefulness in safe laparoscopic cholecystectomy. *Surg Endosc* 2006;20:1754-8.
3. Nuzzo G, Giuliante F, Giovannini I, Ardito F, D'Acapito F, Vellone M, *et al.* Bile duct injury during laparoscopic cholecystectomy: Results of an Italian national survey on 56 591 cholecystectomies. *Arch Surg* 2005;140:986-92.
4. Mujoomdar M, Russell E, Dionne F. CADTH Optimizing HealthSystem Use of Medical Isotopes and Other Imaging Modalities. Ottawa, Ontario: Canadian Agency for Drugs and Technologies in Health; 2012.
5. LeBedis CA, Anderson SW, Mercier G, Kussman S, Coleman SL, Golden L, *et al.* The utility of CT for predicting bile leaks in hepatic trauma. *Emerg Radiol* 2015;22:101-7.
6. Ziessman HA, O'Malley JP, Thrall JH. *Nuclear Medicine: The Requisites*. 4th ed. Philadelphia, PA: Saunders; 2014.
7. Sharma P, Kumar R, Das KJ, Singh H, Pal S, Parshad R, *et al.* Detection and Localization of Post-Operative and Post-Traumatic Bile Leak: Hybrid SPECT/CT with ^{99m}Tc-Mebrofenin. New York, NY: Springer Science Business Media, LLC; 2012.
8. Kapoor S, Nundy S. Bile duct leaks from the intrahepatic biliary tree: A review of its etiology, incidence, and management. *HPB Surg* 2012;2012:752932.