

Case Report

Diagnosis of portal vein tumor thrombosis in colorectal carcinoma in fluorodeoxyglucose positron emission tomography–computed tomography scan and its clinical implication

ABSTRACT

Hypercoagulable state is seldom associated with colorectal carcinoma either in the form of bland thrombosis or tumor thrombosis (TT). Venous TT should not be overlooked while deciding treatment of colorectal cancer due to its propensity to complicate the disease in terms of morbidity and mortality even in favorable prognostic case of colorectal cancer. Fluorodeoxyglucose positron emission tomography–contrast-enhanced computed tomography (FDG PET-CECT) scan has proven its role in staging of colorectal cancer and also to diagnose tumor venous thrombosis. Here, we are presenting a case of a 61-year-old male patient having adenocarcinoma of rectosigmoid colon, and on pretherapy FDG PET-CECT scan, he was found with portal vein TT and its related complication which is helpful for staging, treatment planning, and prognostication.

Keywords: Colorectal carcinoma, fluorodeoxyglucose positron emission tomography–contrast-enhanced computed tomography, portal venous tumor thrombosis

INTRODUCTION

Portal vein tumor thrombosis (PVTT) in case of colon carcinoma is a very rare entity, seen in 1%–2% cases.^[1] It changes the staging, prognosis, and treatment, and it is associated with poor prognosis, lower 24 months' survival rate, and cause of treatment failure due to venous tumor thrombosis (VTT) remains undiagnosed or unaddressed during surgical removal of primary.^[2] PVTT is commonly seen in hepatocellular carcinoma. Microscopic invasion of colorectal carcinoma in intrahepatic portal vein is experienced; but, the incidence of macroscopic evidence at portal trunk is rare, estimated as 2.8%.^[3] We report an infrequent case of colon carcinoma with PVTT.

CASE REPORT

A 61-year-old male patient, biopsy-proven case of moderately differentiated colorectal adenocarcinoma, referred for ¹⁸F fluorodeoxyglucose positron emission tomography–computed tomography (¹⁸F-FDG PET-CT) scan for staging. PET-CT scan

was done on SIEMENS Biograph TruePoint 16-slice CT scanner after 60 min of 370 MBq ¹⁸F-FDG intravenous injection.

The scan revealed high-grade FDG-avid enhancing asymmetric circumferential wall thickening of 14 mm involving distal sigmoid colon, rectosigmoid junction, and proximal rectum with length of involved segment –80 mm and FDG avid multiple locoregional sigmoid mesenteric and mesorectal lymph nodes [Figure 1]. The scan also revealed high-grade FDG-avid (maximum standardized uptake

DIGISH SHAH

Nuclear Medicine and PET CT Department, HCG Cancer Hospital, Ahmedabad, Gujarat, India


Address for correspondence: Dr. Digish Shah, Nuclear Medicine and PET CT Department, HCG Cancer Hospital, Sola – Science City Road, Ahmedabad - 380 060, Gujarat, India. E-mail: digish86PET@gmail.com

Submission: 20-Nov-19, **Accepted:** 02-Jan-20, **Published:** 22-Jul-20

This is an open access journal, and articles are distributed under the terms of the Creative Commons Attribution-NonCommercial-ShareAlike 4.0 License, which allows others to remix, tweak, and build upon the work non-commercially, as long as appropriate credit is given and the new creations are licensed under the identical terms.

For reprints contact: WKHLRPMedknow_reprints@wolterskluwer.com

How to cite this article: Shah D. Diagnosis of portal vein tumor thrombosis in colorectal carcinoma in fluorodeoxyglucose positron emission tomography–computed tomography scan and its clinical implication. World J Nucl Med 2020;19:296-300.

Access this article online	
Website: www.wjnm.org	Quick Response Code 
DOI: 10.4103/wjnm.WJNM_84_19	

value [SUVmax] 12.9) mild enhancing portal vein thrombus extending into the right main branch and left main and segmental branches with ill-margined wedge-shaped hypodense areas in segment IV representing parenchymal involvement [Figures 2 and 3].

The patient has received 4 cycles of chemotherapy and referred for FDG PET-CT scan for response evaluation [Figure 4], and follow-up scan revealed significant reduction in metabolic activity and malignant wall thickening of distal colon and good response in locoregional nodes [Figure 5]. Follow-up scan also revealed complete resolution of hepatic parenchymal lesion and complete metabolic resolution (CMR) of PVTT [Figure 6]. However, thrombosis was further extended into entire length of superior mesenteric

vein (SMV) and part of splenic vein with development of multiple collaterals in periportal and peripancreatic head region which suggested portal vein cavernoma

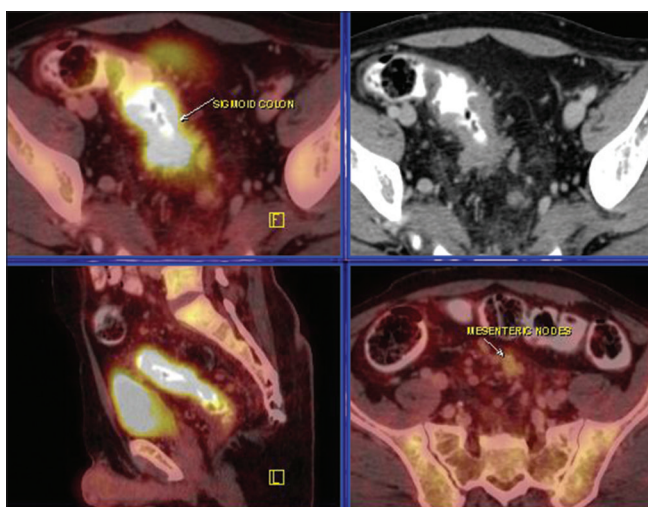


Figure 1: Fluorodeoxyglucose positron emission tomography-contrast-enhanced computed tomography images show fluorodeoxyglucose-avid primary rectosigmoid malignant wall thickening with few inferior mesenteric metastatic lymph nodes

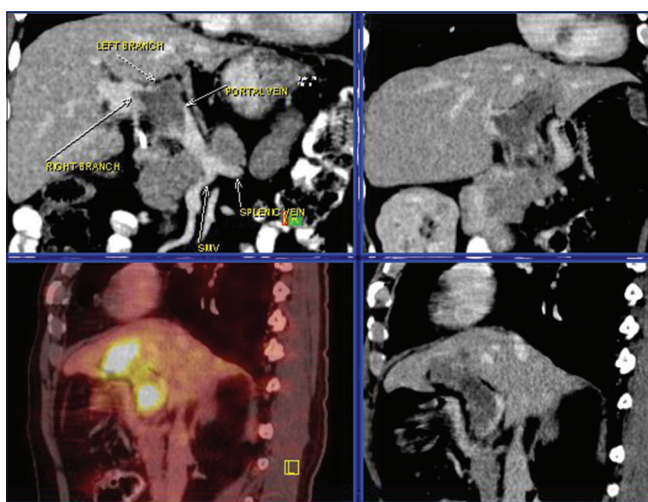


Figure 3: Fluorodeoxyglucose-avid thrombosis in portal vein and proximal right-left branches. Superior mesenteric vein and splenic veins are normal

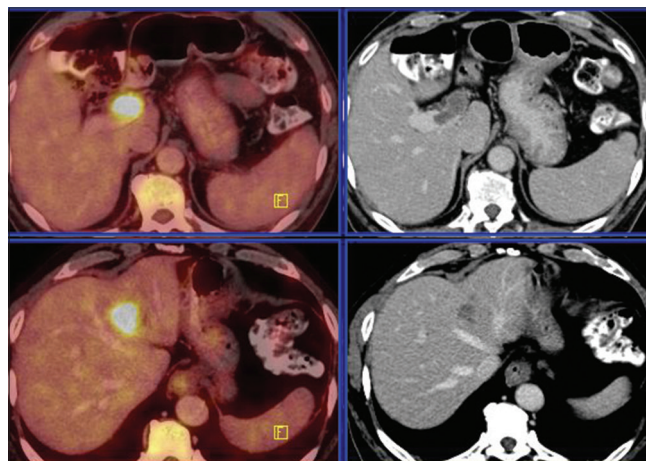


Figure 2: Fluorodeoxyglucose positron emission tomography-contrast-enhanced computed tomography images show fluorodeoxyglucose-avid tumor thrombosis in main portal vein trunk and proximal right (upper row) and left main branch with parenchymal involvement (lower row)

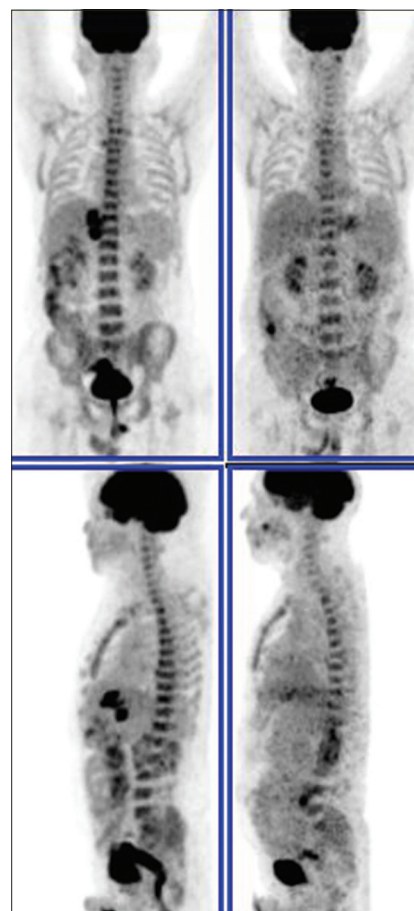


Figure 4: Maximum intensity projection images of fluorodeoxyglucose positron emission tomography scans – baseline (left column) and post therapy (right column) show treatment response in primary and tumor thrombotic lesions

formation [Figure 7]. There was also development of mild ascites [Figure 8], congested small bowel mesentery, and stranding in greater omentum which is suggestive of mesenteric ischemia [Figure 9].

DISCUSSION

Portal vein thrombosis can be of two types: (a) benign – venous thromboembolism (VTE) and (b) tumor thrombosis (TT). It is

critical not only to diagnose PVT but also to differentiate both causes due to their different treatment strategies. Thrombosis, either VTE or TT, is more common in cancer patients with few causative explanations: (i) direct infiltration of tumor in contiguous vein and causes blood flow stasis which leads to thrombosis, (ii) secretion of thrombogenic factors from tumor, and (iii) vascular spread of tumor thromboemboli and reabsorb in remote area.

VTE may be an occult cancer marker, and few cases were reported as splanchnic venous thrombosis as the first sign of liver or pancreatic malignancies.^[4-6]

VTT is occasionally seen but more commonly associated with renal cell carcinoma, hepatocellular carcinoma, gastric, adrenocortical, pancreatic, and testicular carcinoma.

VTT in colorectal cancer is infrequent entity and seen in 1%–2% cases. It is mostly associated with advanced local disease and microscopic invasion in perilesional vein. Cecum to sigmoid colon cancers may have portal vein invasion whereas rectal cancer may have inferior mesenteric (portal system) or

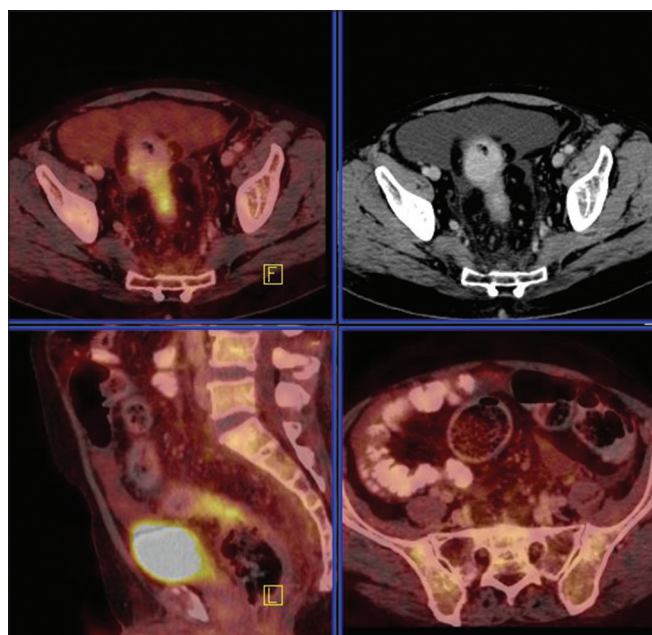


Figure 5: Fluorodeoxyglucose positron emission tomography-computed tomography scan images show reduction in fluorodeoxyglucose avidity and size of primary malignant wall thickening of rectosigmoid colon and mesenteric nodes

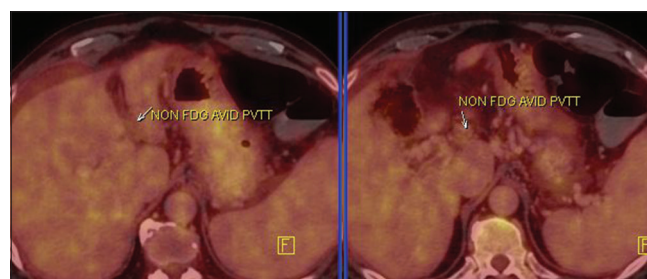


Figure 6: Fluorodeoxyglucose positron emission tomography-computed tomography images show complete metabolic resolution of portal vein tumor thrombosis

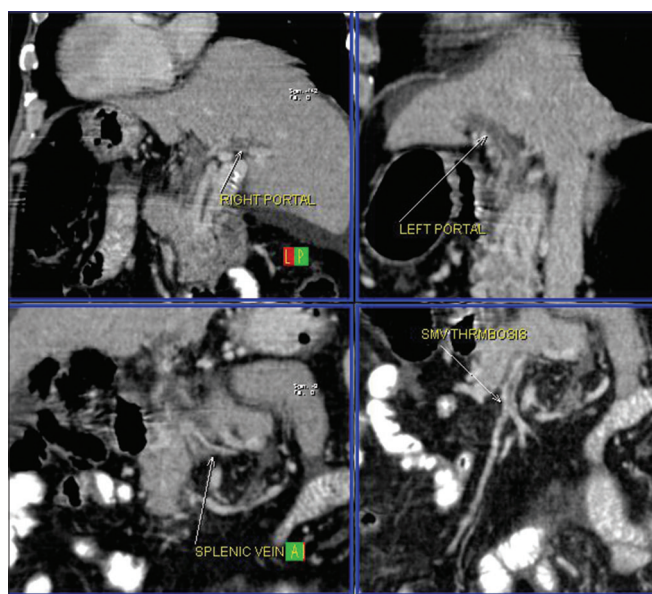


Figure 7: Contrast-enhanced computed tomography images show extension of thrombosis in superior mesenteric and splenic veins

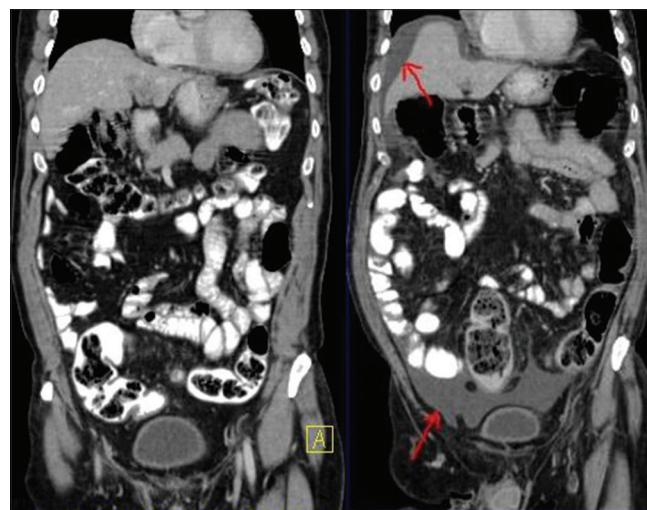


Figure 8: Comparative computed tomography scan images (base line on the left side and post therapy on the right side) show new development of ascites as a complication of portal vein thrombosis

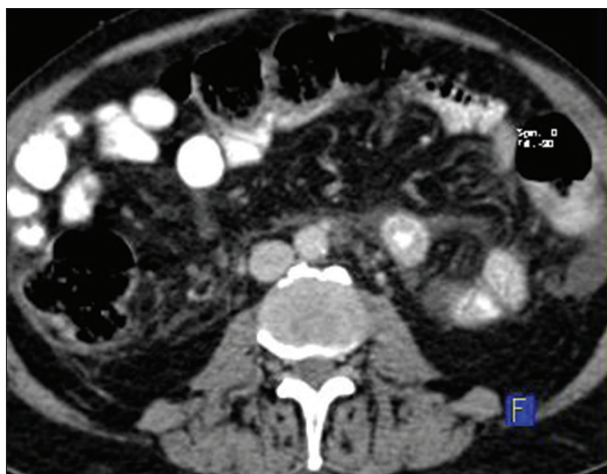

Figure 9: Computed tomography scan images of fluorodeoxyglucose positron emission tomography–contrast-enhanced computed tomography show congestion in small bowel mesentery and greater omentum suggestive of features of mesenteric ischemia as complication of portal vein tumor thrombosis

internal iliac vein (systemic venous system) invasion due to dual venous drainage.^[7]

PVTT in colon cancer is not only always associated with liver parenchymal lesion but also with higher rate of synchronous or metachronous liver metastasis. Most reported cases of PVTT had concomitant liver lesions and is continuous with liver lesions.^[8] Better prognosis can be expected with proper diagnosis of macroscopic TT in main branch and/or trunk of portal vein by proper complete resection and adequate chemotherapy.

Otani *et al.* published review article and analyzed high incidence of PVTT in colorectal cancer in moderately differentiated adenocarcinoma and higher rate synchronous or metachronous liver metastatic rate as seen in this case.^[11]

Pelin *et al.* studied role of FDG PET CT in accurate diagnosis of tumor thrombosis and differentiating benign versus tumor thrombosis and concluded linear/ focal FDG uptake with high SUVmax were consistent with TT.^[9]

On PET-CECT, it is usually seen as linear or focal FDG-avid TT with thread and streak pattern with intraluminal CT contrast filling defect. Difference in intensity of FDG uptake may be due to variable tumor cellular density of thrombosis.^[10] Few pitfalls of FDG PET-CECT scan in thrombosis evaluation are as follows: (a) size of thrombosis – smaller than resolution of PET scanner may miss the lesion; (b) FDG avidity of primary tumor correlates with of TT, for example, non-FDG avid thrombosis in mucinous adenocarcinoma; and (c) false-positive uptake in inflammatory thrombi like septic thrombus which can be correlated with other clinical and biochemical parameters.

Presentation of PVT ranges from asymptomatic to entirely new set of symptoms, including pain, ascites, hematemesis, varices, or melena. PVT-induced complications include extension of thrombus in splenic or SMVs which may lead to mesenteric ischemia, intestinal ischemia and infarction, ascites and conditions associated with chronic PVT-esophageal-gastric varices, and portal hypertension. As seen in this case, PVT causes collateralization called as portal cavernoma and development of portosystemic shunting. If cavernous collaterals may not sufficiently drain the portal blood flow, there may be increase in the risk of complications.

Durable PVT causes stagnant of blood flow in its territories such as mesenteric and splenic veins, which leads to mesenteric thrombosis and may cause lethal complication of bowel ischemia. In the present case, follow-up PET scan revealed extension of bland thrombosis in SMV and splenic vein with few signs of mesenteric ischemia such as mesenteric thickening, congestion, fat stranding, and ascites. Most important predictors of occurrence of subsequent bowel ischemia are location of VT (relative to whole mesenteric circulation), its extension, and presence of adequate collateral circulation.

CONCLUSION

Accurate diagnosis of venous TT is essential for prognostication, to predict recurrence and metastatic rate, for treatment planning, especially planning of surgery and adjuvant chemotherapy, and to avoid unnecessary anticoagulation therapy for benign VTE. In such scenario, FDG PET-CECT plays an important role.

Declaration of patient consent

The authors certify that they have obtained all appropriate patient consent forms. In the form, the patient has given his consent for his images and other clinical information to be reported in the journal. The patient understands that name and initials will not be published and due efforts will be made to conceal identity, but anonymity cannot be guaranteed.

Financial support and sponsorship

Nil.

Conflicts of interest

There are no conflicts of interest.

REFERENCES

1. Otani K, Ishihara S, Hata K, Muroto K, Sasaki K, Yasuda K, *et al.* Colorectal cancer with venous tumor thrombosis. *Asian J Surg* 2018;41:197-202.

2. Shintani D, Tajima Y, Baba H, Matsuzawa T, Kumamoto K, Kumagai Y, *et al.* Colon cancer with portal vein tumor thrombosis-a case report and review of the literature. *Gan To Kagaku Ryoho* 2012;39:2243-5.
3. Tada K, Kokudo N, Seki M, Ueno M, Azekura K, Ohta H, *et al.* Hepatic resection for colorectal metastasis with macroscopic tumor thrombus in the portal vein. *World J Surg* 2003;27:299-303.
4. Saito M, Seo Y, Yano Y, Uehara K, Hara S, Momose K, *et al.* Portal venous tumor growth-type of hepatocellular carcinoma without liver parenchyma tumor nodules: A case report. *Ann Hepatol* 2013;12:969-73.
5. Poddar N, Avezbakiyev B, He Z, Jiang M, Gohari A, Wang JC. Hepatocellular carcinoma presenting as an incidental isolated malignant portal vein thrombosis. *J Gastrointest Cancer* 2012;43:486-9.
6. Reilly C, Zenoni S, Hasan MK, Varadarajulu S, Tran TA, de la Fuente SG, *et al.* Primary pancreatic Ewing's sarcoma with portal vein tumor thrombosis. *J Gastrointest Surg* 2013;17:1015-9.
7. Gupta P, Kramer EL, Ponzio F. FDG uptake in tumor thrombus in inferior vena cava from rectal cancer on positron emission tomography. *Clin Nucl Med* 2005;30:342-3.
8. Matsumoto J, Kojima T, Hiraguchi E, Abe M. Portal vein tumor thrombus from colorectal cancer with no definite metastatic nodules in liver parenchyma. *J Hepatobiliary Pancreat Surg* 2009;16:688-91.
9. Pelin OK, Emel YS, Zehra PK, Eda BY, Elvan CC. Role of FDG PET-CT in distinction of benign thrombus and tumor thrombus in Oncological Patients. *Biomed J Sci Tech Res.* 2018;2:2758-62.
10. Ravina M, Hess S, Chauhan MS, Jacob MJ, Alavi A. Tumor thrombus: Ancillary findings on FDG PET/CT in an oncologic population. *Clin Nucl Med* 2014;39:767-71.