

## Original Article

# Detection efficiency of $^{18}\text{F}$ -flourodeoxyglucose positron emission tomography/computed tomography for primary tumors in patients with carcinoma of unknown primary

## ABSTRACT

Carcinoma of unknown primary (CUP) is defined as biopsy proven tumor metastases that remains unidentified after a thorough diagnostic evaluation. The purpose of this study was to find the detection efficiency of  $^{18}\text{F}$ -flourodeoxyglucose positron emission tomography/computed tomography ( $^{18}\text{F}$ FDG PET/CT) in patients with CUP. This prospective study was conducted at PET/CT Section of Department of Radiology, Aga Khan University Hospital Karachi, Pakistan from August 2017 to January 2018. Patients with a history of CUP referred for  $^{18}\text{F}$ FDG PET/CT scan for detection of primary sites during the study were recruited.  $^{18}\text{F}$ FDG PET/CT scan was acquired using standardized protocol, and patients with suspected primary sites underwent biopsies. Scan findings and biopsy results were analyzed to find the detection rate, sensitivity, area under curve (AUC), and positive predictive value (PPV). As no biopsy was performed in negative scan, true negative, and specificity could not be calculated. During the study, 46 consecutive patients with CUP were included. Mean age of cohort was  $58 \pm 17$  years (63% male and 37% female) having a mean body mass index of  $24.70 \pm 4.97$  kg/m<sup>2</sup>. Thirty-four patients (34/46) found to have a hypermetabolic focus suggestive of the primary tumor with known metastatic sites and subjected to biopsy which turned out to be positive in 26/34 patients (true positive). The primary tumor was detected in gastrointestinal and hepatobiliary in 8 (17%), head and neck in 6 (13%), genitourinary 4 (09%), lung 3 (06%), and miscellaneous sites in 5 (11%) patients. Detection rate, sensitivity and PPV of  $^{18}\text{F}$ FDG PET/CT were 57%, 68%, and 76%, respectively. Remaining 12/46 patients with negative  $^{18}\text{F}$ FDG PET/CT for primary focus did not have biopsy. Receiver operating character curve revealed fair diagnostic strength of  $^{18}\text{F}$ FDG PET/CT for detecting unknown primary (AUC 0.667;  $P = 0.054$ ; standard error = 0.083; confidence interval: 0.504–0.830). We conclude that  $^{18}\text{F}$ FDG PET/CT is an effective tool for detecting primary tumor in patients with CUP and its upfront use could preclude the use of many futile diagnostic procedures. Furthermore, higher resolution scanners and acquiring delayed images in patients with negative study could reduce false-negative results in patients with CUP.

**Keywords:** 18-Flourodeoxyglucose positron emission tomography/computed tomography, carcinoma of unknown primary, detection efficiency

## INTRODUCTION

Carcinoma of unknown primary (CUP) is a histologically proven metastatic tumor having an unidentified primary tumor site despite standardized diagnostic workup.<sup>[1]</sup> CUP is the 7<sup>th</sup>–8<sup>th</sup> commonest cancer in world and accounts for 2% of all malignant tumors diagnosed in the United States in 2011.<sup>[2]</sup> CUP follows an aggressive course with about 50% of patients survive more than a year<sup>[3]</sup> although longer in patients in whom primary tumor is detected.<sup>[4]</sup> Diagnostic paradigm should have included a detailed medical history,

**NOSHEEN FATIMA, MASEEH UZ ZAMAN, AREEBA ZAMAN<sup>1</sup>, UNAIZA ZAMAN<sup>1</sup>, SIDRA ZAMAN<sup>1</sup>, RABIA TAHSEEN<sup>2</sup>**

Departments of Radiology and <sup>2</sup>Radiation Oncology, Aga Khan University Hospital, <sup>1</sup>Department of Medicine, Dow Medical College, Ruth Pfau Hospital, Karachi, Pakistan

**Address for correspondence:** Prof. Maseeh Uz Zaman, Department of Radiology, Aga Khan University Hospital, Karachi, Pakistan.  
E-mail: maseeh.uzzaman@aku.edu

**Submitted:** 24-Oct-2018, **Accepted:** 20-Nov-2018, **Published:** 23-Jul-2019

This is an open access journal, and articles are distributed under the terms of the Creative Commons Attribution-NonCommercial-ShareAlike 4.0 License, which allows others to remix, tweak, and build upon the work non-commercially, as long as appropriate credit is given and the new creations are licensed under the identical terms.

**For reprints contact:** reprints@medknow.com

**How to cite this article:** Fatima N, Zaman MU, Zaman A, Zaman U, Zaman S, Tahseen R. Detection efficiency of  $^{18}\text{F}$ -flourodeoxyglucose positron emission tomography/computed tomography for primary tumors in patients with carcinoma of unknown primary. World J Nucl Med 2020;19:47-51.

### Access this article online

#### Website:

www.wjnm.org

#### DOI:

10.4103/wjnm.WJNM\_93\_18

#### Quick Response Code



complete physical examination, histopathological review of biopsy material with the use of immunohistochemistry, chest radiography, computed tomography (CT), magnetic resonance imaging (MRI), endoscopic techniques, and mammography in some cases.<sup>[5]</sup> These diagnostic investigations are expensive, time-consuming, and inconvenient to patients and in 40%–50% fail to find primary tumor.<sup>[6]</sup> This demands a noninvasive imaging tool with high diagnostic performance. Whole-body detection of primary tumor can be achieved with positron emission tomography/CT (PET/CT) using 18-Fluorodeoxyglucose (<sup>18</sup>FDG) exploiting the high metabolic turnover in cancer cells. Although relative nonspecificity of FDG may pose a challenge anatomical details provided by CT has greatly enhanced the assessment of hypermetabolic foci.<sup>[7]</sup> Published studies have shown a higher detection of primary tumor (24%–40%) by <sup>18</sup>FDG PET/CT than CT or MRI (20%–27%).<sup>[1]</sup>

The purpose of this study was to find the detection efficiency of <sup>18</sup>FDG PET/CT in patients with CUP.

## METHODS

This was a prospective study conducted at PET/CT Section of Department of Radiology, Aga Khan University Hospital Karachi, Pakistan, from August 2017 to January 2018. Patients with a history of CUP referred for <sup>18</sup>FDG PET/CT scan for detection of primary sites during the study were recruited. Informed consent was obtained from all patients as per Institutional Ethical Review Committee policy. We included consecutive patients with biopsy-proven metastatic disease in whom detailed physical, laboratory investigation, CT, MRI, and endoscopic procedures failed to identify primary tumor sites. Patients with indeterminate biopsy findings for malignancy were excluded from the study. Patients with a suspected primary tumor site on <sup>18</sup>FDG PET/CT had biopsy. Scan findings and biopsy results were analyzed to find the detection rate, sensitivity, area under curve (AUC), and positive predictive value (PPV). As no biopsy was performed in negative scan, true negative and specificity could not be calculated.

### 18-Fluorodeoxyglucose positron emission tomography/computed tomography imaging

<sup>18</sup>FDG PET/CT was performed as per institutional protocol adopted from EANM guidelines.<sup>[8]</sup> All patients had 4–6 h fasting (only plain water was allowed) and a fasting blood sugar (FBS) <200 mg% before receiving an intravenous <sup>18</sup>FDG dose of 3 MBq/kg in the uptake room. During uptake period (55–75 min), patients were requested to lie comfortably and allowed to take about 500–1000 ml of plain water. The bladder was emptied before call the patient for PET/CT imaging suite equipped with Celesteion, Toshiba,

Japan. A low-dose CT examination (midbrain to mid-thigh) without intravenous contrast from head to toe followed by the acquisition of PET imaging using 3 min/bed position from toe to head in all patients. Both PET and CT images were acquired with patients under normal tidal breathing. PET (both nonattenuation corrected and attenuation corrected), CT and fusion <sup>18</sup>FDG PET/CT images were examined in axial, coronal, and sagittal planes on the manufacturer's review station. All <sup>18</sup>FDG PET/CT images were evaluated by two nuclear physicians having an experience of more than 5 years. On a transaxial, attenuation-corrected PET image, the maximum standardized uptake values (SUVmax) were obtained by placing regions of interest on hypermetabolic lesions that had been identified on visual analysis.

### Biopsy of suspected primary tumor

Patients with a hypermetabolic suspected primary tumor sites underwent a CT or ultrasound-guided core biopsies. Scan findings and biopsy results were analyzed to find the detection rate, sensitivity, AUC and PPV. No biopsy was performed in patients with a negative <sup>18</sup>FDG PET/CT scan for suspected primary tumor.

### Statistical analysis

Continuous variables were described by mean  $\pm$  standard deviation. Contingency table was drawn to calculate the frequency distribution of true positive, false positive and false negative. Detection rate, sensitivity, and PPV were calculated. Demographic distribution of metastatic sites was plotted in Pie chart. Receiver operating characteristics (ROC) curve was analyzed for the diagnostic strength of PET/CT in suggestive primary neoplasm. Statistical significance was defined as  $P < 0.05$ . Commercially available packages Microsoft excel 2010, Medcalc<sup>®</sup> and statistical package for social sciences (SPSS 19<sup>®</sup>, IBM, Armonk, New York, US) were used.

## RESULTS

During the study, 46 consecutive patients with CUP were included. Mean age of cohort was  $58 \pm 17$  years (63% male and 37% female) having a mean body mass index of  $24.70 \pm 4.97$  kg/m<sup>2</sup> [Table 1]. Biopsy revealed metastatic tumor involving nodes (26%), musculoskeletal system (26%), liver (20%), pleura (15%), ascites (09%), and brain (04%) [Figure 1]. Mean FBS, <sup>18</sup>FDG dose, and uptake time were  $110 \pm 32$  mg/dl,  $181 \pm 54$  MBq, and  $65 \pm 12$  min, respectively. CT dose index, dose length product, and mean hepatic SUV were  $5.46 \pm 1.17$  mGy,  $645.52 \pm 146.62$  (mGy.cm), and  $1.77 \pm 0.55$ , respectively [Table 1]. Thirty-four patients found to have a hypermetabolic focus (mean SUVmax  $9.1 \pm 4.9$  (range: 3.8–22.0) suggestive of primary tumor with known metastatic sites and subjected to biopsy

[Table 1]. Biopsy of hypermetabolic foci was positive for primary tumor in 26 giving a detection rate of 57% (26/46). In remaining eight patients, biopsy of hypermetabolic foci revealed benign findings (8/46%–17%) [Table 2]. Primary tumors detected on biopsy were found in gastrointestinal and hepatobiliary tract in 8 (17%), head and neck in 6 (13%), genitourinary 4 (09%), lung 3 (06%), and miscellaneous sites in 5 (11%) patients [Table 3]. Detection rate, sensitivity, and PPV of <sup>18</sup>FDG PET/CT were 57%, 68%, and 76%, respectively. As remaining 12/46 patients with a negative <sup>18</sup>FDG PET/CT

for suggestive primary tumor did not undergo biopsy, so true negative results and specificity could not be calculated (26% false negative) [Table 2]. ROC curve revealed good diagnostic strength of <sup>18</sup>FDG PET/CT for detecting unknown primary (AUC 0.667; P = 0.054; standard error = 0.083; confidence interval: 0.504–0.830) [Figure 2].

**Table 1: Study demographics**

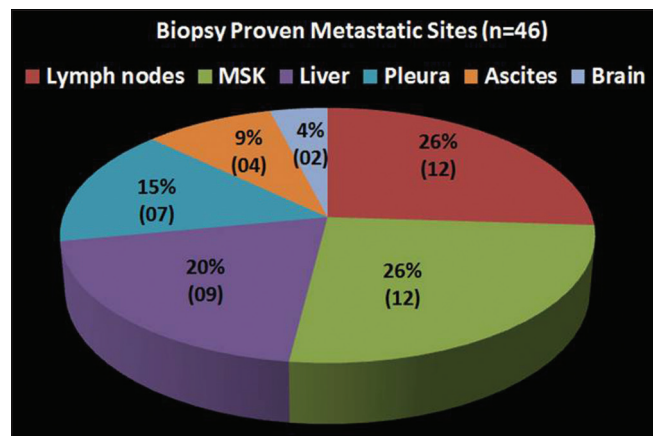
Variables	n=46
Age (years), mean±SD (range)	58±17 (14-87)
Gender (male:female) (%)	29:17 (63:37)
BMI (kg/m <sup>2</sup> ), mean±SD	24.70±4.97
FDG dose (MBq), mean±SD	181±54
FBS (mg/dl), mean±SD	110±32
Duration (min), mean±SD	65±12
CTDI, mean±SD	5.46±1.17
DLP, mean±SD	645.52±146.62
Mean liver uptake, mean±SD	1.77±0.55
SD of mean liver uptake, mean±SD	0.27±0.10
SUV <sub>max</sub> , mean±SD	9.1±4.9 (3.8-22.0)

BMI: Body mass index; SD: Standard deviation; FDG: Fluorodeoxy glucose; FBS: Fasting blood sugar; CTDI: Computed tomography dose index; DLP: Dose length product; SUV<sub>max</sub>: The maximum standardized uptake values

**Table 2: Contingency table**

PET/CT findings	Biopsy positive	Biopsy negative	Total
Positive for suggestive primary	26 (TP)	8 (FP)	34 (all positive)
PET/CT findings	Biopsy not performed	Total	
Negative for suggestive primary	12 (FN)	12 (all negative)	
-		46 (total)	

Detection rate: 57%; FP: 17%; FN: 26%; Sensitivity: 68%; PPV: 76%.  
 FP: False positive; FN: False negative; PPV: Positive predictive value;  
 PET/CT: Positron-emission-tomography/computed tomography

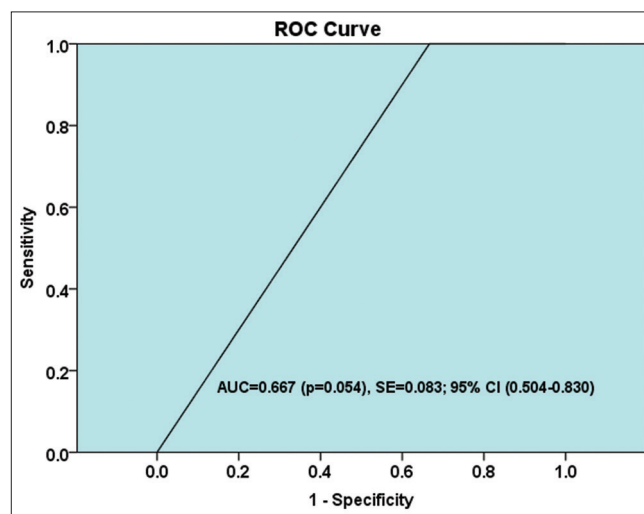


**Figure 1: Distribution of biopsy proven metastatic sites for carcinoma of unknown primary**

**DISCUSSION**

The presence of histopathologically proven malignancy in one or more metastatic site(s) and failure to detect the primary tumor by routine diagnostic algorithm are the prerequisites for the diagnosis of CUP. CUP is predominantly seen between the fifth and seventh decades with slightly more prevalent in men than in women, and despite intensive diagnostic efforts, the primary tumor cannot be detected even at autopsy in almost two-third of patients and reflects the diagnostic challenge of currently available imaging modalities.<sup>[9]</sup> Detection of the primary tumor in patients with CUP is vitally important as it improves overall survival as compared to those in whom no primary tumor is identified.<sup>[4]</sup> <sup>18</sup>FDG PET/CT has become an important step in diagnostic paradigm as vast majority of malignant cancer phenotypes exhibit an increased glucose metabolism (Warburg effect).<sup>[10]</sup>

In the current study, <sup>18</sup>FDG PET/CT successfully identified primary tumor with a detection rate of 57% and fair diagnostic strength as revealed by ROC. Published studies from various part of the world document a variable detection rate of <sup>18</sup>FDG PET/CT in CUP, ranging from none<sup>[11]</sup> to as high as 80%.<sup>[12]</sup> The reason for this diversified detection rate could be a small sample size of many studies, use of nonstandardized imaging



**Figure 2: Receiver operating characteristics curve of positron emission tomography/computed tomography findings for suggestive primary neoplasm (AUC: Area under curve; SE: Standard error; CI: Confidence interval)**

**Table 3: Distribution of suggestive primary findings on positron-emission-tomography/computed tomography and correlation with biopsy**

Suggestive primary on PET/CT	Total (34)	Biopsy positive (TP)	Biopsy negative (FP)
Stomach	4	3	1
Esophagus	2	1	1
Colon	3	3	-
Pancreatobiliary	1	1	-
Head and neck CA	8	4	4
Nasopharynx	2	2	-
CA lung	3	3	-
Breast	2	2	-
Musculoskeletal	5	5	-
RCC	1	1	-
Prostate	1	1	-
Brain	1	-	1
Liver	1	-	1

TP: True positive; FP: False positive; RCC: Renal cell carcinoma; PET/CT: Positron-emission-tomography/computed tomography; CA: Cancer

protocol and scanners with different spatial resolution. Our finding is in concordance with findings of Freudenberg *et al.*, who also reported a detection rate of 57%.<sup>[13]</sup> However, a recently published meta-analysis of 20 studies comprising 1942 patients revealed a pooled detection rate of 40.93%.<sup>[14]</sup> This meta-analysis also pointed out a large heterogeneity between studies, lack of randomization and nonstandardized diagnostic workup used in these studies. The false positive proportion in our study was 17% which is due to established nonspecific uptake of <sup>18</sup>FDG in benign inflammatory, infective lesion, or pulmonary embolism which is seen in 4% of patients with cancer.<sup>[15]</sup> This is in accordance with published data like 19% by Elboga *et al.* 2014<sup>[9]</sup> and 2.3%–22.2% found in a recently published meta-analysis.<sup>[14]</sup> However, it is imperative to realize that false-positive <sup>18</sup>FDG PET/CT findings may result in unnecessary additional invasive diagnostic procedures, which have associated morbidities and costs.<sup>[4]</sup> This limitation highlights the importance and need of more specific PET probes in the diagnostic work-up of CUP.

In the current study, false-negative proportion was 26% which is lower than 48% reported by Elboga *et al.*<sup>[9]</sup> Park *et al.*,<sup>[11]</sup> failed to find a primary tumor site in none of 20 patients with CUP who had an <sup>18</sup>FDG PET/CT giving a false negative result of 100%. Furthermore, it must be acknowledge that despite extensive workup, the diagnostic yield of imaging modality for primary tumor is <20% and 70% of cases remained undiagnosed on autopsy as well.<sup>[4]</sup> The reason for this diagnostic dilemma has still not been clarified. Common plausible explanations are as follows: (1) tumor smaller than spatial resolution of PET/CT scanner causing no appreciation of <sup>18</sup>FDG uptake due to partial volume effect; (2) some tumors with low or no avidity for <sup>18</sup>FDG such as lobular cancer of

breast, bronchoalveolar carcinoma, or well differentiated prostate cancer; and (3) progressive or delayed <sup>18</sup>FDG uptake by tumor appreciable when target to background ratio is increased in delayed images.<sup>[4]</sup> Common hypotheses include spontaneous regression or immune-mediated destruction of the primary tumor or the inherent small size of the primary tumor (metastatic spread is favored above local tumor growth) beyond the spatial resolution of scanner.<sup>[5,16]</sup>

Major limitation of our study is small sample size, although a recent meta-analysis of 20 studies revealed median number of patients of 72 (range: 21–316).<sup>[14]</sup> Other major limitation is that we did not acquire delayed images in patients who failed to reveal a suggestive primary tumor as it would result in unjustified delay in scheduled imaging of subsequent patients.

We conclude that <sup>18</sup>FDG PET/CT is an effective tool for the detecting primary tumor in patients with CUP and its upfront use could preclude the use of many futile diagnostic procedures. Furthermore, higher resolution scanners and acquiring delayed images in patients with negative study could reduce false-negative results in patients with CUP.

#### Financial support and sponsorship

Nil.

#### Conflicts of interest

There are no conflicts of interest.

#### REFERENCES

- Kim KW, Krajewski KM, Jagannathan JP, Nishino M, Shinagare AB, Hornick JL, *et al.* Cancer of unknown primary sites: What radiologists need to know and what oncologists want to know. *AJR Am J Roentgenol* 2013;200:484-92.
- Fizazi K, Greco FA, Pavlidis N, Pentheroudakis G; ESMO Guidelines Working Group. Cancers of unknown primary site: ESMO clinical practice guidelines for diagnosis, treatment and follow-up. *Ann Oncol* 2011;22 Suppl 6:vi64-8.
- Fernandez-Cotarelo MJ, Guerra-Vales JM, Colina F, de la Cruz J. Prognostic factors in cancer of unknown primary site. *Tumori* 2010;96:111-6.
- Kwee TC, Basu S, Cheng G, Alavi A. FDG PET/CT in carcinoma of unknown primary. *Eur J Nucl Med Mol Imaging* 2010;37:635-44.
- Pavlidis N, Fizazi K. Carcinoma of unknown primary (CUP). *Crit Rev Oncol Hematol* 2009;69:271-8.
- Aglund M, Kjems E. Statistics on Cancer of Unknown Primary (in Danish) [The Danish Cancer Society]; 12 January, 2017. Available from: <https://www.cancer.dk/hjaelp-viden/kraeftformer/metastaser-spredning/ukendt-primar-tumor/statistik-ukendt-primar-tumor/>. [Last accessed on 2018 Apr 30].
- Taylor MB, Bromham NR, Arnold SE. Carcinoma of unknown primary: Key radiological issues from the recent national institute for health and clinical excellence guidelines. *Br J Radiol* 2012;85:661-71.
- Boellaard R, Delgado-Bolton R, Oyen WJ, Giammarile F, Tatsch K, Eschner W, *et al.* FDG PET/CT: EANM procedure guidelines for tumour

- imaging: Version 2.0. *Eur J Nucl Med Mol Imaging* 2015;42:328-54.
9. Elboga U, Kervancıoğlu S, Sahin E, Basibuyuk M, Celen YZ, Aktolun C. Utility of F-18 fluorodeoxyglucose positron emission tomography/computed in carcinoma of unknown primary. *Int J Clin Exp Pathol* 2014;7:8941-6.
  10. Rohren EM, Turkington TG, Coleman RE. Clinical applications of PET in oncology. *Radiology* 2004;231:305-32.
  11. Park JS, Yim JJ, Kang WJ, Chung JK, Yoo CG, Kim YW, *et al.* Detection of primary sites in unknown primary tumors using FDG-PET or FDG-PET/CT. *BMC Res Notes* 2011;4:56.
  12. Roh JL, Kim JS, Lee JH, Cho KJ, Choi SH, Nam SY, *et al.* Utility of combined (18)F-fluorodeoxyglucose-positron emission tomography and computed tomography in patients with cervical metastases from unknown primary tumors. *Oral Oncol* 2009;45:218-24.
  13. Freudenberg LS, Fischer M, Antoch G, Jentzen W, Gutzeit A, Rosenbaum SJ, *et al.* Dual modality of 18F-fluorodeoxyglucose-positron emission tomography/computed tomography in patients with cervical carcinoma of unknown primary. *Med Princ Pract* 2005;14:155-60.
  14. Burglin SA, Hess S, Høiland-Carlsen PF, Gerke O. 18F-FDG PET/CT for detection of the primary tumor in adults with extracervical metastases from cancer of unknown primary: A systematic review and meta-analysis. *Medicine (Baltimore)* 2017;96:e6713.
  15. Gladish GW, Choe DH, Marom EM, Sabloff BS, Broemeling LD, Munden RF. Incidental pulmonary emboli in oncology patients: Prevalence, CT evaluation, and natural history. *Radiology* 2006;240:246-55.
  16. Pentheroudakis G, Briasoulis E, Pavlidis N. Cancer of unknown primary site: Missing primary or missing biology? *Oncologist* 2007;12:418-25.