

Anatomical variations of pterion: analysis of the possible anatomical variations of pterion in human skulls**

RUIZ, C. R.¹, SOUZA, G. C.², SCHERB, T. O.² and NASCIMENTO, S. R. R.^{1*}

¹Postgraduate course in Macroscopic and Radiologic Imaging Anatomy, Centro Universitário São Camilo, Avenida Nazaré, 1501, Ipiranga, CEP 04263-200, São Paulo, SP, Brazil

²Centro Universitário São Camilo, Avenida Nazaré, 1501, Ipiranga, CEP 04263-200, São Paulo, SP, Brazil

*E-mail: riosnascimento@uol.com.br

Abstract

Introduction: The pterion is an anatomical region located in the temporal fossa between frontal, sphenoid, and temporal bones. In the literature, we observed that the pterion can suffer many anatomical variations which depend on several factors, such as gender and ethnicity, and its form can vary in relation to the skull side.

Objectives: To study and analyze the variations that can occur in the pterion, related to the type and symmetry, in relation to gender, age, side of the skull and ethnicity. **Materials and Methods:** We examined 55 skulls of both sexes belonging to the Department of Skulls Museum of Anatomy Descriptive and Topographic UNIFESP. The Pterions were outlined with pencil on tracing paper and from this drawing and the information of each skull perform our analysis. **Results:** In our sample, the pterion types vary as follows: sphenoparietal (90%), frontotemporal (4.54%), epiteric (3.64%) and stellate (1.82%). The most common types of female skulls were sphenoparietal (85%), and the least common types were stellate (2.5%). For the male skulls, the most common types were sphenoparietal (92.86%), and the least common types were stellate (1.43%). For the skull of white subjects, the most common types were sphenoparietal (98.08%), and the least common types were frontoparietal (1.92%). For the skull of non-white subjects, the most common types were sphenoparietal (82.75%), and the least common types were stellate (3.45%). **Conclusion:** We concluded that the most common pterions found in the entire sample were the sphenoparietal being predominant in sex, ethnicity, and side but there are variations in relation to the least common pterion types taking into consideration side, sex, and ethnicity.

Keywords: anatomic variations, skull, pterion.

1 Introduction

The pterion is an anatomical region located in the temporal fossa, where the frontal, sphenoid, temporal and parietal bones join (URZÌ, IANNELLO, TORRISI et al., 2003). The pterion is of great relevance and it has been studied since the 19th century (SUTTON, 1884), being used as a landmarker to several brain regions (OGUZ, SANLI, BOZKIR et al., 2004). It is located about 4.0 cm above the zygomatic arch and 3.5 cm behind the frontozygomatic suture. It is considered an important surgical area because it marks the anterior branch of middle meningeal artery and the axial position of the lesser wing of the sphenoid bone (WILLIAMS, WARWICK, DYSON et al., 1995). Fractures on the pterion can damage the anterior branch of middle meningeal artery causing an extradural hematoma (LAMA and MOTTOLESE, 2000).

Apart from the middle meningeal artery, other structures are also reported in the pterion region: the cerebral artery, the anterior pole of the insula and Broca's área (LINDSAY, BONE and CALLANDER, 1991), closely connected to several brain structures. The close region to the pterion can be used to perform surgeries in the motor Broca's area, in aneurysms recovery of middle meningeal artery and of superior basilar complex

(LINDSAY, BONE and CALLANDER, 1991; ESCOSA-BAGÉ, SOLA, LIBERAL-GONZÁLEZ et al., 2002). Furthermore, the pterion is also related to cranial sutures closing, being an important guide to age estimate and sex determination in forensic and anthropological samples (LOVEJOY, MEINDL, MENSFORTH et al., 1985; ILKNUR, MUSTAFA and SINAN, 2009).

It was observed in the literature that the pterion can suffer variations in its anatomy, depending on factors such as sex, age, side of skull, and ethnicity. Depending on bone junctions, it can be classified as sphenoparietal, frontotemporal, stellate, and epiteric.

Due to great pterion anatomical importance, our aim is to study and to analyse what variations can occur in the pterion region regarding type and symmetry, sex, age, side of skull, and ethnicity (PRABA and VENKATRAMANIAH, 2012).

2 Methods

We examined 55 skulls of both sexes which belong to the Department of Descriptive and Topographic Anatomy (UNIFESP). The pterions were outlined with pencil on tracing paper. From this drawing, with the identification of each bone (frontal - f; sphenoid - s; parietal - p, and temporal - t) and the information of each skull (age, ethnicity and sex), we performed our analysis. For the statistical tests, we carried out the chi-squared test, the Cramer test, and the Marascuilo procedure in cases where the chi-squared test rejected the hypothesis of independent variables.

** This Research was conducted by Centro Universitário São Camilo, at Avenida Nazaré, 1501, Ipiranga, São Paulo, SP, CEP 04263-200, Brasil, in partnership with the Universidade Federal de São Paulo - UNIFESP at Rua Sena Madureira, 1500, Vila Clementino, São Paulo, SP, CEP 04021-001, Brazil.

3 Results

The pterion can be seen in four distinct forms: sphenoparietal type (Figure 1), a standard suture in which the sphenoid and the parietal bones are in direct contact; frontotemporal type (Figure 2) in which the frontal and the temporal bones are in direct contact; stellate type (Figure 3) characterized by four bones joint in a single place; and the last, epiteric type (Figure 4) which has a small bone suture among the four bones. The four types of pterions were found in our study.

In our sample (55 skulls = 110 pterions), the pterion shape varied as follow: 99 were sphenoparietal (90%); 5 were frontotemporal (4.54%); 4 were epiteric (3.64%); and 2 were stellate (1.82%).

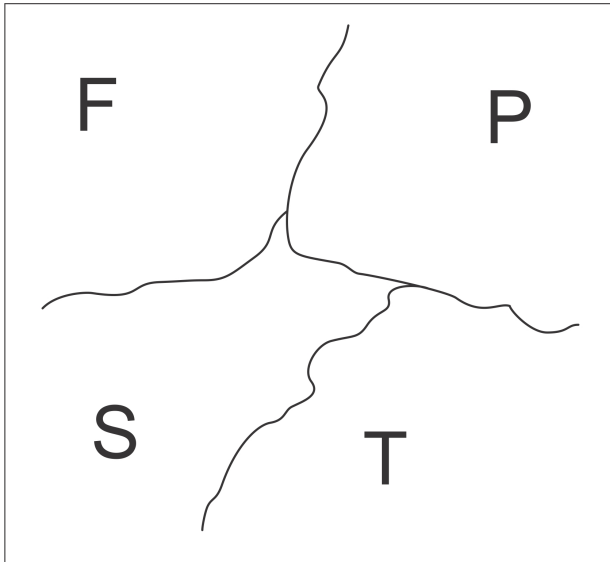


Figure 1. Sphenoparietal pterion. F: frontal bone; P: parietal bone; S: sphenoid bone; T: temporal bone. Left side.

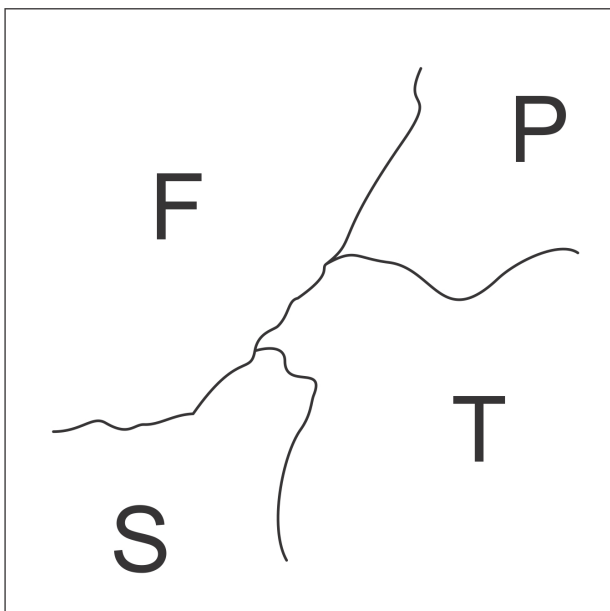


Figure 2. Frontotemporal pterion. F: frontal bone; P: parietal bone; S: sphenoid bone; T: temporal bone. Left side.

In the 20 female skulls (40 pterions) were found the following rate: 34 sphenoparietal (85%); 2 frontotemporal (5%); 3 epiteric (7.5%); and 1 stellate (2.5%). The most common type was the sphenoparietal and the least common was the stellate. In the 35 male skulls (70 pterions) were found the following rate: 65 sphenoparietal (92.86%) this one being the most common; 3 frontotemporal (4.28%); 1 epiteric (1.43%) this one being the least common (Table 1).

For the 26 skulls (52 pterions) of white subjects, the most common was sphenoparietal accounting for 51 pterions (98.08%); and the least common was frontotemporal with only 1 (1.92%). It was not found epiteric and stellate pterion types. For the non-white subjects, out of 29 skulls (58 pterions), the most common was sphenoparietal accounting for 48 pterions (82.75%); and the least common was stellate with 2 pterions (3.45%). For the frontotemporal and epiteric types, the rate was 6.90% (4 pterions) (Table 2)

On both sides (right and left), the most common pterion type was sphenoparietal: 49 on the right side (89.10%), and 50 on the left side (90.91%). The least common types were the epiteric (1 pterion, 1.82%) and the stellate (1 pterion, 1.82%). On the right side, 4 frontotemporal pterions were found (7.2%), and, on the left side, there were 3 epiteric pterions (5.45%).

From all analysed skulls, 46 presented the same pterion types on both sides (83.63%). Among them, there was a difference regarding suture lines. From 46 skulls, 29 (63.04%) had their suture lines in different direction or height.

In relation to epiteric and stellate pterion types, they always presented themselves unilaterally, and, on the other side, the sphenoparietal type was found. The frontotemporal type was

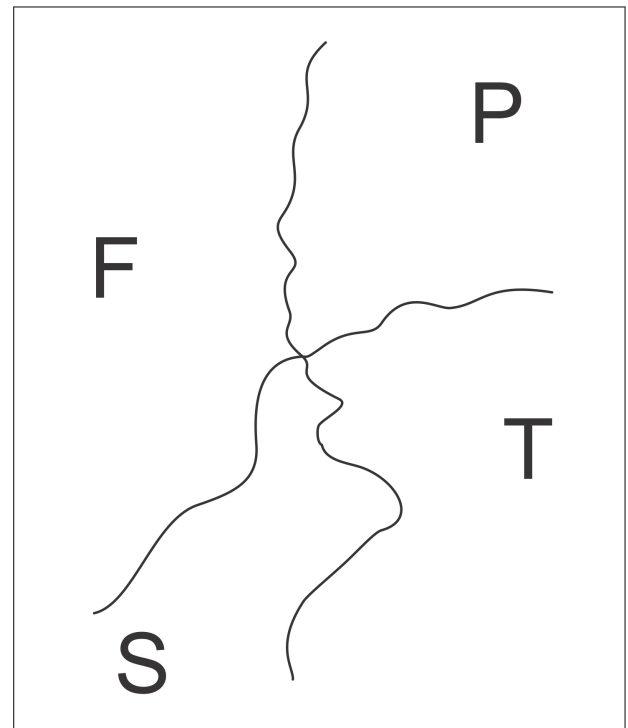


Figure 3. Stellate pterion. F: frontal bone; P: parietal bone; S: sphenoid bone; T: temporal bone. Left side.

present associated to other frontotemporal type one time and to sphenoparietal type other times (Table 3 and 4).

Moreover, it was observed the sutural bones presence but this fact did not alter the conformation of the pterion regarding

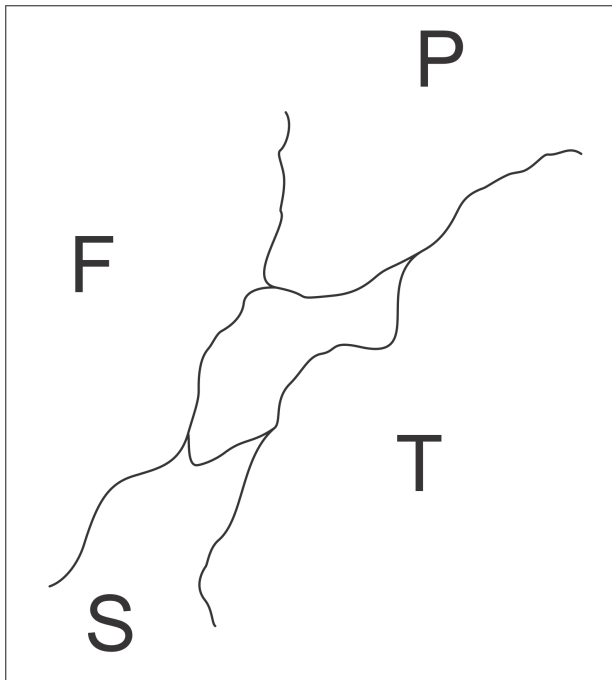


Figure 4. Epiteric pterion. F: frontal bone; P: parietal bone; S: sphenoid bone; T: temporal bone. Left side.

the epiteric type. From 110 analysed pterions, 7 presented sutural bones (6.36%), and all of them was associated to sphenoparietal type. These sutural bones were found in the following proportions: 5 to the right side (71.43%), and 2 to the left side (28.57%); 5 belonging to female skulls (71.43%), and 2 belonging to male skulls (28.57%), 4 in white subjects skulls (57.15%), and 3 in non-white subjects skulls (42.85%).

4 Discussion

The pterion anatomical variations reported in the literature occur due to some factors such as sex, age, ethnicity, and side of skull. These variations normally appear in relation to the way the bones join and form the pterion region (PRABA and VENKATRAMANIAH, 2012). Some authors described the pterion in K, X or H shape, horizontal or vertical being that the H shape classification is the most found. In our study, we used the Praba and Venkatramaniah classifications (PRABA and VENKATRAMANIAH, 2012) which categorize the pterions in frontotemporal, sphenoparietal, epiteric, and stellate.

Symmetry is not common among the pterions shape lines on one side and their configuration on the opposite side because the pterion has within the skull a pattern that normally doesn't overlay the one which is on the outer skull surface (MENDES, 1988).

Some authors studied different populations to determine the most common pterion type. According to Zalawadia, VADGAMA, RUPARELIA et al. (2010), in eight different ethnicity analysis on pterion type, the sphenoparietal type is always the most found in all ethnicities, varying from 66% to 95.3% what supports our study (98.08% of sphenoparietal

Table 1. Distribution of the pterion regarding gender.

	Sphenoparietal	Frontotemporal	Epiteric	Stellate	Total
Male	65	3	1	1	70
Female	34	2	3	1	40
Total	99	5	4	2	110

Table 2. Distribution of the pterion regarding ethnicity.

	Sphenoparietal	Frontotemporal	Epiteric	Stellate	Total
White	51	1	0	0	52
Non-white	48	4	4	2	58
Total	99	5	4	2	110

Table 3. Distribution of the pterion regarding side.

	Sphenoparietal	Frontotemporal	Epiteric	Stellate	Total
Right	49	4	1	1	55
Left	50	1	3	1	55
Total	99	5	4	2	110

Table 4. Correlation between the side and displayed pterion.

	Sphenoparietal L	Frontotemporal L	Epiteric L	Stellate L	Total
Sphenoparietal R	45	0	3	1	49
Frontotemporal R	3	1	0	0	4
Epiteric R	1	0	0	0	1
Stellate R	1	0	0	0	1
Total	50	1	3	1	110

pterions). Furthermore, the least common type found varied between stellate and epiteric, dissonant to our results (frontotemporal 1.92% of white subjects and stellate 3.45% of non-white subjects). In a study realized with Nigerians by Asala and Mbajiorgu (1996), the stellate type was not found, and in a study realized with Koreans by Lee, Park, Kwon et al. (2001), the stellate and frontotemporal pterion types were not found.

A study performed by Saxena, Jain and Chowdhary (1988) used 40 Nigerians skulls and 72 Indians skulls obtained at Anatomy Department of Jos University, in Nigeria. All four pterion variations were found. The frequency of sphenoparietal pterion was high in both ethnicities (Indians 95.3% and Nigerians 84.79%) again in agreement with our results, while the frontotemporal (Indians 3.46% and Nigerians 10.11%), and stellate (Indians 1.38% and Nigerians 5.06%) are more common in Nigerians. The epiteric type in turn is more common in Indians (11.79%) than in Nigerians (3.79%).

Ukoha, Oranusi, Okafor et al. (2013) verified that in a sample of Nigerian population, the sphenoparietal type was also the most common, appearing in 75% of the skulls, on both sides, followed by frontotemporal (19.6% on both sides) and by epiteric (3.6% on both sides). The stellate type appeared only in 1.8% of the skulls and just on the right side. The data are in the same order as our results in relation to total sampling (sphenoparietal 90%, frontotemporal 4.54%, epiteric 3.64% and stellate 1.82%).

In the Turkish population, the sphenoparietal pterion type was the most common (96% on the right side and 79% on the left side), and the epiteric was the least common (none on the right side and 4% on the left side), while the stellate type was not even found in this ethnicity based on this study. There is also asymmetry in relation to both sides of skulls being that normally is not found the same pterion type on both sides of skulls (SUTTON, 1884). This asymmetry was found in our sample as well.

Zalawadia et al. (2010) showed that all pterions types were found in the West region of Gujarat, in India. Again, the sphenoparietal was the most common and most found on both sides of the same skulls (91.7%), followed by the epiteric type (4.8%). A single stellate type was observed on the left side of a skull while on the opposite side there was the sphenoparietal type, likewise the sample found in our population.

Ma, Baillie and Stringer (2012) developed a study bringing in 30 women and 20 men to CT skull examination and obtained these results: 78.3% pterions were sphenoparietal type, followed by epiteric type with 16.4%, and frontotemporal type 5.2%, no stellate configuration was identified. The symmetry of the pterions types occurred in 62% of skulls (61% in male skulls and 64% in female skulls).

Several studies have been already performed with primates and humans with the same structure. According to Wang, Opperman, Havill et al. (2006), humans pterion differs in pattern from primates pterion in comparison to other species. While in humans the most common is sphenoparietal, in primates the most common is frontotemporal. The stellate type is the least common, as well as in humans.

5 Conclusions

We can conclude that the proportion of pterion types vary in relation to ethnicity, sex, and side of skulls. However, the most common in humans is the sphenoparietal in any category. The stellate and epiteric conformations are the least common.

The frontotemporal pterion, when it is present, is more found on the right side of skulls. The stellate pterion, when it is present, is more found on the left side of skulls.

Statistically, there is not a correlation between the pterion type found and the side of skull observed (chi-square: 2.81), and nor there is a correlation between sex of subject and pterion type (chi-square: 2.94). However, there is a statistical correlation between pterion type and ethnicity (chi-square: 7.58 with p : 0.2-0.25), although this correlation is not significant (Cramér coefficient: 0.263). The pterion proportion of sphenoparietal type in white subjects is significantly larger, and the pterion proportion of frontotemporal, stellate, and epiteric types in non-white subjects is meaningfully larger.

We also concluded that the pterion type of one side of skulls is not necessarily the same on the other side, and to have the same symmetry is not a rule. Nevertheless, the sphenoparietal type is the most common on both sides (left and right) of observed skulls. Variations regarding age were not found.

References

- ASALA, SA. and MBAJIORGU, FE. Epigenetic variation in the Nigerian skull: sutural pattern at the pterion. *East African Medical Journal*, 1996, vol. 73, n. 7, p. 484-486.
- ESCOSA-BAGÉ, M., SOLA, RG., LIBERAL-GONZÁLEZ, R., CANIEGO, JL. and CASTRILLO-CAZÓN, C. Fusiform aneurysm of the middle cerebral artery. *Revista de Neurología*, 2002, vol. 34, n. 7, p. 655-658. PMID:12080516.
- ILKNUR, A., MUSTAFA, KI. and SINAN, B. Comparative study of variation of the pterion of human skulls from 13th and 20th century anatolia. *International Journal of Morphology*, 2009, vol. 27, n. 4, p. 1291-1298. <http://dx.doi.org/10.4067/S0717-95022009000400051>.
- LAMA, M. and MOTTOLESE, C. Middle meningeal artery aneurysm associated with meningioma. *Journal of Neurosurgical Sciences*, 2000, vol. 44, n. 1, p. 39-41. PMID:10961495.
- LEE, UY., PARK, DK., KWON, SO., PAIK DJ. and HAN, SH. Morphological analysis of the pterion in Korean. *Korean Journal of Physical Anthropology*, 2001, vol. 14, n. 4, p. 281-289.
- LINDSAY, K., BONE, I. and CALLANDER, R. *Neurology and neurosurgery illustrated*. 2nd ed. Hong Kong: Churchill Livingstone, 1991.
- LOVEJOY, CO., MEINDL, RS., MENSFORTH, RP. and BARTON, TJ. Multifactorial determination of skeletal age at death: a method a blind tests of its accuracy. *American Journal of Physical Anthropology*, 1985, vol. 68, n. 1, p. 1-14. PMID:4061595. <http://dx.doi.org/10.1002/ajpa.1330680102>.
- MA, S., BAILLIE, LJ. and STRINGER, MD. Reappraising the surface anatomy of the pterion and its relationship to the middle meningeal artery. *Clinical Anatomy*, 2012, vol. 25, n. 3, p. 330-339. PMID:21800374. <http://dx.doi.org/10.1002/ca.21232>.
- MENDES, JC. *As origens do homem: bases anatômicas da hominização*. Lisboa: Fundação Calouste Gulbenkian, 1988.
- OGUZ, Ö., SANLI, SG., BOZKIR, MG. and SOAMES, RW. The pterion in turkish male skulls. *Surgical and Radiologic Anatomy*, 2004, vol. 26, n. 3, p. 220-224. PMID:14648037. <http://dx.doi.org/10.1007/s00276-003-0210-2>.
- PRABA, AMA. and VENKATRAMANIAH, C. Morphometric study of different types of pterion and It's relation with middle meningeal artery in dry skulls of Tamil Nadu. *Journal of Pharmaceutical and Biomedical Sciences*, 2012, vol. 21, n. 21, p. 1-4.

SAXENA, SK., JAIN, SP. and CHOWDHARY, DSA. Comparative study of pterion formation and its variations in the skulls of Nigerians and Indians. *Anthropologischer Anzeiger*, 1988, vol. 46, p. 75-82.

SUTTON, JB. On the relation of the orbito-sphenoid to the pterion in the side wall of the skull. *Journal of Anatomy and Physiology*, 1884, vol. 18, n. 2, p. 218-222. PMID:17231523.

UKOHA, U., ORANUSI, CK., OKAFOR, JI., UDEMEZUE, OO., ANYABOLU, AE. and NWAMARACHI, TC. Anatomic study of pterion in Nigerian dry human skulls. *Nigerian Journal of Clinical Practice*, 2013, vol. 16, n. 3, p. 325-328. PMID:23771454. <http://dx.doi.org/10.4103/1119-3077.113455>.

URZI, F., IANNELLO, A., TORRISI, A., FOTI, P., MORTELLARO, NF. and CAVALLARO, M. Morphological variability of pterion in the human skull. *Italian Journal of Anatomy and Embryology*, 2003, vol. 108, n. 2, p. 83-117. PMID:14503657.

WANG, Q., OPPERMAN, LA., HAVILL, LM., CARLSON, DS. and DECHOW, PC. Inheritance of sutural pattern at the pterion in rhesus monkey skulls. *The Anatomical Record. Part A, Discoveries in Molecular, Cellular, and Evolutionary Biology*, 2006, vol. 288, n. 10, p. 1042-1049. PMID: 16964596. <http://dx.doi.org/10.1002/ar.a.20373>.

WILLIAMS, PL., WARWICK, R., DYSON, M. and BANNISTER, L. H. *Gray anatomy*. 37. ed. Rio de Janeiro: Guanabara Koogan, 1995.

ZALAWADIA, A., VADGAMA, J., RUPARELIA, S., PATEL, S., RATHOD, SP. and PATEL, SV. *Morphometric study of pterion in dry skull of Gujarat region*. *National Journal of Integrated Research in Medicine*, 2010, vol. 1, n. 4, p. 25-29.

Received September 27, 2015

Accepted November 5, 2016