

Bilateral variation of anterior belly of digastric muscle

AZEREDO, R. A.¹, CESCO NETTO, L. A.^{2*} and TORRES, L. H. S.²

¹Department of Morphology, Health Science Center, Universidade Federal do Espírito Santo – UFES, Av. Marechal Campos, 1468 - térreo, CEP 29043-900, Vitória, ES, Brazil

²Health Science Center, Universidade Federal do Espírito Santo – UFES, Av. Marechal Campos, 1468 - térreo, CEP 29043-900, Vitória, ES, Brazil

*E-mail: lorenzzodac@hotmail.com

Abstract

Introduction: Digastric is a suprahyoid muscle and usually consists of two bellies. Its action consists in drawing the mental region downwards and backwards when opening the mouth, resulting in the depression of the mandible. **Methods and Results:** During a routine dissection of the cervical region, a muscle bundle arising from the intermediary tendon going towards the middle line was found. The supranumerary belly arised from the intermediary tendon so that some bundles inserted on the middle rafe and others continued towards the mento and inserted on the belly of mylohyoid muscle at the same side. These anatomic variations on the anterior belly of the digastric muscle could be significant during surgical procedures involving the submental region. **Conclusion:** Besides this surgical importance, we suggest that these supranumerary bellies have no direct action on the mandible, but on the floor of the mouth, due to its insertions on the mylohyoid muscle.

Keywords: anatomy, anatomic variation, digastric muscle.

1 Introduction

The digastric muscle is a suprahyoid muscle that usually consists of two portions or bellies, named anterior and posterior, connected by an intermediate tendon (ROUVIÈRE and DELMAS, 1964; GARDNER, GRAY and O'RAHILLY, 1967; MOORE, 1994; DI DIO, AMATUZZI and CRICENTI, 1998). The posterior belly arises from the mastoid notch located in the mastoid portion of the temporal bone and passes downward and forward towards the hyoid bone (GARDNER, GRAY and O'RAHILLY, 1967). The anterior belly of the digastric muscle, shorter and less bulky than the posterior belly, is inserted in the digastric fossa located in the inferior part of the mandible's body. It passes backwards and downwards. The intermediary tendon is thin, almost cylindrical and is fixed on the body and greater cornu of the hyoid bone by fibers derived from the cervical fascia. This tendon usually perforates the stylohyoideus muscle. Occasionally a synovial sheath can be found between the intermediary tendon and the fibrous sling.

The two bellies have distinct embryologic origins and consequently different innervations. The anterior belly originates from the first branchial arch and is innervated by mylohyoid nerve, a branch of the mandibular division of the trigeminal nerve while the posterior belly is derived from the second branchial arch and is innervated by the posterior auricular branch of facial nerve. These morphological and embryological differences led some authors (ROUVIÈRE and DELMAS, 1964) to affirm "the digastric muscle results from the union at their hyoid ends of two primarily distinct muscles".

The action of the digastric muscle consists in drawing the mental region downwards and backwards when opening the mouth, resulting in the depression of the mandible.

The intermediary tendon moves freely through its sheath, sliding forward and backward, which lets the whole muscle act on the mandible, starting from its insertion into the temporal bone (GARDNER, GRAY and O'RAHILLY, 1967; MOORE, 1994).

The aim of this study was describe and discuss a variant conformation of digastric muscle found during a routine desiccation, its application and importance in medical and dental field and the possible clinical implications.

2 Case Report

During a routine dissection of the cervical region in the Anatomy Lab of Dentistry Course of the University, bilateral variations in the structure of the digastric muscle were discovered. We found a muscle bundle arising from the intermediary tendon going towards the middle line and it was observed in in both sides of the neck, a fact considered rare according to literature (TESTUT, 1928; LE DOUBLE, 1987; PEKER, TURGUT and ANIL, 2000).

The supranumerary belly arised from the intermediary tendon so that some bundles inserted on the middle rafe and others continued towards the mento and inserted on the belly of mylohyoid muscle at the same side (Figure 1).

Observing and measuring the anterior belly of the digastric muscle with a paquimeter, we observed that the anterior right belly had 55 millimeters length, 14 millimeters width close to its insertion and 11 millimeters width close to the intermediary tendon, while the supranumerary belly at the same side was divided in two portions: the first crossed the middle line and inserted on the belly of the mylohyoid muscle

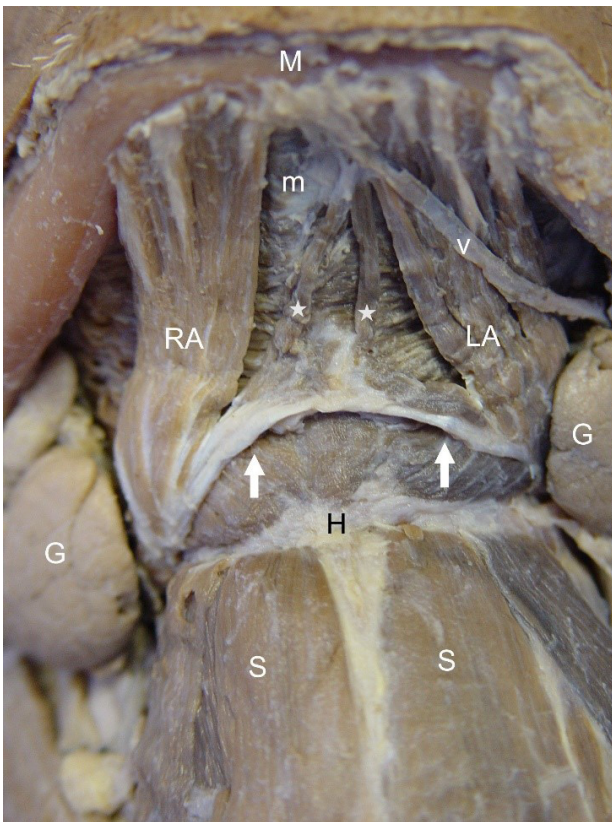


Figure 1. Anterior view of the suprahyoid muscles. (RA) right anterior belly and (LA) left anterior belly of the digastric muscles; (stars) right and left supranumerary bellies arising from the Tendinous Arch (Arrows) and inserting on the Mylohyoid Muscle (m). (M) Mandible; (v) submental vein; (G) submandibular gland; (H) hyoid bone; (S) Sternohyoid muscles (infrahyoid muscles).

in the opposite side and the second inserted on the middle rafe of the mylohyoid muscle.

On the left side of the same cadaver, the anterior belly measured 50 millimeters length, 14 millimeters width close to its insertion and 12 millimeters close to the intermediary tendon. Its important to mention that there were no bone insertions of the supranumerary bellies and that the supranumerary bellies inserted on the middle rafe of both sides acquired an archade form.

3 Discussion

Many anatomic variations have been described about the digastric muscle and these variations can affect its three parts. Gardner, Gray and O’Rahilly, 1967 (1967) state that the anterior bellies can be united by accessory bundles of muscle fibers. Rouvière and Delmas (1964) say that the anterior belly of the digastric muscle can receive some tendinous fiber bundles from the hyoid bone, independent of the intermediary tendon.

Earlier reports of Testut (1928) describes that the posterior belly may not pass through the stylohyoideus muscle and in this case, it passes before or after it. The posterior belly can also go directly from the base of the cranium to the mental symphysis without going down to the hyoid bone. In this case the intermediary tendon will be located above the

hypoglossal nerve and the lingual artery. This variation should be remembered in case of a ligation of this artery.

The right and left digastrics intermediary tendons can unite at the middle line of the neck consequently forming a transversal arcade where the anterior bellies arise, which can be completely fused in the middle line. The occurrence of an anterior belly supplying an extra bundle which can insert itself into the middle line or on hyoid bone or digastric fossa of the opposite side, is described as not very rare. In this case, the variant muscle becomes a trigastric. This variation usually happens only on one side (unilaterally). The absence of the anterior belly, the fusion of both anterior bellies, the presence of fibrous intersections in the posterior belly on one or both sides and the presence of an extra anterior belly, which can arise from the anterior belly or from the intermediary tendon, have also been reported (LE DOUBLE, 1987).

Mori (1964) have analysed two hundred sixty-two cadaveres and classified the anterior belly of the digastric muscle in seven morphological types. The occurrence of trigastrics and quadrigastrics, as well as the possibility of the intermediary tendon’s absence has been documented (BERGMAN, AFIFI and MIYAUCHI, 2006). Several authors found during a dissection a left digastric anterior belly composed of three muscle bundles and a right anterior belly of four muscle bundles (FUJIMURA, ONODERA, FENG et al., 2003). These variations were associated with morphological changes in the mylohyoideus muscle. These authors proposed using the muscle insertion as a basis to classify the variations of the digastric muscle. Some studies described a case in which the anterior bellies were composed of two different portions bilaterally (PEKER, TURGUT and ANIL, 2000). These anatomic variations on the anterior belly of the digastric muscle could be significant during surgical procedures involving the submental region (PEKER, TURGUT and ANIL, 2000; FUJIMURA, ONODERA, FENG et al., 2003).

Besides this surgical importance, we suggest that these supranumerary bellies have no direct action on the mandible, but on the floor of the mouth, due to its insertions on the mylohyoid muscle, when it involves chewing and deglutition function.

References

- BERGMAN, RA., AFIFI, AK. and MIYAUCHI, R. *Illustrated encyclopedia of human anatomic variation: opus I: muscular system: alphabetical listing of muscles: varieties of the anterior belly of digastricus*. 2006. Available from: <<http://www.anatomyatlases.org/AnatomicVariants/Images/0015.shtml>>. Access in: 01 June 2015.
- DI DIO, LJA., AMATUZZI, MM. and CRICENTI, SV. *Tratado de anatomia aplicada: sistema muscular*. São Paulo: Póluss Editorial, 1998. 213 p.
- FUJIMURA, A., ONODERA, M., FENG, XY., OSAWA, T., NARA, E., NAGATO, S., MATSUMOTO, Y., SASAKI, N. and NOZAKA, Y. Abnormal anterior belly of the digastric muscle: a proposal for the classification of abnormalities. *Anatomical Science International*, 2003, vol. 78, n. 3, p. 185-188. PMID:14527134. <http://dx.doi.org/10.1046/j.0022-7722.2003.00049.x>.
- GARDNER, E., GRAY, DJ. and O’RAHILLY, R. *Anatomia: estudo regional do corpo humano: região submandibular*. Rio de Janeiro: Guanabara Koogan, 1967. 764 p.

- LE DOUBLE, AF. *Traité des variations du système musculaire de l'homme e leur signification au point de vue di l'anthropologie: muscles du Cou*. Paris: Libraire C. Reinwald, Schleicher Freres, 1987. 516 p.
- MOORE, KL. *Anatomia orientada para a clínica: o peçoço*. Rio de Janeiro: Guanabara Koogan, 1994. 723 p.
- MORI, M. Statistics on the musculature of the Japanese. *Okajimas Folia Anatomica Japonica*, 1964, vol. 40, n. 3, p. 195-300. PMID:14213705. http://dx.doi.org/10.2535/ofaj1936.40.3_195.
- PEKER, T., TURGUT, HB. and ANIL, A. Bilateral anomaly of anterior bellies of digastric muscles. *Surgical and Radiologic Anatomy*, 2000, vol. 22, n. 2, p. 119-121. PMID:10959680. <http://dx.doi.org/10.1007/s00276-000-0119-y>.
- ROUVIÉRE, H. and DELMAS, A. *Anatomía humana descriptiva: topográfica y funcional*. Madrid: Casa Editorial Bailly-Bailliere, 1964. 712 p. Cabeza y cuello, vol. 1.
- TESTUT, L. *Traité d'anatomie humaine: myologie*. Paris: Tome Premier, Gaston Doin & C^{ie}, 1928. 1024 p.

Received October 6, 2015
Accepted November 8, 2016