

An extensive study and review of literature about multiple variations of the lumbar plexus

NAYAK, S. B., SURENDRAN, S. *, REGHUNATHAN, D., MALOOR, P. A. and SHETTY, P.

Department of Anatomy, Melaka Manipal Medical College, Manipal University,
Manipal – 576104, Karnataka, India

*E-mail: anat.sudarshan@gmail.com

Abstract

Introduction: Lumbar plexus involves the L1 – L5 spinal segments for the formation of the nerves which supply parts of the abdominal wall, pelvis and the upper part of the thigh (both sensory and motor). Our aim in this study was to compile all the rare variations found in a single cadaver, which is of the rarest possible kind. **Methods:** During the dissection of the abdomen and pelvis in approximately 70 year old cadaver, there were multiple variations observed in the anatomy of the lumbar plexus. The entire region was cleaned for visibility of the variations and all those were clearly documented for compiling purpose. **Results:** The following variations in the formation of the lumbar and sacral nerves were observed. 1. The genitofemoral nerve bifurcated at a higher level; genital branch of genitofemoral nerve gave branches to the anterior abdominal wall muscles, 2. A communicating branch was given from the lateral cutaneous nerve of thigh to the medial cutaneous nerve of thigh, 3. A muscular branch was given from femoral nerve to psoas major, 4. There was absence of contribution of L4 spinal nerve in the formation of the lumbosacral trunk, and 5. Lumbosacral trunk gave communicating branches to the femoral and obturator nerves. Most of the variations found were rare and finding all the above said variations in a single cadaver is even rare. **Conclusion:** Knowledge of the normal anatomy and any possible variations would help the clinicians and surgeons dealing with this region and avoid possible complications beforehand.

Keywords: lumbosacral trunk, lumbar plexus, femoral nerve, genitofemoral nerve, sacral plexus.

1 Introduction

Lumbar plexus is formed by the union of ventral rami of T12, L1, L2, L3 spinal nerves and the larger upper division of L4 lumbar spinal nerves (URBANOWICZ and ZALUSKA, 1969). There are cases where the cranial or the caudal nerve twigs contribute in the formation of lumbar plexus. The smaller lower division of the fourth lumbar nerve joins with the first sacral nerve to form the lumbosacral trunk and contributes to the formation of sacral plexus.

The ventral rami of the lumbar nerves course laterally and downwards between the planes of the psoas major muscle. The first lumbar nerve gives rise to the ilio-hypogastric and the ilio-inguinal nerves. A branch from the first lumbar nerve joins with a branch from the second lumbar nerve to form the genito-femoral nerve. Then the L2, L3 and L4 nerves divide into ventral and dorsal divisions. The dorsal branches of L2 and L3 join to form the lateral cutaneous nerve of thigh. The dorsal branches of L2, L3 and L4 join to form the femoral nerve whereas the ventral branches join to form the obturator nerve. Occasionally, an accessory obturator nerve (seen in 30% of cases) is given off from L3 and L4 nerves (TUBBS, SHEETZ, SALTER et al., 2003). Being such a complicated formation and difficult to reach within the pelvis, it gains its importance in a clinician's point of view. Lumbar plexus gains its importance in lumbar nerve block.

Lumbar plexus is less common to be injured compared to the brachial plexus, but they do occur in the former and in

such cases the surgeon must be aware of the normal anatomy of this region as well as the probable variations to avoid possible complications. Any lesion to the lumbar plexus is mostly iatrogenic. They could also be a result of trauma during birth (HOPE, BODENSTEINER and THONG, 1985), fibrous or muscular band entrapments (KASHUK, 1977), intrinsic or extrinsic tumors or due to a damage caused by any sharp object penetration or a gunshot. Apart from the above said, any procedure (such as in genitofemoral neuralgia (RHO, LAMER and FULMER, 2001)) done to relieve pain in relation to the branches of lumbar plexus or involvement of the lumbar plexus would also require detailed knowledge of the normal anatomy of the lumbar plexus and the possible variations related to its formation (BENZEL, BAROLAT-ROMANA and LARSON, 1988; BENZEL, 1992).

2 Materials and Methods

The present study involved the cadaveric dissections done at the Department of Anatomy, Melaka Manipal Medical College, Manipal University, Manipal, Karnataka, India. The dissections were carried out according to the guidelines and instructions provided by the Cunningham's Manual of Practical Anatomy (ROMANES, 1977, 1986). During a routine dissection for undergraduate medical students, a variant communication between the lateral cutaneous nerve of the thigh and the medial cutaneous nerve of thigh was observed.

These nerves were reverse traced to their point of origin and we found that there were other nerves from the lumbar plexus which also did not have a normal anatomy. All the nerves in this region were clearly dissected and cleaned for maximum possible naked eye visibility. The psoas major muscle was split for observing the genitofemoral nerve and other nerves related to it. While clearing the psoas major, additional nerves were found to supply it and when traced, they were observed to be given off from the femoral nerve. The lateral cutaneous nerve of the thigh was traced from the front of the

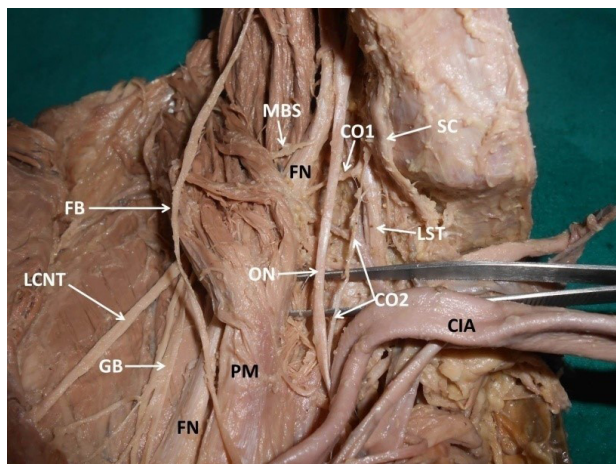


Figure 1. Dissection of the variant branches of right lumbar plexus. Caption: FB – femoral branch of genitofemoral nerve; GB – genital branch of genitofemoral nerve; LCNT – lateral cutaneous nerve of thigh; FN – femoral nerve; ON – obturator nerve; MBS – muscular branch to psoas major muscle; SC – sympathetic chain; LST – lumbosacral trunk; CIA – common iliac artery; PM – psoas major muscle; CO1 – communicating branch between lumbosacral trunk and femoral nerve; CO2 – communicating branch between lumbosacral trunk and obturator nerve.

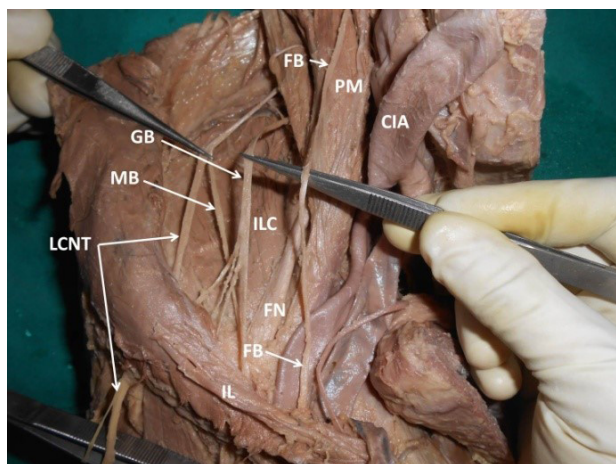


Figure 2. Dissection of the variant branches of right lumbar plexus. Caption: FB – femoral branch of genitofemoral nerve; GB – genital branch of genitofemoral nerve; LCNT – lateral cutaneous nerve of thigh; MB – medial branch of lateral cutaneous nerve of the thigh; FN – femoral nerve; CIA – common iliac artery; PM – psoas major muscle; ILC – iliacus muscle; IL – inguinal ligament.

thigh till its appearance from the lateral border of the psoas major. The femoral nerve and its branches were cleared in the femoral triangle and the trunk was traced back into the pelvis where the communication to it from the lumbosacral trunk was observed. During this, another communicating branch was found to be given off from the lumbosacral trunk which joined the obturator nerve. On tracing the lumbosacral trunk cranially, it was seen that it did not have any contribution from the L4 spinal nerve. The connective tissue, peritoneum and other structures covering the nerves in this region were cleared for the complete view of the various communications and formations of nerves from the lumbar plexus. Thus the combination of this rare case with multiple variations in the communications and combinations was done.

3 Results

Here we present the variations observed during our dissection of the lumbar plexus.

Genitofemoral nerve coursed out from psoas major as genital and femoral branches separately. The femoral branch coursed on the anterior surface of the psoas major and genital branch was on the iliacus muscle. The genital branch, while passing superficial to the iliacus muscle, gave three muscular branches to the flat muscles of anterior abdominal wall.

Lateral cutaneous nerve of thigh gave a medial branch in the iliac fossa. This medial branch passed deep to the inguinal ligament and joined the intermediate cutaneous nerve of the thigh in the thigh, 7 cm below inguinal ligament. Femoral nerve gave a muscular branch to psoas major muscle L4 root did not contribute to the formation of lumbosacral trunk. Lumbosacral trunk was formed only by L5 root alone. Lumbosacral trunk gave two communicating branches; one to femoral nerve and other to obturator nerve. The communicating branch to femoral nerve was very short. But the communicating branch to obturator nerve was long and it joined obturator nerve after a course of about 6 cm.

These above mentioned variations are shown in Figures 1-3.

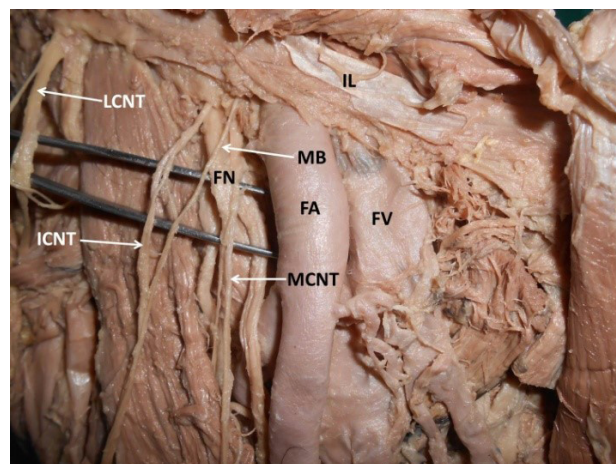


Figure 3. Dissection of the variant branches of right lumbar plexus. Caption: LCNT – lateral cutaneous nerve of thigh; MB – medial branch of lateral cutaneous nerve of the thigh; ICNT – intermediate cutaneous nerve of the thigh; MCNT – medial cutaneous nerve of the thigh; FN – femoral nerve; FA – femoral artery; FV – femoral vein; IL – inguinal ligament.

4 Discussion

Variations in the formation of the nerves are generally developmental unless there is a surgical intervention in their normal anatomy. There are various reports regarding the variations in the formation of nerves from the lumbar plexus, involving one of the nerves from it (MINE ERBIL, ONDEROGLU and BASAR, 1998; ERBIL, ONDEROGLU and BASAR, 1999). During development, the formation of nerves starts as early as 04th week and it is coordinated along with the formation of the muscles, skin and other structures requiring the nerve supply from that segment of the developing spinal cord. The formation of bones, muscles and skin is a part of the somites, which are subdivided into sclerotome, myotome and dermatome with respect to its three derivatives.

Neurectoderm is the portion of the ectoderm of the trilaminar germ disc lying above the notochord in the midline and the entire nervous system develops from the Neurectoderm (LYSER, 1968). The neural precursor cells are the progenitor cells from the neural tube, which give rise to the neuroblasts and finally these differentiate to form the neurons (PURVES, AUGUSTINE, FITZPATRICK et al., 2001). The somites start appearing in the developing embryo as early as 04th week of the embryonic period. The segmentation of the paraxial mesoderm gives rise to a number of somites which are located on either side of the developing neural tube. The sclerotome, myotome and the dermatome are the divisions of the somites and the myotome gives rise to the striated muscle. During this development, one spinal nerve innervates one myotome and those myotomes giving rise to the muscles of the limbs migrate towards the limb bud. During this migration, the spinal nerves extend to the final destination of the muscle developed from the myotome. Thus it is clear that the muscles which receive innervations from multiple spinal segments have developed from more than one myotome. Experimental evidences in birds show that the somites themselves do not possess any predetermined or programmed path for migration, but they respond to positional cues (WACHTLER and CHRIST, 1992). During migration of these myotomes from the either sides of the developing neural tube into the developing limb buds, the myotomes get arranged along the pre-axial and post-axial borders of the limb bud. Within the limb bud, the migration of cells from somites is also affected by growth factor signals from the apical ectodermal ridge of the limb bud field. The final positioning of the migrating myogenic precursors is reported to depend on the surrounding connective tissue around the mass of developing muscle (HAYASHI and OZAWA, 1995). It is also shown that the contact between the medial region of the presumptive limb bud and the somite is also required for the migration of the myogenic cells (HAYASHI and OZAWA, 1995). The migratory path of these precursors for developing muscles is also presumably determined by the acquired receptors on them, which respond to the tissues around in determining their path. There is also a possibility of transcriptional factors like pax-3, which could be located on the lateral part of the somite responsible for acquiring such receptors that assist in migration of these precursors (BIENZ, 1994). There are various studies which have related these migratory paths and the development of muscles in the process of mammalian embryogenesis, in drosophila and also in isolated myoblasts (DONOGHUE, MORRIS-VALERO, JOHNSON et al., 1992;

DONOGHUE, PATTON, SANES et al., 1992; WACHTLER and CHRIST, 1992; BIENZ, 1994).

In our case, the variation is in the formation of the nerves and there are no variations seen with respect to the normal anatomy of the muscles finally formed. This indicates that the variations in the formation of nerves of this region have been due to the variations in the migratory paths of the myotomes towards their destination. The individual myotomes when migrating probably could have taken a different path which could have led to the difference in the course of nerves. The cause for the myotomes taking an unusual course could be linked to various reasons as mentioned earlier.

Variations, such as the ones seen in this case could prove information of particular importance to surgeons and clinicians dealing with this region. The lumbar plexus and its branches do not have a frequent approach in the clinics even though surgery to peripheral nerves is a common procedure in neurosurgery. This infrequent approach to the lumbar plexus is due to its relative inaccessibility and the least frequency with which deep dissections of the pelvic and abdominal cavities are performed by the neurosurgeons. According to Benzel, the lumbosacral plexus and any lesion to the nerves from is a “noman’s-land” and has also referred in relation to it as “unfortunately, an inappropriately conservative approach is often undertaken in patients harboring these lesions because of the suspected degree of difficulty of the surgical approach” (BENZEL, BAROLAT-ROMANA and LARSON, 1988). In procedures such as laparoscopic hernioplasties, any injury to the branches from the lumbar plexus is said to be approximately 2% (ROSENBERGER, LOEWENECK and MEYER, 2000) and there has also been a recent surge in the use of approaches using endoscopes to retroperitoneal regions in treatments related to various spinal disorders (MORO, KIKUCHI, KONNO et al., 2003). In a condition dealing with approach to the lumbosacral plexus, a lateral-extracavitary approach (BENZEL, 1989), a pelvic brim-extraperitoneal approach (LEE and KIM, 2013), an anterolateral-extraperitoneal approach (LEE and KIM, 2013), a transperitoneal approach (MOONEY and GOODMAN, 1969) or a Pfannenstiel infraperitoneal approach (ABERNATHEY, ONOFRIO, SCHEITHAUER et al., 1986; DOMINGUEZ, LOBATO, RAMOS et al., 1997) may be performed. The lower branches such as the femoral nerve could be accessed by the Pfannenstiel infraperitoneal approach whereas the requirement of a wide exposure for this region for lumbar plexus could be achieved by transperitoneal approach, especially in cases of tumors having a neural origin (BENZEL, 1992).

In a literature search related to the above mentioned variations, most of the variations were reported (MEHLER, FISCHER and ALEXANDER, 1952; KIHARA, SATO, ANDO et al., 1991; RAGETH, SAURENMANN and WAESPE, 2000) but we could not come across any report of all of the above variations to be found together. Based on the above reports from the literature, our case is seen as a possible change in course of migration of multiple myotomes to their destination.

The genitofemoral nerve has the root value of L1 and L2 spinal segments, where the genital branch is from L2 segment of the spinal cord and only this nerve is seen to be off the normal course. The dermatome segment from L1 supplied by the femoral branch of the same nerve was seen to have followed the normal course. The genital branch of the genitofemoral nerve supplies the cremaster muscle, a derivative of the internal oblique muscle of the anterior abdominal wall. This could also

possibly be the reason for the existence of the branches from the genital branch to the anterior abdominal wall muscles as the internal oblique muscle of the abdomen is supplied by the lower six thoracic nerves and the first lumbar nerve.

The lateral cutaneous nerve of thigh has contribution from the L2 and L3 spinal segments. The communication between the lateral cutaneous nerve of thigh and the medial cutaneous nerve of thigh could be explained by the fact that some of the fibres of the area supplied by the medial cutaneous nerve of thigh passed through the LCNT before joining their original course through the MCNT.

The other major variation found in the present case was the presence of nerves supplying the psoas major muscle from the femoral nerve. This could be the nerves instead of arising from the L2, 3, 4 segments, joined with the femoral nerve formation and then came out of it as the root values for the nerve to psoas major and the femoral nerve are the same.

The variation found in the formation of the lumbosacral trunk was that there was no contribution from the L4 segment in its formation. The lower division from the L4 spinal nerve joins with the L5 nerve to form the lumbosacral trunk, which was not seen in the present case. The L4 fibres contribute to the formation of the superior gluteal nerve (L4, L5, S1) and the nerve to quadratus femoris (L4, L5) which course to the gluteal region where the gluteus medius and minimus are supplied by the former and the quadratus femoris by the latter. In the current case, these muscles were possibly supplied by only L5 and S1 segments of the spinal cord.

The final variation observed was the communication between the lumbosacral trunk (without contribution from L4) was seen to give communicating branches to the femoral and the obturator nerves. The branch to femoral was short and that to the obturator nerve was longer. Probably the fibres involved in the formation of the femoral and the obturator nerves (both having the same spinal segments in their formation which are L2, 3, 4) could have got some of the fibres through lumbosacral trunk. But in the present case, there was no contribution of L4 in the formation of lumbosacral trunk. **This appears to be a mystery.**

Variations in the normal anatomy of the lumbar and sacral plexus might be seen in some cases and are reported in the literature, but finding such an unusual case comprising of multiple variations which is normally not expected in a clinical setup, proves to be a vital piece of information for clinicians and medical practitioners. Single nerve variations in the lumbar plexus formation have been reported (JAMIESON, 1903; WEBBER, 1961; MORIKAWA, 1971; ANLOAGUE and HUIJBREGTS, 2009; YASAR, KAYA, TEMIZ et al., 2014) to be of rare occurrence and having multiple variations such as the one presented here is one of the rarest and adds up a prime level of knowledge on the possibilities of variations which could be seen in this region.

5 Conclusion

Documentation of such rare cases with multiple variations in the formation of nerves from the lumbar plexus provides vital information on such occurrences. This would in turn improve the knowledge of clinicians and surgeons dealing with this region. Emphasizing such knowledge of this region would prevent accidental damage to the structures with a variant anatomy.

References

- ABERNATHEY, CD., ONOFRIO, BM., SCHEITHAUER, B., PAIROLERO, PC. and SHIVES, TC. Surgical management of giant sacral schwannomas. *Journal of Neurosurgery*, 1986, vol. 65, n. 3, p. 286-295. PMID:3734878.
- ANLOAGUE, PA. and HUIJBREGTS, P. Anatomical variations of the lumbar plexus: a descriptive anatomy study with proposed clinical implications. *The Journal of Manual & Manipulative Therapy*, 2009, vol. 17, n. 4, p. e107-e114. PMID:20140146.
- BENZEL, EC. The lateral extracavitary approach to the spine using the three-quarter prone position. *Journal of Neurosurgery*, 1989, vol. 71, n. 6, p. 837-841. PMID:2585074.
- BENZEL, EC. *Practical approaches to peripheral nerve surgery*. Park Ridge: American Association of Neurological Surgeons, 1992.
- BENZEL, EC., BAROLAT-ROMANA, G. and LARSON, SJ. Femoral obturator and sciatic neurectomy with iliacus and psoas muscle section for spasticity following spinal cord injury. *Spine*, 1988, vol. 13, n. 8, p. 905-908. PMID:3187713.
- BIENZ, M. Homeotic genes and positional signalling in the Drosophila viscera. *Trends in Genetics*, 1994, vol. 10, n. 1, p. 22-26. PMID:7908470.
- DOMINGUEZ, J., LOBATO, R., RAMOS, A., RIVAS, J., GÓMEZ, P. and CASTRO, S. Giant intrasacral schwannomas: report of six cases. *Acta Neurochirurgica*, 1997, vol. 139, n. 10, p. 954-959. PMID:9401656.
- DONOGHUE, MJ., MORRIS-VALERO, R., JOHNSON, YR., MERLIE, JP. and SANES, JR. Mammalian muscle cells bear a cell-autonomous, heritable memory of their rostrocaudal position. *Cell*, 1992, vol. 69, n. 1, p. 67-77. PMID:1555243.
- DONOGHUE, MJ., PATTON, BL., SANES, JR. and MERLIE, JP. An axial gradient of transgene methylation in murine skeletal muscle: genomic imprint of rostrocaudal position. *Development*, 1992, vol. 116, n. 4, p. 1101-1112. PMID:1295732.
- ERBIL, KM., ONDEROGLU, S. and BASAR, R. Unusual branching in lumbar plexus: case report. *Okajimas Folia Anatomica Japonica*, 1999, vol. 76, n. 1, p. 55-59. PMID:10409846.
- HAYASHI, K. and OZAWA, E. Myogenic cell migration from somites is induced by tissue contact with medial region of the presumptive limb mesoderm in chick embryos. *Development*, 1995, vol. 121, n. 3, p. 661-669. PMID:7720574.
- HOPE, EE., BODENSTEINER, JB. and THONG, N. Neonatal lumbar plexus injury. *Archives of Neurology*, 1985, vol. 42, n. 1, p. 94-95. PMID:4038449.
- JAMIESON, EB. Some anomalies in nerves arising from the lumbar plexus, and a bilaminar musculus pectineus in a foetus; and on variations in nerve supply in man and some other mammals. *Journal of Anatomy and Physiology*, 1903, vol. 37, n. 3, p. 266-286. PMID:17232559.
- KASHUK, K. Proximal peripheral nerve entrapment syndromes in the lower extremity. *Journal of the American Podiatry Association*, 1977, vol. 67, n. 8, p. 529-544. PMID:893955.
- KIHARA, K., SATO, K., ANDO, M., SATO, T. and OSHIMA, H. Lumbosacral sympathetic trunk as a compensatory pathway for seminal emission after bilateral hypogastric nerve transections in the dog. *The Journal of Urology*, 1991, vol. 145, n. 3, p. 640-643. PMID:1997722.
- LEE, S. and KIM, D. H. *Surgical approaches to the lumbosacral spine*. 2013. Lumbosacral and Pelvic Procedures, vol. 21.
- LYSER, KM. Early differentiation of motor neuroblasts in the chick embryo as studied by electron microscopy: II. Microtubules and neurofilaments. *Developmental Biology*, 1968, vol. 17, n. 2, p. 117-142. PMID:5637101.

- MEHLER, WR., FISCHER, JC. and ALEXANDER, WF. The anatomy and variations of the lumbosacral sympathetic trunk in the dog. *The Anatomical Record*, 1952, vol. 113, n. 4, p. 421-435. PMID:14943971.
- MINE ERBIL, K., ONDEROGLU, S. and BASAR, R. Unusual branching in lumbar plexus: case report. *Folia Morphologica*, 1998, vol. 57, n. 4, p. 377-381. PMID:10437316.
- MOONEY, V. and GOODMAN, F. Surgical approaches to lower-extremity disability secondary to strokes. *Clinical Orthopaedics and Related Research*, 1969, vol. 63, p. 142-152. PMID:5769370.
- MORIKAWA, R. Distribution and variations of the nerves deriving from the lumbar plexus and supplying the abdominal wall. *Kaibogaku Zasshi*, 1971, vol. 46, n. 5, p. 312-338. PMID:4260167.
- MORO, T., KIKUCHI, S., KONNO, S. and YAGINUMA, H. An anatomic study of the lumbar plexus with respect to retroperitoneal endoscopic surgery. *Spine*, 2003, vol. 28, n. 5, p. 423-428. PMID:12616150.
- PURVES, D., AUGUSTINE, G. J., FITZPATRICK, D., KATZ, L. C., LAMANTIA, A.-S., MCNAMARA, J. O. and WILLIAMS, S. M. *The initial formation of the nervous system: gastrulation and neurulation*. 2001.
- RAGETH, JC., SAURENMANN, E. and WAESPE, W. Postpartum footdrop due to compression of the lumbosacral trunk. *Gynakologisch-Geburtsbifflche Rundschau*, 2000, vol. 40, n. 2, p. 68-70. PMID:10971088.
- RHO, RH., LAMER, TJ. and FULMER, JT. Treatment of genitofemoral neuralgia after laparoscopic inguinal herniorrhaphy with fluoroscopically guided tack injection. *Pain Medicine*, 2001, vol. 2, n. 3, p. 230-233. PMID:15102257.
- ROMANES, G. *Cunningham's manual of practical anatomy*. Oxford: Oxford University Press, 1986. Upper and Lower Limbs, vol. 1.
- ROMANES, GJ. *Cunningham's manual of practical anatomy*. Oxford: Oxford University Press, 1977. Thorax and Abdomen, vol. 2.
- ROSENBERGER, RJ., LOEWENECK, H. and MEYER, G. The cutaneous nerves encountered during laparoscopic repair of inguinal hernia: new anatomical findings for the surgeon. *Surgical Endoscopy*, 2000, vol. 14, n. 8, p. 731-735. PMID:10954819.
- TUBBS, RS., SHEETZ, J., SALTER, G. and OAKES, WJ. Accessory obturator nerves with bilateral pseudoganglia in man. *Annals of Anatomy*, 2003, vol. 185, n. 6, p. 571-572. PMID:14704003.
- URBANOWICZ, Z. and ZALUSKA, S. Formation of the lumbar plexus in man and macaca. *Folia Morphologica*, 1969, vol. 28, p. 256-271.
- WACHTLER, F. and CHRIST, B. The basic embryology of skeletal muscle formation in vertebrates: the avian model. *Seminars in Developmental Biology*, 1992, vol. 3, p. 217-227.
- WEBBER, RH. Some variations in the lumbar plexus of nerves in man. *Acta Anatomica*, 1961, vol. 44, p. 336-345. PMID:13783591.
- YASAR, S., KAYA, S., TEMIZ, C., TEHLI, O., KURAL, C. and IZCI, Y. Morphological structure and variations of lumbar plexus in human fetuses. *Clinical Anatomy*, 2014, vol. 27, n. 3, p. 383-388. PMID:22696243.

Received February 8, 2016
Accepted April 17, 2017