

# A report on the accessory head of Flexor Pollicis Longus and Variations of Forearm Musculature

HAFEZ, S. A.<sup>1,2,3\*</sup>

<sup>1</sup>Department of Biomedical Sciences, Virginia Tech Carilion School of Medicine and Research Institute, Roanoke, VA, 24016, USA

<sup>2</sup>Department of Biomedical Sciences and Pathobiology, Virginia-Maryland College of Veterinary Medicine, Virginia Polytechnic Institute and State University, Blacksburg, VA, 24061, USA

<sup>3</sup>Department of Anatomy and Embryology, College of Veterinary Medicine, Alexandria University, Egypt

\*E-mail: shafez@vt.edu

## Abstract

**Introduction:** Gantzer's muscle has drawn attention from several authors owing to the possibility of interosseous nerve compression. This is a report of an accessory head of flexor pollicis longus (FPL, a variant of Gantzer's muscle) and a review of the variations of all muscles of the forearm. **Materials and Methods:** An accessory head of FPL was discovered in both the right and left antebrachial regions during a cadaver dissection. The muscle was dissected and photographed. **Results:** The anatomical variation I report is a slender conical muscle joining the FPL. Its origin merged with fibers of the flexor digitorum superficialis. It inserted into the upper part of the middle third of the forearm by joining the medial tendinous part of the FPL; this join was by means of a short cylindrical tendon. The reported muscle was innervated by the anterior interosseous nerve, which was seen to be present posterolateral to the muscle in both forearms. **Conclusion:** The described muscle might cause pressure problems to the underlying structures especially the anterior interosseous nerve. Variations must be considered during surgical intervention to avoid unintentional damage to healthy tendons. In addition, accessory tendons can potentially be useful in the repair or replacement of damaged tendons through surgical transfer or transplantation. Variations of muscles, especially accessory muscles, may mimic the behavior of soft tissue tumors and can result in nerve compressions. This collection of variations of the forearm musculature will be useful to surgeons in practice as well as students in dissection labs.

**Keywords:** Gantzer's muscle, flexor pollicis longus, accessory head of FPL, forearm musculature variations, anatomical variations.

## 1 Introduction

Two accessory heads were initially named after Gantzer in his 1813 dissertation on anatomical variations (translated by KAPLAN, 1969) (MACALISTER, 1875; WOOD, 1868). These heads originate more frequently from the medial epicondyle of the humerus and join the FPL (thus forming an accessory head of the FPL); less frequently they arise from the medial epicondyle of the humerus and join the flexor digitorum profundus (FDP) (creating an accessory head of the FDP). Further studies of these accessory heads by several authors (AL-QATTAN, 1996; DELLON and MACKINNON, 1987; EID and OTSUKI, 2009) documented their origin from the medial epicondyle of the humerus, the coronoid process of the ulna, or both.

An accessory muscle reported by Vollala, Nagabhooshana, Bhat et al. (2008) originated from the undersurface of the flexor digitorum superficialis distal to that muscle's origin from the medial epicondyle of humerus. The accessory muscle belly ended in a long tendon in the middle part of the forearm, which merged with the tendon of the FDP. Jones, Abrahams and Sañudo (1997) reported an accessory head that inserted on both the abductor pollicis longus and FDP. Eid and Otsuki (2009) reported the presence of a pair of Gantzer's muscle. One of these was larger, more voluminous in shape, and originated from the medial epicondyle of the humerus, inserting

into the ulnar side of the FPL at the junction between the proximal and middle thirds of forearm. The second superficial accessory muscle was smaller and fusiform in shape and arose from the undersurface of the FDS muscle. It terminated distally into the FPL.

Gantzer's muscle has drawn attention from several authors owing to the possibility of interosseous nerve compression. In this report I describe an accessory head of the FPL.

The flexors and pronators of the forearm occupy the anterior compartment. All of them are served by the median nerve except the flexor carpi ulnaris and the medial half of the flexor digitorum profundus which are served by the ulnar nerve. The extensors and supinators of the forearm occupy the posterior compartment. They all are innervated directly or indirectly by the radial nerve (MOORE, DALLEY and AGUR, 2014).

The superficial layer of the anterior compartment of the forearm includes the pronator teres (PT), flexor carpi radialis (FCR), palmaris longus (PL), and flexor carpi ulnaris (FCU) which share a common flexor attachment on the medial epicondyle of the humerus. The intermediate layer consists of the flexor digitorum superficialis (FDS). The deep layer includes the flexor digitorum profundus (FDP), flexor pollicis longus (FPL), and pronator quadratus (PQ) which are innervated by

the anterior interosseous nerve; with the exception of the medial part of the FDP (MOORE, DALLEY and AGUR, 2014).

The superficial layer of the extensors of the forearm includes the brachioradialis (BR), extensor carpi radialis longus (ECRL), extensor carpi radialis brevis (ECRB), extensor digitorum communis (EDC), extensor digiti minimi (EDM), extensor carpi ulnaris (ECU). The deep layer includes the supinator (SP), extensor indicis (EI), abductor pollicis longus (APL), extensor pollicis longus (EPL), and extensor pollicis brevis (EPB) (MOORE, DALLEY and AGUR, 2014).

Many of the variations in forearm musculature have been either individually reported or described in combination in older publications. The aim of this report is to review both individual and combined reports arranging them topographically for easier review before surgery is attempted on the forearm. This report can also be simply used in human anatomy dissection labs to alleviate confusion due to the presence of an unreported muscle, or lack of a head of a certain muscle.

## 2 Materials and Methods

An anomalous muscle was observed during routine dissection of an 81-year-old man in the course of first-year medical school instruction in the anatomy laboratory of the Virginia Tech Carilion School of Medicine. A more meticulous dissection of the muscle was performed on both forearms and photographs were taken.

## 3 Results

### 3.1 Case report

I report the presence of a slender conical muscle joining the FPL in both the right and left forearms. The FPL is one of the deep flexors of the forearm, originating from the anterior surface of radius and the adjacent interosseous membrane, and inserting onto the base of the distal phalanx of thumb.

The cadaver had a typical textbook architecture of the superficial layer of the anterior (flexor-pronator) compartment (Figure 1) in both forearms. However, upon deeper dissection, a slender elongated cone-shaped muscle was seen joining the FPL (Figure 2). Its origin was merged with fibers of the FDS. It inserted into the upper part of the middle third of the forearm by joining the medial tendinous part of the FPL via a short cylindrical tendon. The muscle was relatively fatter in the right forearm.

The muscle was innervated by the anterior interosseous nerve. This nerve was present posterolateral to the muscle in both forearms (Figure 3).

### 3.2 Review of variations of forearm musculature

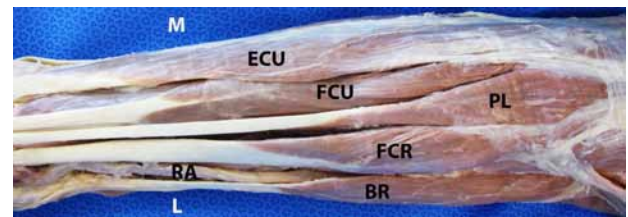
There are countless reports on the anatomical variations of the forearm musculature. The following is a review, to the best of this author's knowledge, of the variations that have been reported in the literature. The review is organized topographically whenever possible.

#### 3.2.1 Variations of the posterior compartment

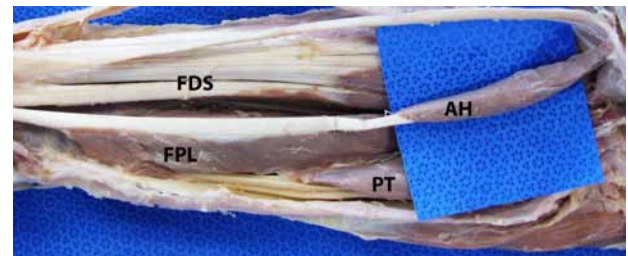
Rodriguez-Niedenfuhr, Vazquez, Parkin et al. (2001) studied the incidence and morphology of the brachioradialis accessorius. That muscle was reported as a rare incident present in 2.8% of the cadavers that were studied. It originated proximal to the origin of the BR, or from the humeral condylar ridge distally

to the lower border of the origin of the BR. Less frequently, it originated as part of the BR muscle proper. A double origin combining a high one from below the deltoid and one from the condylar ridge has also been reported. Distal to its origin the muscle was shown to run medially and distally towards its insertion, which was most frequently into the radial tuberosity together with the biceps brachii tendon; less frequently it inserted into the anterior surface of the radius, or into the PT tendon. Occasionally, combined insertions were observed by authors (RODRIGUEZ-NIEDENFUHR, VAZQUEZ, PARKIN et al., 2001); sometimes it was seen to insert partially into the radius and partially into the SP, PT, or radial notch of the ulna.

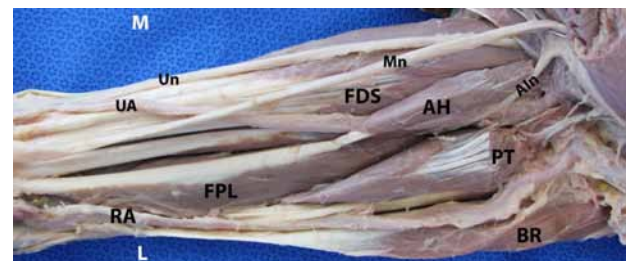
A case of compression of the superficial radial nerve at the elbow was reported due to a brachioradialis accessorius muscle entrapment (SPINNER and SPINNER, 1996). The muscle



**Figure 1.** Anterior view of the forearm showing typical textbook topography of the superficial muscles. ECU, extensor carpi ulnaris; FCU, flexor carpi ulnaris; PL, palmaris longus; FCR, flexor carpi radialis; BR, brachioradialis; RA, radial artery; M, indicates medial; L, indicates lateral.



**Figure 2.** Deep dissection of the forearm musculature. The flexor digitorum superficialis (FDS) is reflected medially. The accessory head (AH) of flexor pollicis longus (FPL) is showing joining the Medial tendinous part of the FPL. PT, pronator teres.



**Figure 3.** Deep dissection of the forearm. The flexor digitorum superficialis (FDS) is reflected medially. The anterior interosseous nerve (AIIn) which is a branch of the median nerve (Mn) runs posterolateral to the accessory head (AH) of the flexor pollicis longus (FPL). BR, brachioradialis; PT, pronator teres; RA, radial artery; UA, ulnar artery; Un, ulnar nerve; M, indicates medial; L, indicates lateral.

in question arose from the distal humerus on the lateral supracondylar ridge adjacent to the BR origin and inserted into the radial tuberosity. The radial nerve was compressed in the interval between BR and brachioradialis accessorius.

Nair, Nair, Mookambika et al. (2012) reported additional anomalous fleshy fibers seen at the origin of BR in addition to its normal origin from the upper part of the lateral supracondylar ridge of the humerus. These fibers were attached proximally to the middle part of the shaft of the humerus, close to the insertion of the deltoid. Some of the fibers continued further up to the acromion process of the scapula. These fibers passed downwards along with those of the deltoid and joined the fibers from the humerus before merging with the BR distally. Authors compared these additional muscle fibers with the brachioradialis accessorius and based on that they did not consider the reported fibers to be a variety of an accessory brachioradialis. These authors discussed the uniqueness, functional significance, and the clinical relevance of this variation. The reported accessory muscles crossed both the shoulder and elbow joints; their fibers could stabilize the shoulder joints during abduction of the arm and/or may help to maintain it in an abducted position of the arm. They may also assist in flexion of the supinated forearm. A potential radial nerve compression could be created by these anomalous muscle fibers and the biceps brachii. The authors recommended that these fibers should be considered during tendon transfer surgery (NAIR, NAIR, MOOKAMBIKA et al., 2012).

The extensor carpi radialis longus and brevis may also have their share of variations. Hong and Hong (2005) found two accessory muscles in the lateral compartment of the forearm of a 92-year old female cadaver. One of these originated from the ECRB, became tendinous and travelled between the two radial extensor tendons. It inserted independently into the second metacarpal bone, and they regarded it as an extensor carpi radialis intermedius. An extensor carpi radialis intermedius was present in some cases, as documented by Albright and Linburg (1978); it arose proximally from the ECRL and inserted distally with the ECRB. Another accessory muscle reported by Hong and Hong (2005) originated from the ECRL, passed superficially over the parent tendon and inserted into the abductor pollicis brevis. This variation appeared to be different from extensor carpi radialis accessorius reported by Claassen and Wree (2002). The reported accessory muscle originated from the ECRL and inserted onto the first metacarpal bone. Its tendon passed through a specific dorsal tunnel under the extensor retinaculum. These authors also reported an accessory tendon lying underneath the main tendon of the extensor carpi radialis muscle. The accessory tendon joined with the main tendon just as it crossed under the APL and EPB. Afterwards the tendon lay in the second tunnel of the extensor retinaculum and inserted in the base of the third metacarpal.

Additional radial wrist extensor tendons that were reported by Nayak, Madhan Kumar, Krishnamurthy et al. (2007) originated either from the ECRL or ECRB muscles and were inserted at the base of the 2nd or 3rd metacarpal bone.

Pinar, Govsa, Bilge et al. (2012) reported accessory slips arising from the extensor carpi ulnaris muscle. These slips ran to the ulnar side of the EDM tendon. The mean width of the tendinous slips was  $1.4 \pm 0.01$  mm.

Anatomical variations of the finger extensor tendons are not uncommon and have been described by several authors

(ABDEL-HAMID, EL-BESHBISHY and ABDEL AAL, 2013; BETTENCOURT PIRES, CASAL, MASCARENHAS DE LEMOS et al., 2013; BLUTH, WU, ELENA STARK et al., 2011; CASANOVA MARTINEZ, VALDIVIA GANDUR and GOLANO, 2013; CASANOVA-MARTINEZ, VALDIVIA-GANDUR and GOLANO, 2014; AVDAR and SEHIRLI, 1996; LI and MAO, 2014; MEHTA et al., 2009; NAYAK, HUSSEIN, KRISHNAMURTHY et al., 2009; NAYAK, KRISHNAMURTHY, PAI et al., 2008; NAYAR and MCARTHUR, 2009; RAY, RANADE, D'COSTA et al., 2010; ROY, MEHTA, SURI et al., 2010; YAMMINE, 2014, 2015; ZAINO, MITGANG, RAWAT et al., 2014). Some of these studies included anatomical variations of the first dorsal compartment of the wrist in relation to their importance in de Quervain's disease (NAYAK, HUSSEIN, KRISHNAMURTHY et al., 2009; ROY, ROY, DE et al., 2012; ROY, MEHTA, SURI et al., 2010). Variations in the fingers extensor tendons are of paramount importance for the reconstructive surgeons, who may utilize these accessory slips to restore functional capacity of the fingers. Some representative variations are described below.

Abdel-Hamid, El-Beshbishy and Abdel Aal (2013) reported variations of the hand extensors. The EPL and EPB tendons were found to be single, doubled or, rarely, absent. Their insertion could be traced to either the proximal phalanx, or through the extensor expansion to both phalanges; or, rarely, to the distal phalanx of the thumb. The EI had a single tendon in all specimens. In the majority of specimens, the extensor digitorum had no independent slip to the little finger; it gave off a single tendon to the index finger, double tendons to the middle finger and triple tendons to the ring finger. The EDM muscle often had double or triple tendons distal to the extensor retinaculum.

Multiple variations of the extensor tendons were reported by Nayak, Krishnamurthy, Pai et al. (2008). The variants included the complete absence of the EPB, and the APL having six slips of insertion with an additional muscle slip from the BR. The EDC had five tendon slips; the extra tendon split close to the metacarpo-phalangeal joint and contributed to the tendons of the ring and little fingers. The number of accessory tendons of the APL has functional significance in the development of de Quervain's stenosing tendovaginitis. All three variations were present in the ipsilateral upper limb.

Zaino, Mitgang, Rawat et al. (2014) reported that the APL and EPB tendons were flanked by anomalous muscles within an inflamed sheath in an elderly patient.

Roy, Roy, De et al. (2012) reported an anomaly consisting of a bitendinous insertion of the APL on the base of the first metacarpal, complemented by an additional muscle belly arising from the fascia covering the ECRL. They suggested that this could provide an additional support to the first carpo-metacarpal joint and act as an effective aid in tendon transfers and reconstructive procedures of the hand. In contrast, these tendons can pose as surgical hazards in post-operative cases of De Quervain's disease.

Casanova Martinez, Valdivia Gandur and Golano (2013) described finding an accessory tendon located between the EDC muscle tendon, destined for the index finger, and the EPL tendon. A fascial connection was observed between the radial portion of the accessory tendon and the ulnar portion of the EPL tendon. This corresponds anatomically to the supernumerary muscle denominated extensor indicis radialis,



but due to the fascial connections observed with the EPL, the reported muscle would behave functionally as a supernumerary muscle denominated by the authors as extensor pollicis et indicis communis.

Later, the same authors (CASANOVA MARTINEZ, VALDIVIA GANDUR and GOLANO, 2014) found an extensor pollicis et indicis communis with three slips in a cadaver: two toward the index finger and one toward the thumb. Additionally, they found an extensor indicis radialis in the left wrist. In both hands, the course of accessory slips was modified by fibers derived from intertendinous fascia.

Mehta, Jyoti, Suri et al. (2009) reported an accessory muscle arising from the origin of the EDC, passing to the index finger; this was in addition to the usual EI. Later, Yammine (2015) reviewed the prevalence of the EI and its variants.

Avdar and Sehirli (1996) reported an accessory tendon of the EI muscle in between the EI and EPL muscles. The accessory muscle's tendon passed under the extensor retinaculum. At the level of the 2nd metacarpal bone, the accessory extensor indicis tendon was connected to the tendon of the EPL muscle by an intertendinous connection. In addition, Nayar and McArthur (2009) reported an anomalous, independent tendon to the thumb, which was accompanied by an accessory supernumerary tendon to the EI.

The EDM tendon is frequently used in the case of an abduction deformity of the little finger. Its variations were reported by Yammine (2014). Li and Mao (2014) reported an EDM with five slips on the right hand. Except for the two slips of the little finger, the two radial slips were inserted into the dorsal aponeurosis of the middle finger and the ring finger, respectively. The middle slip was connected to the junctura tendinum in the fourth intermetacarpal spaces. Bettencourt Pires, Casal, Mascarenhas de Lemos et al. (2013) identified a thick bundle of muscular fibers, connecting the main muscular shafts of the EDM, and the EDC Muscles, in a defined muscular expansion, bridging obliquely downwards and outwards, between the two main muscular shafts.

Bluth, Wu, Elena Stark et al. (2011) described a variant of the extensor pollicis tertius muscle that had its origin at the proximal end of the EI muscle and inserted on the tendon of the EPL at the proximal shaft of the proximal phalanx of the thumb.

### 3.2.2 Variations of the anterior compartment

#### 3.2.2.1 Palmaris longus

The palmaris longus is known to exhibit the most frequent anatomical variations compared to the other muscles in the upper limb (PARK, NAMDARI and YAO, 2010). Complete agenesis is the most frequent variation, but a number of other variations have been reported. These include reversed, duplicated, bifid, or hypertrophied PL muscles. Variation in the location, form of the fleshy portion, aberrancy in attachment, and accessory tendinous slips, replacing elements of similar form or position have also been reported (NATSIS, DIDAGELOS, MANOLI et al., 2012). Park, Namdari and Yao (2010) consolidated many reports of the anatomic variations of the PL muscle and its clinical relevance. Different variations of the PL may be useful to the hand surgeon as a tendon graft, a tendon for transfer, or as an anatomical landmark for operations at this area (SALGADO, CANTIN, INZUNZA et al., 2012).

Most standard textbooks of hand surgery quote the absence of a PL at around 15%. However, a study and literature

review of by Sebastin, Puhaindran, Lim et al. (2005) revealed a low level of absence in Asian, Black and Native American populations and a much higher prevalence of absence in Caucasian populations. In Chinese it is absent unilaterally in 3.3%, and bilaterally in 1.2%, with an overall prevalence of absence of 4.6%. Yammine (2013) reported significantly lower pooled rates in Africans (11.3%) and East Asians (4.5%) when compared to Arab Middle Eastern population (41.7%) and Egyptians (50%) (RAOUF, KADER, JARADAT et al., 2013). A subgroup analysis of the African group showed a pooled rate of 2.71%, the lowest, in the East and South East African population. The pooled rate was 26.3% among Caucasians, 26.16% among South and Southeast Asians and 34.13% among Turkish. PL agenesis was statistically more common on the right side (YAMMINE, 2013).

Kawashima, Kikushima, Yokota et al. (2002) reported a duplicate PL muscle with an accessory PL muscle on the right side of a cadaver. On the left forearm, a case of double PL was reported by Ari, Sendemir, Kurt et al. (1997). Takanashi, Eda, Kaidoh et al. (2012) reported duplicate PL muscles in the bilateral forearms together with the palmaris profundus muscle in the right forearm. The aberrant bilateral PL muscles were observed at the ulnar side of the PL muscle and their distal tendons were attached to the flexor retinaculum. The palmaris profundus muscle found in the right forearm was located at the radial side of the FDS muscle. The proximal tendon originated from the anterior surface in the middle of the radius, while the distal tendon coursed radial to the median nerve through the carpal tunnel, finally inserting into the distal part of the flexor retinaculum.

Reversal of the PL is seen when it is tendinous proximally and muscular distally. Murabit, Gnarra and Mohamed (2013) reported a case of a reversed PL and provided a literature review of variations in the PL. A three-headed reserved PL was reported by Natsis, Levva, Totlis et al. (2007) whereas the lower muscular part of PL was triple. A case of bilateral reversed PL muscle was reported by Salgado, Cantin, Inzunza et al. (2012). The muscle was tendinous in its upper portion and muscular in its lower portion in both arms. A reversed PL muscle may cause a compartment syndrome in the wrist area, carpal tunnel, and Guyon's syndrome (SALGADO, CANTIN, INZUNZA et al., 2012).

A fleshy PL arising from the common tendon for the antebrachium flexor muscles was reported by Durgun, Celik, Atasever et al. (1993). It was divided into a lateral and a medial tendon. The lateral tendon of the muscle was inserted onto the thenar fascia and the scaphoid bone while the medial tendon was inserted onto the hypothenar fascia and the triquetral bone. Another totally fleshy PL without a long insertion tendon was described by Natsis, Didagelos, Manoli et al. (2012) on the right side in a 63-year-old man. The belly was rather broad and long, fusiform at the upper half and unipennate at the lower half of the forearm, and it was toggled into a short and thick tendon. At its insertion the tendon was split forming a second thinner tendon. The thick tendon was inserted into the flexor retinaculum and the thinner one into the palmar aponeurosis. A hypertrophied PL was also reported by Polesuk and Helms (1998) with a warning that this could be mistaken for a tumor during magnetic resonance imaging.

An accessory palmaris muscle detected in a patient during surgery was reported by Raouf, Kader, Jaradat et al. (2013). The muscle arose from the base of the fifth metacarpal passed

proximally and inserted into the PL tendon. In its course it compressed the ulnar nerve and vessels. When it was detached proximally and folded on itself to provide hypothenar bulk, the entrapment symptoms were relieved.

A case of a bilateral palmaris profundus associated with bilateral PL causing bilateral carpal tunnel syndrome was described by Floyd, Burger and Sciaroni (1990).

### 3.2.2.2 Other muscles of the anterior compartment

Nebot-Cegarra, Perez-Berrueto and Reina de la Torre (1991) studied the variability of the PT muscle in 60 upper limbs. The humeral head was present in all cases and was double in 3 cases (5.0%). The ulnar head was present in 47 cases (78.3%). The ulnar head was muscular in 11 cases, tendinous in 6 cases, and mixed in 30 cases. Special reference was made to the influence of variations in the PT muscle on the compression or the entrapment of the median nerve (pronator syndrome).

Jelev and Georgiev (2009) reported an unusual high-origin of the PT muscle. The fibers of the aberrant muscle arose from the medial epicondyle and the supracondylar ridge of the humerus, and from a tendinous arch (Struthers' ligament) extending between them. In addition, there was a variation of the musculocutaneous nerve: in the axillary fossa the musculocutaneous was fused to the median nerve and its usual branches arose consecutively from the median nerve stem. In this case the entrapment of the lateral antebrachial cutaneous nerve by the Struthers' ligament is possible.

Anomalies of the FCU were reported and reviewed by Bhardwaj, Bhandari and Sabapathy (2013). Digastric FCU was reported by Bhardwaj, Bhandari and Sabapathy (2013). It is characterized by the presence of two separate bellies of the FCU muscle with separate tendons. The muscle was found incidentally in a patient operated on for complex Post Volkmann's ischemic contracture deficits. In this case one tendon was used for the thumb opposition while the other for index finger flexion. Postoperatively, the patient had independent movement of thumb and index finger. The authors (BHARDWAJ, BHANDARI and SABAPATHY, 2013) reviewed the literature for supernumerary FCU in general and digastric FCU in particular, and proposed a classification for supernumerary FCU muscle based on the clinical appearance and the probable embryological basis of the anomaly: Type 1 (Split tendons) — single muscle with two tendons; Type 2 (Digastric FCU) — for each head of FCU forming separate muscle bellies and tendons; and Type 3 (Accessory FCU) — abnormal muscle adjacent to normal FCU with combined features of FCU and PL.

An accessory FCU was reported by Ang, Rozen, Vally et al. (2010). The reported muscle was seen running superficial to the ulnar nerve and radial to the FCU proper, arising from the common flexor origin and inserting at the triquetral carpal bone. This was therefore suitably acknowledged as an "accessory FCU". The anomaly was identified as bilateral using ultrasound imaging, and was found to be anomalously innervated by the median nerve with nerve conduction studies. A subsequent review of 5,000 cadaveric dissections of the forearm did not identify any such variations related to FCU (ANG, ROZEN, VALLY et al., 2010).

Ciftçioğlu, Kopuz, Corumlu et al. (2011) reported an unusual muscle on the left side of a 65-year-old male cadaver. The anomalous muscle belly arose from the medial epicondyle approximately 1 cm posterolateral to the origin of the normal

FCU muscle, and from the proximal part of the FDS muscle. It inserted to the triquetral, hamate bones and flexor retinaculum. Passive traction on the tendon of the accessory muscle resulted in flexion of the radiocarpal junction. The FCU, which had one head, inserted into the pisiform bone, hook of hamate, and palmar aponeurosis. Its contiguous muscles displayed normal morphology.

Anatomic variations of the FDS in forms of tendon interconnections, substitutions, absences or muscle belly variations are reviewed by Elliot, Khandwala and Kulkarni (1999). Yesilada, Tatlidede, Çakmak et al. (2013) reported a unique large muscle belly of the FDS. The deformity is type V according to the classification of Elliot, Khandwala and Kulkarni (1999) in which the muscle belly extends to four digits (the index, middle, ring and little finger) in the right hand of a patient.

Guler, Kose, Turan et al. (2013) conducted a study to determine the prevalence of the absence of a FDS tendon to the little finger in a Turkish population. The overall prevalence of absence of FDS-V was 18.5%. The prevalence of functional absence of FDS-V was statistically similar between the body sides and sex ( $p = 0.258$  and  $p = 0.333$ ). The prevalence of symmetric occurrence of the variations in both hands was 87.2%. If a functional FDS were demonstrated in one hand, the probability of having a functional FDS-V in the contralateral hand would have been 91.8%. However, when the FDS-V was absent in one hand, the probability of having an absent FDS-V in the contralateral hand was 51.1%. The symmetric occurrence of variations was equally distributed in both sex and dexterity ( $p = 0.223$  and  $p = 0.201$ ). A bilateral absence of the FDS tendon to little finger in the upper limbs of a 45-year-old male cadaver was observed by Gupta and Kumar (2014).

Shoja, Tubbs, Loukas et al. (2008) reported an unusual variant of the FDS. The deep part was found to be split and showed two distinct fusiform muscle bellies. The medial belly originated from the common flexor tendon from the medial condyle of the humerus and continued as a thin tendon at the middle of the forearm to insert onto the fifth digit. The lateral belly blended proximally with the deep surface of the superficial portion of the FDS and ended in a relatively thicker tendon, which inserted onto the second digit. The median nerve passed between the medial and lateral bellies of the deep part of the FDS.

Rodrigues, Nayak, Rao et al. (2009) encountered an additional muscle in the anterior compartment of the forearm. This muscle took origin from the anterior surface of the radius in common with the FDS muscle. It had a tendon of origin and a tendon of insertion. Its fleshy radial belly and the tendon of insertion, crossed superficial to the median nerve. The muscle was inserted partly to the flexor retinaculum and partly to the undersurface of palmar aponeurosis.

An anomalous muscle in a patient with coexistent carpal and ulnar tunnel syndrome was demonstrated by magnetic resonance imaging and reported by Zeiss and Jakab (1995). The muscle originated from the PL tendon and ulnar antebrachial fascia at the lower half of the forearm as a single belly, then diverged medially from the PL tendon and bifurcated. Both portions of the split muscle extended into the distal ulnar tunnel or Guyon's canal. One segment joined with the abductor digiti minimi muscle and the other with the flexor retinaculum.

Wahba, Singh and Lozanoff (1998) reported a well-developed anomalous muscle within the forearm flexor compartment.

The identified muscle originated from the intercompartmental septum on the medial side of the forearm just proximal to the wrist joint and inserted on the proximal phalanx of the fifth digit. It produced flexion of the metacarpophalangeal joint of the fifth digit. The muscle appeared to be an accessory belly of the FDP. The authors named the muscle the accessory flexor digiti minimi profundus. This muscle could possibly affect ulnar nerve function and circulation in the hand.

#### 4 Conclusion

The reported muscle in this study may be considered a variant of Gantzer's muscle. Considering its origin from the FDS, it is a rare muscle that has been reported to be present only in about 2% of the specimen studied in one report [24] but more commonly in other reports [30, 50].

The incidence of Gantzer's muscle was reported to be more than 50% of individuals worldwide (AL-QATTAN, 1996; EL DOMIATY, ZOAIR and SHETA, 2008; GUNNAL, SIDDIQUI, DAIMI et al., 2013; JONES, ABRAHAMS, SAÑUDO et al., 1997; KARA, ELVAN, YILDIZ et al., 2012; MAHAKKANUKRAUH, SURIN, ONGKANA et al., 2004; OH, CHUNG and KOH, 2000; PAI, NAYAK, KRISHNAMURTHY et al., 2008; UYAROGLU, KAYALIOGLU and ERTURK, 2006). A recent meta-analysis study (ROY, HENRY, PEKALA et al., 2015) reported the pooled prevalence of an accessory head of FPL (AHFPL) to be 44.2%. The accessory head of FPL was found more commonly in men than in women, and was slightly more prevalent on the right side than on the left side. Most authors found it to be bilateral in about 70% of cases. Mahakkanukrauh, Surin, Ongkana et al. (2004) observed it to be bilateral in 75.3% cases and to be unilateral in 24.7% cases. Uyaroglu, Kayalioglu and Erturk (2006) found it to be bilateral in 74% cases and to be unilateral in 26% cases. Gunnal, Siddiqui, Daimi et al. (2013) found it to be bilateral in 71.73% cases and to be unilateral in 28.26% cases. Some exceptions are the report of Jones, Abrahams, Sañudo et al. (1997) who found it to be bilateral in 58.4% cases and to be unilateral in 33.4% cases and the report by Oh, Chung and Koh (2000) who observed it to be bilateral in 50% cases and to be unilateral in 33% cases.

Gantzer's muscles are thought to be a causative factor in development of the anterior interosseous syndrome (AINS) or a cause of restricted movement of the FPL causing pain via a muscle-tendon shearing action (JONES, ABRAHAMS, SAÑUDO et al., 1997). The AINS is also called Kiloh-Nevin syndrome owing to their original description of the condition (KILOH and NEVIN, 1952). Compression of the anterior interosseous nerve (AIN) could be due to structural anomalies or trauma. Two types of AINS have been described as "incomplete" and "complete" syndromes (GUNNAL, SIDDIQUI, DAIMI et al., 2013). A complete AINS results in malfunction of all muscles innervated by the AIN, i.e. the FDP of the middle and index fingers, the FPL, and the PQ muscles. An incomplete AIN syndrome occurs where only the medial branch of the AIN to the FDP (which passes underneath the belly) is compressed, or the lateral branch to the FPL (which runs alongside the belly) is compressed. This results in the loss of function of only the FPL or the FDP. Tabib, Aboufarah and Asselineau (2001) reported a case of incomplete AINS, and Degreeef and De Smet (2004) reported a complete AINS due to mechanical compression by ahFPL. Mahakkanukrauh,

Surin, Ongkana et al. (2004) suggested that AINS occurs when the nerve passes posterior to the belly of the accessory head of FPL. This was confirmed by Oh, Chung and Koh (2000).

Manual muscle testing, observation of pinch, and electrodiagnostic testing are reported to be useful in the diagnosis of AINS (KARA, ELVAN, YILDIZ et al., 2012; SPINNER, 1970). With the interosseous nerve paralysis, the index finger shows hyperextension of the distal interphalangeal joint and increased flexion of the proximal interphalangeal joint during pinch.

There is a close relationship between the anterior interosseous nerve and the accessory head of the FPL muscle. In this study the nerve was located posterior to the muscle. Gunnal, Siddiqui, Daimi et al. (2013) reported that the nerve passes posterior to the muscle in 90.21% of the cases and anterior to the muscle in 9.78% of cases. El Domiaty, Zoair and Sheta (2008); Jones, Abrahams, Sañudo et al. (1997); Kara, Elvan, Yildiz et al. (2012); Oh, Chung and Koh (2000) reported that the nerve is located posterior to the muscle belly. Al-Qattan (1996), and Dellon and Mackinnon (1987) reported that the nerve is located anterior to the muscle belly. Mahakkanukrauh, Surin, Ongkana et al. (2004) reported that the nerve passed anterior to the muscle in 13.4% of cases, passed lateral to the muscle in 65.8%; it passed posterior to the muscle in 8.1%; and passed both lateral and posterior to the muscle in 12.8% of the specimens studied. Uyaroglu, Kayalioglu and Erturk (2006) reported that the AIN passed anterior to the muscle in one case (3.7%), lateral in 3 (11.1%), posterolateral in 8 (29.6%) and posterior in 15 (55.6%) cases. Kara, Elvan, Yildiz et al. (2012) reviewed the origin, shape, and relationship of accessory head of the FPL to the anterior interosseous nerve.

The presence of Gantzer's muscle indicates the embryonic development of the superficial and deep flexor layers from the common flexor mass. This muscle as well as the more common humeral and coronoid heads of the FPL may be a result of incomplete differentiation (BERGMAN, THOMPSON and AFIFI, 1988; GUNNAL, SIDDIQUI, DAIMI et al., 2013).

Compared to other upper limb muscles, the PL is known to exhibit the most variation. The PL tendon has been used for eyelid constructive surgery (UEDA, OBA, OKADA et al., 2007) and lower lip constructive surgery (JENG, KUO, WEI et al., 2004). It has been used for lip augmentation (DAVIDSON, 1995). Many surgeons agree that the PL tendon is the first choice as a donor tendon because it fulfils the necessary requirements of length, diameter, and availability.

PL anomalies are very important for hand surgeons. In spite of being a landmark to the structures of the wrist, the variations of this tendon may confuse even an experienced surgeon. The clinician must consider the possibility of variations if there is any suspicion of an abnormal swelling in the distal forearm.

As reviewed above almost all of the forearm musculature exhibit anatomical variations in some form. The presence of such anatomical anomalies is not usually noticed until the normal functions of an individual become hindered, or when these anomalies become a surgical problem. Prior to surgical approaches, surgeons should be acquainted with these variations and at the same time consider the possibility of individual anatomical uniqueness of human beings.

**Acknowledgements:** I'm in great debt to my students and doctors 'to be' Jonathan Hootman, Caroline Reist, Elizabeth Sugg, and Adam Tate for their curiosity and love of knowledge. This was



evidence when they asked me about the anomalous muscle while dissecting their cadaver. I would like to thank Dr. Thomas Caceci of the Virginia-Maryland Regional College of Veterinary medicine for his critical review of the manuscript. This work would have not been possible without cadaver donors. Thank you for all donors.

## References

- ABDEL-HAMID, GA., EL-BESHBISHY, RA. and ABDEL AAL, IH. Anatomical variations of the hand extensors. *Folia Morphologica*, 2013, vol. 72, n. 3, p. 249-257. PMID:24068687. <http://dx.doi.org/10.5603/FM.2013.0040>. </jrn>X
- ALBRIGHT, JA. and LINBURG, RM. Common variations of the radial wrist extensors. *The Journal of Hand Surgery*, 1978, vol. 3, n. 2, p. 134-138. PMID:632542. [http://dx.doi.org/10.1016/S0363-5023\(78\)80060-4](http://dx.doi.org/10.1016/S0363-5023(78)80060-4).
- AL-QATTAN, MM. Gantzer's muscle: an anatomical study of the accessory head of the flexor pollicis longus muscle. *The Journal of Hand Surgery*, 1996, vol. 21, n. 2, p. 269-270. PMID:8732417.
- ANG, GG., ROZEN, WM., VALLY, F., EIZENBERG, N. and GRINSELL, D. Anomalies of the flexor carpi ulnaris: clinical case report and cadaveric study. *Clinical Anatomy*, 2010, vol. 23, n. 4, p. 427-430. PMID:20196127. <http://dx.doi.org/10.1002/ca.20952>.
- ARI, I., SENDEMIR, E., KURT, MA. and IKIZ, I. A rare case of a multiple variation of the muscles in the upper and lower extremities. *Kaibogaku Zasshi*, 1997, vol. 72, n. 6, p. 521-524. PMID:9465554.
- AVDAR, SC. and SEHIRLI, U. The accessory tendon of the extensor indicis muscle. *Okajimas Folia Anatomica Japonica*, 1996, vol. 73, n. 2-3, p. 139-142. PMID:8870479. [http://dx.doi.org/10.2535/ofaj1936.73.2-3\\_139](http://dx.doi.org/10.2535/ofaj1936.73.2-3_139).
- BERGMAN, RA., THOMPSON, SA. and AFIFI, AK. *Compendium of human anatomic variation: text, atlas, and world literature*. Baltimore-Munich: Urban & Schwarzenberg, 1988.
- BETTENCOURT PIRES, MA., CASAL, D., MASCARENHAS DE LEMOS, L., GODINHO, CE., PAIS, D. and GOYRI-O'NEILL, J. An unusual variety of the extensor digiti muscles: report with notes on repetition strain injuries. *Acta Medica Portuguesa*, 2013, vol. 26, n. 3, p. 278-283. PMID:23815846.
- BHARDWAJ, P., BHANDARI, L. and SABAPATHY, SR. Supernumerary flexor carpi ulnaris: case report and review. *Hand Surgery*, 2013, vol. 18, n. 3, p. 393-397. PMID:24156584.
- BLUTH, BE., WU, B., ELENA STARK, M. and WISCO, JJ. Variant of the extensor pollicis tertius: a case report on a unique extensor muscle to the thumb. *Anatomical Science International*, 2011, vol. 86, n. 3, p. 160-163. PMID:20101486. <http://dx.doi.org/10.1007/s12565-010-0074-6>.
- CASANOVA MARTINEZ, D., VALDIVIA GANDUR, I. and GOLANO, P. Extensor pollicis et indicis communis or extensor indicis radialis muscle. *Anatomical Science International*, 2013, vol. 88, n. 3, p. 153-155. PMID:23255266. <http://dx.doi.org/10.1007/s12565-012-0164-8>.
- CASANOVA-MARTINEZ, D., VALDIVIA-GANDUR, I. and GOLANO, P. Extensor pollicis et indicis communis with triple slips in a bilateral case of accessory muscles of the hand. *Anatomical Science International*, 2014, vol. 89, n. 4, p. 250-254. PMID:24337982. <http://dx.doi.org/10.1007/s12565-013-0223-9>.
- CIFTÇIOĞLU, E., KOPUZ, C., CORUMLU, U. and DEMIR, MT. Accessory muscle in the forearm: a clinical and embryological approach. *Anatomy & Cell Biology*, 2011, vol. 44, n. 2, p. 160-163. PMID:21829760. <http://dx.doi.org/10.5115/acb.2011.44.2.160>.
- CLAASSEN, H. and WREE, A. Multiple variations in the region of mm: extensores carpi radialis longus and brevis. *Annals of Anatomy*, 2002, vol. 184, p. 489-491.
- DAVIDSON, BA. Lip augmentation using the palmaris longus tendon. *Plastic and Reconstructive Surgery*, 1995, vol. 95, n. 6, p. 1108-1110. PMID:7732124. <http://dx.doi.org/10.1097/00006534-199505000-00026>.
- DEGREEF, I. and DE SMET, L. Anterior interosseous nerve paralysis due to gantzer's muscle. *Acta Orthopaedica Belgica*, 2004, vol. 70, n. 5, p. 482-484. PMID:15587039.
- DELLON, AL. and MACKINNON, SE. Musculoaponeurotic variations along the course of the median nerve in the proximal forearm. *The Journal of Hand Surgery*, 1987, vol. 12, n. 3, p. 359-363. PMID:3437205.
- DURGUN, B., CELIK, HH., ATASEVER, A., YILMAZ, E. and HAYRAN, M. An unusual insertion of the palmaris longus muscle. *Kaibogaku Zasshi*, 1993, vol. 68, n. 1, p. 104-106. PMID:8517112.
- EID, N. and OTSUKI, Y. A case of double Gantzer's muscle and its possible role in nerve entrapment. *Clinical Anatomy*, 2009, vol. 22, n. 8, p. 881-882. PMID:19806672. <http://dx.doi.org/10.1002/ca.20862>.
- EL DOMIATY, MA., ZOAIR, MM. and SHETA, AA. The prevalence of accessory heads of the flexor pollicis longus and the flexor digitorum profundus muscles in egyptians and their relations to median and anterior interosseous nerves. *Folia Morphologica*, 2008, vol. 67, n. 1, p. 63-71. PMID:18335416.
- ELLIOT, D., KHANDWALA, AR. and KULKARNI, M. Anomalies of the flexor digitorum superficialis muscle. *The Journal of Hand Surgery*, 1999, vol. 24, n. 5, p. 570-574. PMID:10597934.
- FLOYD, T., BURGER, RS. and SCIARONI, CA. Bilateral palmaris profundus causing bilateral carpal tunnel syndrome. *The Journal of Hand Surgery*, 1990, vol. 15, n. 2, p. 364-366. PMID:2324472. [http://dx.doi.org/10.1016/0363-5023\(90\)90125-B](http://dx.doi.org/10.1016/0363-5023(90)90125-B).
- GULER, F., KOSE, O., TURAN, A., BAZ, AB. and AKALIN, S. The prevalence of functional absence of flexor digitorum superficialis to the little finger: A study in a turkish population. *Journal of Plastic Surgery and Hand Surgery*, 2013, vol. 47, n. 3, p. 224-227. PMID:23617293. <http://dx.doi.org/10.3109/2000656X.2012.742019>.
- GUNNAL, SA., SIDDIQUI, AU., DAIMI, SR. and FAROOQUI, MS. A study on the accessory head of the flexor pollicis longus muscle (Gantzer's muscle). *Journal of Clinical and Diagnostic Research*, 2013, vol. 7, n. 3, p. 418-421. PMID:23634387.
- GUPTA, A. and KUMAR, V. Bilateral absence of flexor digitorum superficialis (fds) tendon of the little finger: clinical significance. *Journal of Clinical and Diagnostic Research*, 2014, vol. 8, n. 2, p. 135-136. PMID:24701505.
- HONG, MK. and HONG, MK. An uncommon form of the rare extensor carpi radialis accessorius. *Anatomischer Anzeiger*, 2005, vol. 187, n. 1, p. 89-92. PMID:15835405.
- JELEV, L. and GEORGIEV, GP. Unusual high-origin of the pronator teres muscle from a struthers' ligament coexisting with a variation of the musculocutaneous nerve. *Romanian Journal of Morphology and Embryology*, 2009, vol. 50, p. 497-499.
- JENG, SF., KUO, YR., WEI, FC., SU, CY. and CHIEN, CY. Total lower lip reconstruction with a composite radial forearm-palmaris longus tendon flap: A clinical series. *Plastic and Reconstructive Surgery*, 2004, vol. 113, n. 1, p. 19-23. PMID:14707618. <http://dx.doi.org/10.1097/01.PRS.0000090722.16689.9A>.
- JONES, M., ABRAHAMS, PH. and SAÑUDO, JR. Case report: accessory head of the deep forearm flexors. *Journal of Anatomy*, 1997, vol. 191, n. 2, p. 313-314. PMID:9306208. <http://dx.doi.org/10.1046/j.1469-7580.1997.19120313.x>.

- JONES, M., ABRAHAMAS, PH., SAÑUDO, JR. and CAMPILLO, M. Incidence and morphology of accessory heads of flexor pollicis longus and flexor digitorum profundus (gantzer's muscles). *Journal of Anatomy*, 1997, vol. 191, n. 3, p. 451-455. PMID:9419002. <http://dx.doi.org/10.1046/j.1469-7580.1997.19130451.x>.
- KAPLAN, E. Anatomical dissertation on muscular variations presented after gracious decision before the medical board ... The thirteenth day of March 1813. *Bulletin of the Hospital for Joint Diseases*, 1969, vol. 30, p. 191-198.
- KARA, A., ELVAN, O., YILDIZ, S. and OZTURK, H. Accessory head of flexor pollicis longus muscle in fetuses and adult cadavers and its relation to anterior interosseous nerve. *Clinical Anatomy*, 2012, vol. 25, n. 5, p. 601-608. PMID:22038878. <http://dx.doi.org/10.1002/ca.21296>.
- KAWASHIMA, T., KIKUSHIMA, S., YOKOTA, E., OHKUBO, F., YAMANA, Y., SATO, F. and SASAKI, H. A case of an accessory palmaris longus muscle and a duplicate palmaris longus muscle with special reference to their nerve supply--morphologic significance of a common innervation trunk. *Okajimas Folia Anatomica Japonica*, 2002, vol. 79, n. 2-3, p. 75-81. PMID:12425381. <http://dx.doi.org/10.2535/ofaj.79.75>.
- KILOH, LG. and NEVIN, S. Isolated neuritis of the anterior interosseous nerve. *British Medical Journal*, 1952, vol. 1, n. 4763, p. 850-851. PMID:14916168. <http://dx.doi.org/10.1136/bmj.1.4763.850>.
- LI, J. and MAO, QH. Accessory slips of the extensor digiti minimi. *Romanian Journal of Morphology and Embryology*, 2014, vol. 55, p. 487-489.
- MACALISTER, A. Additional observations on muscular anomalies in human anatomy (3rd series), with the catalogue of principal muscular variation hitherto published. *Transactions of the Royal Irish Academy*, 1875, vol. 25, p. 1-130.
- MAHAKKANUKRAUH, P., SURIN, P., ONGKANA, N., SETHADAVIT, M. and VAIDHAYAKARN, P. Prevalence of accessory head of flexor pollicis longus muscle and its relation to anterior interosseous nerve in thai population. *Clinical Anatomy*, 2004, vol. 17, n. 8, p. 631-635. PMID:15495169. <http://dx.doi.org/10.1002/ca.20016>.
- MEHTA, V., JYOTI, A., SURI, RK. and RATH, G. An assembly of anomalous extensor tendons of the hand--anatomical description and clinical relevance. *Acta Medica*, 2009, vol. 52, p. 27-30.
- MOORE, KL., DALLEY, AF. and AGUR, AMR. *Upper limb: moore clinically oriented anatomy*. 7th ed. Philadelphia: Wolters Kluwer/Lippincott Williams & Wilkins, 2014. p. 746-751.
- MURABIT, A., GNARRA, M. and MOHAMED, A. Reversed palmaris longus muscle: Anatomical variant - case report and literature review. *The Canadian Journal of Plastic Surgery*, 2013, vol. 21, n. 1, p. 55-56. PMID:24431941. <http://dx.doi.org/10.1177/229255031302100115>.
- NAIR, V., NAIR, RV., MOOKAMBIKA, RV., MOHANDAS RAO, KG. and KRISHNARAJA SOMAYAJI, S. Additional muscle fibers of brachioradialis with anomalous high origin and entrapment of radial nerve in an osseomuscular canal. *Bratislavske Lekarske Listy*, 2012, vol. 113, n. 10, p. 622-623. PMID:23233914.
- NATSIS, K., DIDAGELOS, M., MANOLI, S., VLASIS, K., PAPANATHANASIOU, E., SOFIDIS, G. and NERANTZIDOU, X. Fleshy palmaris longus muscle - a cadaveric finding and its clinical significance: a case report. *Hippokratia*, 2012, vol. 16, n. 4, p. 378-380. PMID:23935323.
- NATSIS, K., LEVVA, S., TOTLIS, T., ANASTASOPOULOS, N. and PARASKEVAS, G. Three-headed reversed palmaris longus muscle and its clinical significance. *Anatomischer Anzeiger*, 2007, vol. 189, p. 97-101.
- NAYAK, SR., HUSSEIN, M., KRISHNAMURTHY, A., MANSUR, DI., PRABHU, LV., D'SOUZA, P., POTU, BK. and CHETTIAR, GK. Variation and clinical significance of extensor pollicis brevis: a study in south indian cadavers. *Chang Gung Medical Journal*, 2009, vol. 32, n. 6, p. 600-604. PMID:20035638.
- NAYAK, SR., KRISHNAMURTHY, A., PAI, MM., PRABHU, LV., RAMANATHAN, LA., GANESH KUMAR, C. and THOMAS, MM. Multiple variations of the extensor tendons of the forearm. *Romanian Journal of Morphology and Embryology*, 2008, vol. 49, n. 1, p. 97-100. PMID:18273511.
- NAYAK, SR., MADHAN KUMAR, SJ., KRISHNAMURTHY, A., PRABHU, LV., RANADE, AV., RAI, R. and RAMANATHAN, L. An additional radial wrist extensor and its clinical significance. *Anatomischer Anzeiger*, 2007, vol. 189, n. 3, p. 283-286. PMID:17534036.
- NAYAR, R. and MCARTHUR, P. A supernumerary extensor tendon to the thumb with an accessory tendon to extensor indicis. *BMJ Case Reports*, 2009, vol. 2009. PMID:21686628. <http://dx.doi.org/10.1136/bcr.08.2008.0791>.
- NEBOT-CEGARRA, J., PEREZ-BERRUEZO, J. and REINA DE LA TORRE, F. Variations of the pronator teres muscle: Predispositional role to median nerve entrapment. *Archives d'Anatomie, d'Histologie et d'Embryologie Normales et Experimentales*, 1991, vol. 74, p. 35-45. PMID:1366347.
- OH, CS., CHUNG, IH. and KOH, KS. Anatomical study of the accessory head of the flexor pollicis longus and the anterior interosseous nerve in asians. *Clinical Anatomy*, 2000, vol. 13, n. 6, p. 434-438. PMID:11111895. [http://dx.doi.org/10.1002/1098-2353\(2000\)13:6<434::AID-CA7>3.0.CO;2-4](http://dx.doi.org/10.1002/1098-2353(2000)13:6<434::AID-CA7>3.0.CO;2-4).
- PAI, MM., NAYAK, SR., KRISHNAMURTHY, A., VADGAONKAR, R., PRABHU, LV., RANADE, AV., JANARDHAN, JP. and RAI, R., The accessory heads of flexor pollicis longus and flexor digitorum profundus: Incidence and morphology. *Clinical Anatomy*, 2008, vol. 21, n. 3, p. 252-258. PMID:18351652. <http://dx.doi.org/10.1002/ca.20612>.
- PARK, MJ., NAMDARI, S. and YAO, J. Anatomic variations of the palmaris longus muscle. *American Journal of Orthopedics*, 2010, vol. 39, n. 2, p. 89-94. PMID:20396682.
- PINAR, Y., GOVSA, F., BILGE, O. and CELIK, S. Accessory tendon slip arising from the extensor carpi ulnaris and its importance for wrist pain. *Acta Orthopaedica et Traumatologica Turcica*, 2012, vol. 46, n. 2, p. 132-135. PMID:22491439. <http://dx.doi.org/10.3944/AOTT.2012.2471>.
- POLESUK, BS. and HELMS, CA. Hypertrophied palmaris longus muscle, a pseudomass of the forearm: Mr appearance--case report and review of the literature. *Radiology*, 1998, vol. 207, n. 2, p. 361-362. PMID:9577481. <http://dx.doi.org/10.1148/radiology.207.2.9577481>.
- RAI, R., RANADE, AV., T, M., P J, J., D'COSTA, S. and C, M. A rare origin of abductor pollicis longus. *Romanian Journal of Morphology and Embryology*, 2010, vol. 51, n. 2, p. 399-400. PMID:20495764.
- RAOUF, HA., KADER, GA., JARADAT, A., DHARAP, A., FADEL, R. and SALEM, AH. Frequency of palmaris longus absence and its association with other anatomical variations in the Egyptian population. *Clinical Anatomy*, 2013, vol. 26, n. 5, p. 572-577. PMID:23339087. <http://dx.doi.org/10.1002/ca.22186>.
- RODRIGUES, V., NAYAK, SB., RAO, MK., VOLLALA, V., SOMAYAJI, N. and RAO, AS. Abnormal muscle in the anterior compartment of the forearm: a case report. *Cases Journal*, 2009, vol. 2, n. 1, p. 9125. PMID:20062702. <http://dx.doi.org/10.1186/1757-1626-2-9125>.
- RODRIGUEZ-NIEDENFUHR, M., VAZQUEZ, T., PARKIN, I., NEARN, L. and SAÑUDO, JR. Incidence and morphology of the brachioradialis accessorius muscle. *Journal of Anatomy*, 2001, vol. 199, n. Pt 3, p. 353-355. PMID:11554514. <http://dx.doi.org/10.1017/S0021878201008020>.
- ROY, AJ., ROY, AN., DE, C., BANERJI, D., DAS, S., CHATTERJEE, B. and HALDER, TC. A cadaveric study of the first dorsal compartment



- of the wrist and its content tendons: anatomical variations in the indian population. *Journal of Hand and Microsurgery*, 2012, vol. 4, n. 2, p. 55-59. PMID:24293951. <http://dx.doi.org/10.1007/s12593-012-0073-z>.
- ROY, J., HENRY, BM., PEKALA, PA., VIKSE, J., RAMAKRISHNAN, PK., WALOCHA, JA. and TOMASZEWSKI, KA. The prevalence and anatomical characteristics of the accessory head of the flexor pollicis longus muscle: a meta-analysis. *PeerJ*, 2015, vol. 3, p. e1255. PMID:26557419. <http://dx.doi.org/10.7717/peerj.1255>.
- ROY, S., MEHTA, V., SURI, R., RATH, G., DHURIA, R. and DAS, S. Bitendinous insertion of abductor pollicis longus coexistent with a rare accessory antebrachial muscle: clinico-anatomical considerations. *La Clinica Terapeutica*, 2010, vol. 161, n. 2, p. 159-161. PMID:20499032.
- SALGADO, G., CANTIN, M., INZUNZA, O., MUNOZ, A., SAEZ, J. and MACUER, M. Bilateral reversed palmaris longus muscle: A rare anatomical variation. *Folia Morphologica*, 2012, vol. 71, n. 1, p. 52-55. PMID:22532187.
- SEBASTIN, SJ., PUHAINDRAN, ME., LIM, AY., LIM, IJ. and BEE, WH. The prevalence of absence of the palmaris longus--a study in a chinese population and a review of the literature. *The Journal of Hand Surgery*, 2005, vol. 30, n. 5, p. 525-527. PMID:16006020. <http://dx.doi.org/10.1016/j.jhbs.2005.05.003>.
- SHOJA, MM., TUBBS, RS., LOUKAS, M. and SHOKOUHI, G. The split flexor digitorum superficialis. *Italian Journal of Anatomy and Embryology*, 2008, vol. 113, n. 2, p. 103-107. PMID:18702238.
- SPINNER, M. The anterior interosseous-nerve syndrome with special attention to its variations. *The Journal of Bone and Joint Surgery*, 1970, vol. 52-A, n. 1, p. 84-94. PMID:5411776. <http://dx.doi.org/10.2106/00004623-197052010-00007>.
- SPINNER, RJ. and SPINNER, M. Superficial radial nerve compression at the elbow due to an accessory brachioradialis muscle: A case report. *The Journal of Hand Surgery*, 1996, vol. 21, n. 3, p. 369-372. [http://dx.doi.org/10.1016/S0363-5023\(96\)80346-7](http://dx.doi.org/10.1016/S0363-5023(96)80346-7).
- TABIB, W., ABOUFARAH, F. and ASSELINEAU, A. Compression of the anterior interosseous nerve by Gantzer's muscle. *Chirurgie de la Main*, 2001, vol. 20, n. 3, p. 241-246. PMID:11496612. [http://dx.doi.org/10.1016/S1297-3203\(01\)00041-5](http://dx.doi.org/10.1016/S1297-3203(01)00041-5).
- TAKANASHI, Y., EDA, M., KAIDOH, T. and INOUE, T. A case of the bilateral duplicate palmaris longus muscles coupled with the palmaris profundus muscle. *Yonago Acta Medica*, 2012, vol. 55, n. 4, p. 75-80. PMID:24031143.
- UEDA, K., OBA, S., OKADA, M., HARA, M. and ZEN, N. Eyelid reconstruction with a composite radial forearm palmaris longus tendon flap. *Journal of Plastic, Reconstructive & Aesthetic Surgery*, 2007, vol. 60, n. 3, p. 256-259. PMID:17293282. <http://dx.doi.org/10.1016/j.bjps.2006.03.058>.
- UYAROGLU, FG., KAYALIOGLU, G. and ERTURK, M. Incidence and morphology of the accessory head of the flexor pollicis longus muscle (gantzer's muscle) in a turkish population. *Neurosciences*, 2006, vol. 11, n. 3, p. 171-174. PMID:22266615.
- VOLLALA, VR., NAGABHOOSHANA, S., BHAT, SM., POTU, BK. and RAKESH, V. Multiple accessory structures in the upper limb of a single cadaver. *Singapore Medical Journal*, 2008, vol. 49, n. 9, p. e254-e258. PMID:18830534.
- WAHBA, MY., SINGH, GD. and LOZANOFF, S. An anomalous accessory flexor digiti minimi profundus muscle: a case study. *Clinical Anatomy*, 1998, vol. 11, n. 1, p. 55-59. PMID:9445099. [http://dx.doi.org/10.1002/\(SICI\)1098-2353\(1998\)11:1<55::AID-CA9>3.0.CO;2-R](http://dx.doi.org/10.1002/(SICI)1098-2353(1998)11:1<55::AID-CA9>3.0.CO;2-R).
- WOOD, J. Variations in human myology observed during the winter session of 1867-68 at king's college, london. *Proceedings of the Royal Society of London*, 1868, vol. 16, p. 483-525. <http://dx.doi.org/10.1098/rspl.1867.0110>.
- YAMMINE, K. Clinical prevalence of palmaris longus agenesis: a systematic review and meta-analysis. *Clinical Anatomy*, 2013, vol. 26, n. 6, p. 709-718. PMID:23825029. <http://dx.doi.org/10.1002/ca.22289>.
- YAMMINE, K. The prevalence of the extensor digitorum communis tendon and its insertion variants: a systematic review and meta-analysis. *Clinical Anatomy*, 2014, vol. 27, n. 8, p. 1284-1290. PMID:24953717. <http://dx.doi.org/10.1002/ca.22429>.
- YAMMINE, K. The prevalence of the extensor indicis tendon and its variants: a systematic review and meta-analysis. *Surgical and Radiologic Anatomy*, 2015, vol. 37, n. 3, p. 247-254. PMID:25096501.
- YESILADA, AK., TATLIDEDE, HS., ÇAKMAK, E., KIYAK, MV. and KILINÇ, L. Anomalous large unique muscle belly of flexor digitorum superficialis and the absence of palmaris longus in the forearm. *Journal of Plastic, Reconstructive & Aesthetic Surgery*, 2013, vol. 66, n. 1, p. 137-139. PMID:22652291. <http://dx.doi.org/10.1016/j.bjps.2012.04.044>.
- ZAINO, CJ., MITGANG, JT., RAWAT, M. and PATEL, MR. Anomalous muscles within the first dorsal extensor compartment of the wrist. *Hand*, 2014, vol. 9, n. 4, p. 551-553. PMID:25414621. <http://dx.doi.org/10.1007/s11552-013-9580-z>.
- ZEISS, J. and JAKAB, E. Mr demonstration of an anomalous muscle in a patient with coexistent carpal and ulnar tunnel syndrome: case report and literature summary. *Clinical Imaging*, 1995, vol. 19, n. 2, p. 102-105. PMID:7773871. [http://dx.doi.org/10.1016/0899-7071\(94\)00036-C](http://dx.doi.org/10.1016/0899-7071(94)00036-C).

Received June 15, 2016  
Accepted April 11, 2017