

## Protective role of caffeine versus N-acetylcysteine in hyperoxic acute lung injury in neonatal rats

SADEK, A. S.<sup>1,2\*</sup>, KHATTAB, R. T.<sup>1,2</sup>, AMER, A. M.<sup>3</sup> and YOUSSEF, A. M.<sup>3</sup>

<sup>1</sup>Department of Anatomy, Faculty of Medicine, Taibah University, Prince Naif Ibn Abdulaziz, Tayba, 42353, Medina 42353, Saudi Arabia

<sup>2</sup>Department of Anatomy and Embryology, Faculty of Medicine, Ain Shams University, 38 Abbassia street, Faculty of Medicine, 11566, Cairo, Egypt

<sup>3</sup>Department of Anesthesia, Intensive Care and Pain management, Faculty of Medicine, Ain Shams University, 38 Abbassia street, Faculty of Medicine, 11566, Cairo, Egypt

\*E-mail: dr\_ahmedsamir79@yahoo.com

### Abstract

**Introduction:** Prolonged breathing of high oxygen concentration leads to hyperoxic acute lung injury. Neonatal Respiratory diseases usually require increased supplement of high oxygen concentrations, so neonates are more susceptible to hyperoxic acute lung injury. The aim of this work was to investigate the protective role of caffeine versus N-acetylcysteine against hyperoxic acute lung injury in neonatal rats. **Materials and Methods:** 32 albino rats aged seven days were used in this experiment. The pups were divided into four groups; 1) Control or normoxic group; rats placed in normoxic chamber where fraction of inspired oxygen (FiO<sub>2</sub>) was 0.21, 2) Hyperoxic group; rats were placed in hyperoxic chamber (FiO<sub>2</sub>>0.8) using an oxygen flow of 1.5 Litre/min, 3) Hyperoxia-CAF group; rats exposed to hyperoxia and received a single intra-peritoneal injection of 20 mg/kg caffeine just prior to exposure, and 4) Hyperoxia-NAC group; rats exposed to hyperoxia and received a single intra-peritoneal injection of 150 mg/kg N-acetylcysteine just prior to exposure. 48 hours after exposure, lung specimens were processed for histological and immunohistochemical study using caspase-3, cluster of differentiation-68-antibody (CD68) and interleukin-1-beta (IL-1β). **Results:** Neonatal hyperoxia led to severe impairment in lung architecture, with a highly significant increase in alveolar macrophages. Also, caspase and IL-1β immune-reaction were increased significantly as compared to control group. Caffeine could improve the histopathological picture of hyperoxic acute lung injury, and also could decrease alveolar macrophage count and IL-1β immune-reaction better than N-acetylcysteine. **Conclusion:** Caffeine is more effective than N-acetylcysteine in prophylaxis against hyperoxic acute lung injury in neonates.

**Keywords:** hyperoxia, neonatal rats, caffeine, n-acetylcysteine.

### 1 Introduction

Oxygen (O<sub>2</sub>) is gas of life as it is mandatory for cellular respiration and metabolism. O<sub>2</sub> is commonly used in many fields of medicine especially in operating theatres, emergency departments and intensive care units. O<sub>2</sub> is usually used to treat hypoxia that is associated with many pathological conditions especially cardiac and respiratory diseases. Unfortunately increased fraction of inspired oxygen (FiO<sub>2</sub>) is associated with toxic effects mainly in the lungs (BITTERMAN, 2009).

Although neonatal respiratory diseases as pulmonary hypertension and hyaline membrane disease often required high O<sub>2</sub> concentration supplement (MANTELL, HOROWITZ, DAVIS et al., 1999). Breathing of high FiO<sub>2</sub> (≥ 0.9) for prolonged time (> 24 hours) at normal atmospheric pressure is associated with high risk of hyperoxic acute lung injury (HALI) which is usually life threatening. Moreover, the severity of HALI is directly proportional to the partial oxygen pressure (PO<sub>2</sub>) and also to the duration of exposure (KALLET and MATTHAY, 2013). Hyperoxia could produce reactive O<sub>2</sub> species (ROS) which considered the main factor in developing HALI (MACH, THIMMESCH and PIERCE, 2011).

As preterm infants are commonly susceptible to lung injury due to resuscitation and oxygen therapy. There was an increased

concern to protect neonatal lungs against these detrimental effects (JOBE and IKEGAMI, 1998).

Caffeine (CAF) is a nonspecific adenosine receptor antagonist that is widely used in the treatment of apnea of prematurity, broncho-pulmonary dysplasia (BPD) in neonates (SCHMIDT, ROBERTS, DAVIS et al., 2006; DOBSON, PATEL, SMITH et al., 2014). Also, CAF as a methyl-xanthine derivative can improve respiratory morbidity through its beneficial effects on respiratory mechanics (DAVIS, BHUTANI, STEFANO et al., 1989).

N-acetylcysteine (NAC) is considered as a glutathione (GTH) precursor. GTH is considered the most important antioxidant system in lungs which decreased in many inflammatory lung conditions. NAC could improve oxygenation and decrease mortality rate in case of acute respiratory distress syndrome (ARDS) and acute lung injury due to its ability to increase GTH synthesis, and enhance glutathione-S-transferase (GST) activity, also through its direct effect on oxygen free radicals (MORADI, MOJTAHEDZADEH, MANDEGARI et al., 2009; GALVÃO, ANDRADE, MAIA et al., 2011).

The aim of this work was to investigate the possible protective role of CAF versus NAC against HALI in neonatal rats.

## 2 Materials and Methods

### 2.1 Experimental animals

32 seven days old Sprague Dawley albino rats of average body weight about 8-12 gms were used in this study. Rat pups were placed in a transparent airtight chambers (7.5' L x 5.5' W x 4' H) (Acrylic Small Animal Chambers, Model 93705206, Paragon Medical Supply, Florida, USA). The animals were placed either in the hyperoxic chamber exposed to  $FiO_2 > 0.8$  using an  $O_2$  flow of 1.5 L/min or they placed in the normoxic chamber exposed to room air where  $FiO_2 = 0.21$ .  $O_2$  concentration was monitored daily with an oxygen sensor (Drägerwerk AG, Lübeck, Germany). Rat mothers were kept with their pups throughout the study. Mothers were switched every 24 hours from hyperoxic chamber to another normoxic chamber to avoid  $O_2$  toxicity and to provide sufficient nutrition to their pups. All experimental methodology were performed according to National Institutes of Health guide for the care and use of Laboratory animals (NIH Publications No. 8023, revised 1978).

### 2.2 Drugs

1. CAF-citrate for intravenous (IV) administration (Caffeinospire<sup>®</sup>; Inspire Pharmaceutical Co. Egypt). Each ampoule contains 20 mg/mL caffeine citrate equal to 10 mg/mL caffeine base. CAF citrate was administered by intra-peritoneal injection (IPI) at a dose of 20 mg/kg body weight (LI, LI, HU et al., 2011);
2. NAC for IV administration (Hidonac<sup>®</sup>, Zambon Group, SPA, Vicenza, Italy). Each vial contains 200 mg/mL NAC. NAC was administered by IPI at a dose of 150 mg/kg body weight (XU, QU and LI, 2011).

### 2.3 Experimental design

Thirty two rat pups were divided into 4 groups, 8 in each group; 1) Control or normoxic group (Group N) contained rats exposed to room air ( $FiO_2 = 0.21$ ) for 48 hours and received IPI of dextrose 5% in water (Dx5%W) at an equivalent volume to that given to treated rats, 2) Hyperoxic group (Group H) contained rats exposed to hyperoxia ( $FiO_2 > 0.8$ ) for 48 hours and received Dx5%W at a volume equivalent to that given to treated rats by IPI, 3) Hyperoxia-Caf group (Group HC) contained rats exposed to hyperoxia for 48 hours and received a single IPI of 20 mg/kg CAF citrate diluted in 0.2 mL Dx5%W just prior to exposure, and 4) Hyperoxia-NAC group (Group HNAC) contained rats exposed to hyperoxia for 48 hours and received a single IPI of 150 mg/kg NAC diluted in 0.2 mL Dx5%W just prior to exposure. At the end of the experiment, all rats were anesthetized by IPI of ketamine 50 mg/kg, then sacrificed and segments from the lungs were obtained from different groups. Specimens were fixed in formalin and processed to paraffin blocks. 5 mm thickness sections were stained with Haematoxylin & Eosin (DRURY and WALLINGTON, 1980) and Masson's trichrome (BANCROFT and GAMBLE, 2002). An immunohistochemical (IHC) study was done using CD68, caspase-3 and IL-1 $\beta$ .

### 2.4 IHC staining

Five-mm thickness paraffin sections were de-paraffinized and dehydrated with a graded series of ethanol. endogenous peroxidase activity was blocked by hydrogen peroxide.

The following antibodies were used for the IHC analysis as primary antibodies: rat monoclonal anti-caspase-3 (diluted 1:100) (Thermo Scientific, Lab Vision, CA, USA, Cat#: MA1-16843, Lot #: QG2055501) (YANG, EL-NAHAS, THOMAS et al., 2001); anti-CD68 mouse monoclonal antibodies (diluted 1:200) (Lab Vision, Fremont, CA, Cat#: MS-1808-R7) (ELNER, ELNER, NIELSEN et al., 1992); rabbit polyclonal anti-IL-1 $\beta$  (diluted 1:200) (Abcam, Cambridge, MA, USA, Cat#: ab2105) (PLEWKA, MADEJ, PLEWKA et al., 2013). Then, the slides were washed by PBS and incubated with biotinylated rabbit anti-mouse IgG (1:100 dilution) (Vector Labs, Burlingame, VA, USA) for one hour. Then all slides were washed in PBS and incubated in avidin-biotin-peroxidase complex (Vector Lab. Inc., U.S.A) for one hour. 3,3' diaminobenzidine hydrogen peroxide was used as a chromogen to visualize the immune reaction. Counterstaining of tissues was done by using haematoxylin (BioGenex, Menarini Diagnostics, France Cat: 94685) (CATTORETTI, PILERI, PARRAVICINI et al., 1993). The immune reaction specificity was tested by replacing the primary antibody with PBS as a negative control. Under optical microscope, positive immune reaction was detected in the cytoplasm as brown particles or patches (KIERNAN, 1999).

### 2.5 Morphometric study

The image analyzer computer system Leica Qwin 600 (England) was used to evaluate the count of alveolar macrophage using CD68 immune-stained sections. Also, the area percentage of collagen fibers using Masson's trichrome-stained sections, and the area percentage of caspase-3 and IL-1 $\beta$  IHC staining were evaluated. The area percentage and the measuring frame of a standard area were chosen from the parameters measuring ten readings from five sections from randomly chosen five animals from each group.

### 2.6 Statistical analysis

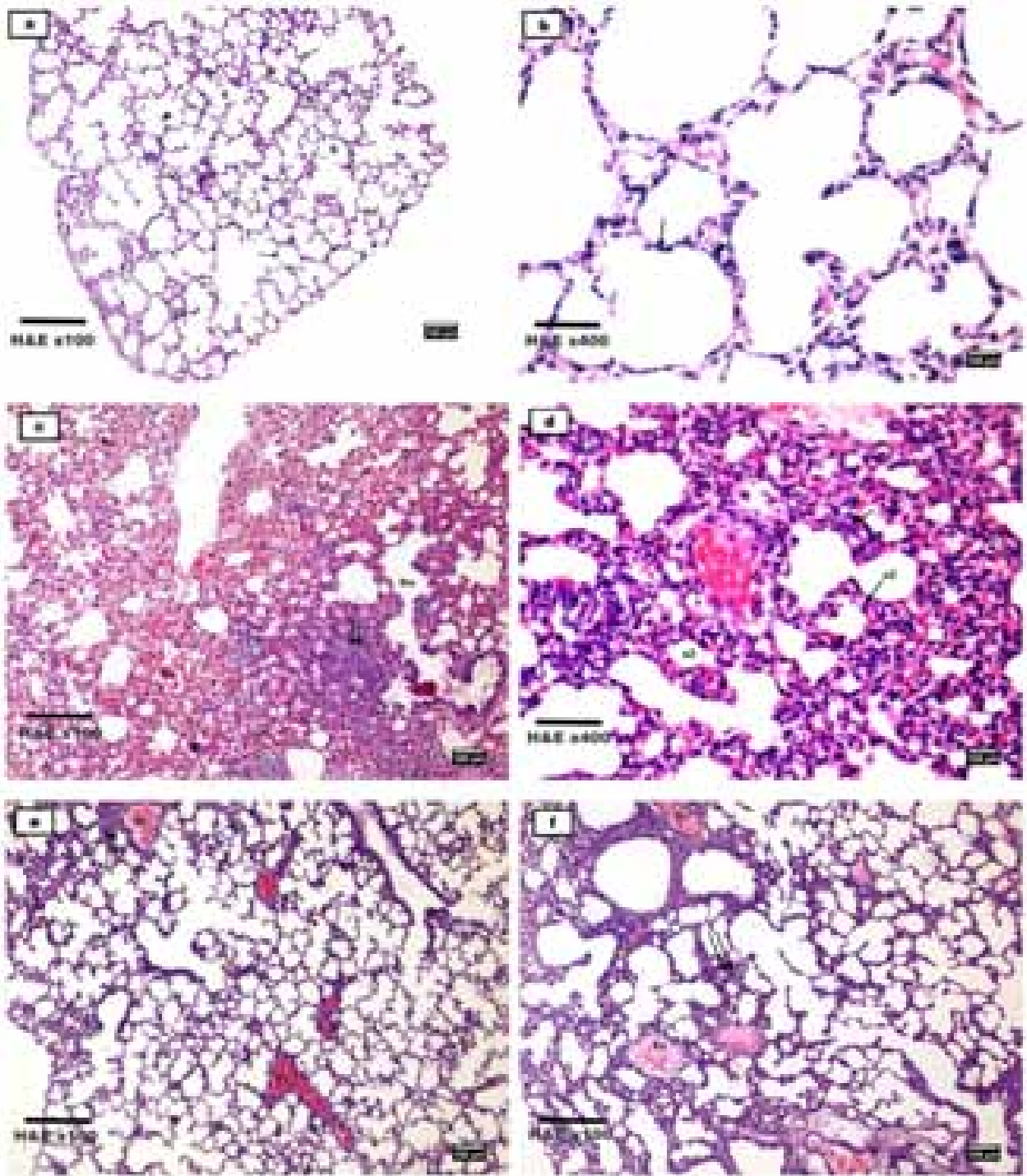
The collected data was presented in the form of mean and standard deviation. The count of alveolar macrophage, the area percentage of collagen fibers, caspase-3 and IL-1 $\beta$  were compared among all groups using One-way Anova Test. The degree of statistical significance was defined as  $P \leq 0.05$ . The significant differences among the four studied groups was indicated by using Scheffe's multiple comparison procedure.

## 3 Results

### 3.1 Histological findings

Examination of sections of rat lungs from the control group showed normal spongy architecture of the lung with bronchioles, blood vessels, alveolar sacs and alveoli with thin inter-alveolar septa. Also, there were many thin secondary septa (Figure 1a). The alveolar wall was lined by 2 types of epithelial cells; squamous epithelial cells or pneumocyte type-I and large cuboidal cells or pneumocyte type-II located at the angular junctions of the alveolar walls (Figure 1b).

Examination of lung sections of the hyperoxic group (Group H) showed loss of the normal lung architecture as some alveoli appeared with destructed walls together with fusion of some air spaces. There was massive infiltration of inflammatory cells into the alveolar spaces and the interstitium. Blood vessels were congested with extravasation of blood into the surrounding tissues. Many alveoli were collapsed and their inter-alveolar septa became thickened, while other alveoli



**Figure 1.** Photomicrographs of Hx & E stained sections from rat's lung of different groups; **the control group (Group N):** (a) normal histological architecture of the lung with bronchioles (B), blood vessels (Bv), alveolar sacs (S) and alveoli (a), with thin inter-alveolar septa (↑) and secondary septa (▲); (b) Squamous epithelial cells (pneumocyte Type I) (↑) and large cuboidal cells (pneumocyte Type II) (▲) lined the alveolar wall; **The hyperoxic group (Group H):** (c) Destroyed alveoli (Da) with fusion of air spaces. Inflammatory cellular infiltration (↑↑) in the interstitium. Blood vessels (Bv) were congested and blood was extravasated into the surrounding tissues; (d) Collapsed alveoli (a1) with thickened inter-alveolar septa (↑), and other alveoli (a2) were compensatorily dilated and expanded; **The Hyperoxia-CAF group (Group HC):** (e) Nearly normal lung architecture except for mild interstitial inflammatory cellular infiltration (↑↑). Few blood vessels (Bv) appeared dilated and congested; **The Hyperoxia-NAC group (Group HNAC):** (f) Some alveoli appeared normal while others showed thickened inter-alveolar septa (\*). Cellular infiltration (↑↑) and inflammatory exudate (Ex) were observed in the interstitium. Some blood vessels (Bv) appeared congested and dilated.

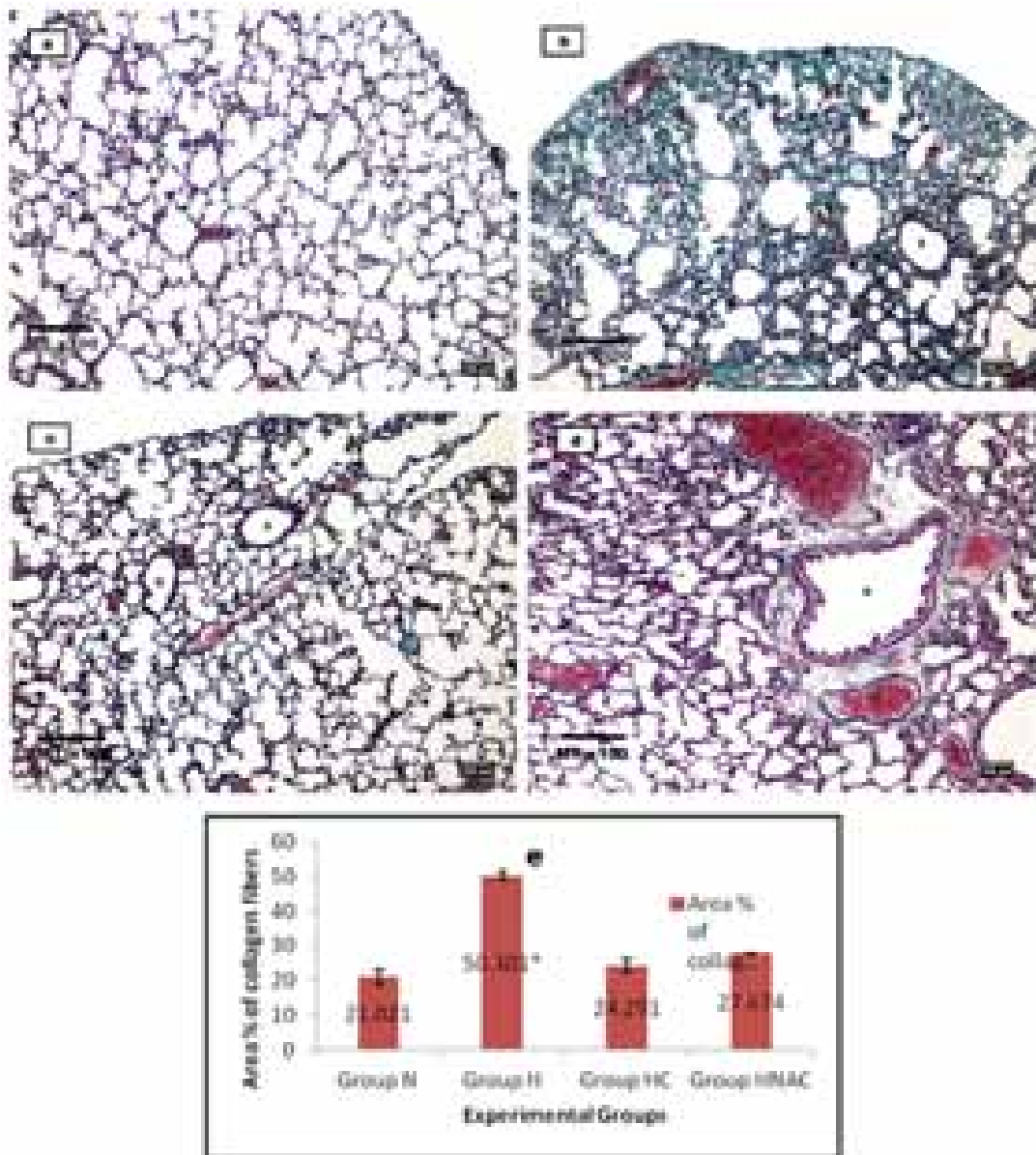
became dilated and expanded to compensate the collapsed ones (Figures 1c, d).

Examination of sections of the hyperoxia-CAF group (Group HC) showed that the architecture of the lung was nearly similar to that of the control group except for few alveoli showed mild thickening of their inter-alveolar septa with mild inflammatory cellular infiltration. Few blood vessels showed congestion and dilatation (Figure 1e).

Examination of sections of the hyperoxia-NAC group (Group HNAC) revealed moderate affection of the general architecture of the lung with areas of cellular infiltration and inflammatory exudate in the interstitium. Some blood vessels

appeared congested and dilated. Some alveoli appeared normal while others showed thickened inter-alveolar septa (Figure 1f).

Masson's trichrome-stained sections of lung tissue from the control group revealed normal distribution of fine collagen fibers around the bronchioles and blood vessels (Figure 2a). There was an excessive deposition of collagen fibres around the bronchioles and congested blood vessels as well as in the thickened inter-alveolar septa in lung sections from the hyperoxic group (Figure 2b). Masson's trichrome stained sections from the protected groups receiving CAF or NAC showed respectively mild to moderate deposition in collagen fibres around the bronchioles and blood vessels (Figures 2c, d).



**Figure 2.** Photomicrographs of Masson's trichrome-stained sections of the rat's lung from different groups; (a) Normal collagen distribution around the bronchioles and the blood vessels in the control group; (b) Excessive deposition of collagen fibers (\*) around the bronchioles and congested blood vessels as well as in the thickened inter-alveolar septa in group [H]; (c) Mild deposition of collagen fibers around the bronchioles (B) and blood vessels (Bv) in group [HC]; (d) Moderate deposition of collagen fibers around the bronchioles (B) and blood vessels (Bv) in group [HNAC]; (e) Area percent of collagen fibers among the four studied groups;  $P < 0.001 = (**)$  High significant difference between group H and other groups.

IHC staining using CD68 showed few alveolar macrophages that were normally distributed in the lung tissue of the control group. There was a highly significant increase in brown positively-stained macrophages in the lung parenchyma, especially in the inter-alveolar septa of group (H). Lung tissues of group (HC) showed more or less normal distribution of alveolar macrophages in the lung parenchyma, while there was a significant increase in alveolar macrophages in lung tissues of group (HNAC) as compared to the control group (Figures 3a-d).

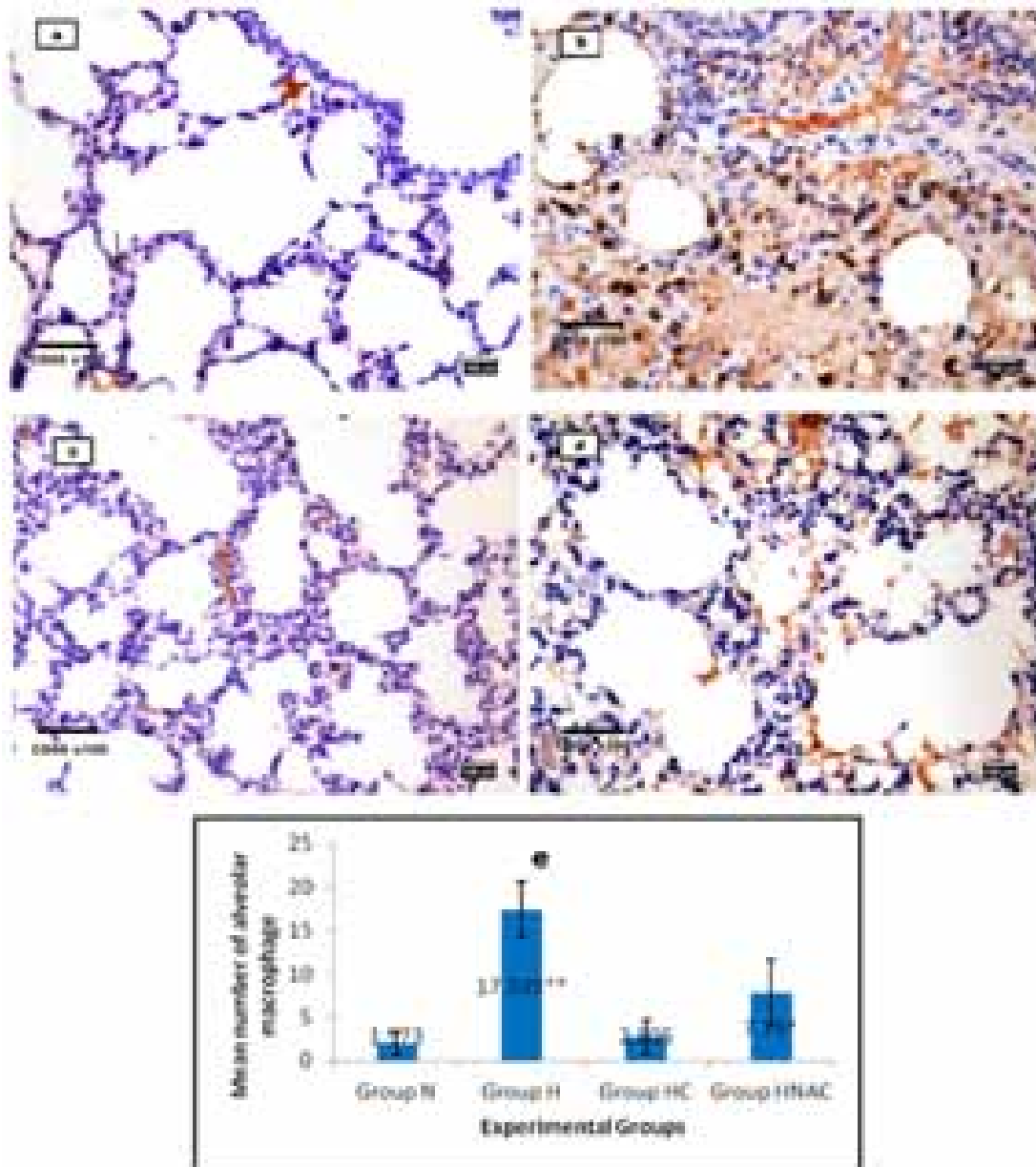
Examination of caspase-3 immune-stained sections of the control group revealed few positive apoptotic cells that had dark brown stained cytoplasm (Figure 4a). whereas caspase-3 immune-reaction was significantly increased in Group H

(Figure 4b). The immune-reaction in rats treated either with CAF (Group HC) or with NAC (Group HNAC) showed a non significant increase as compared to the control group (Figures 4c, d).

Expression of IL-1 $\beta$  IHC staining in lung sections of groups H and HNAC was significantly higher than that in the control group, while IL-1 $\beta$  immunoreactivity in group HC revealed a non-significant change as compared to group N (Figures 4e-h).

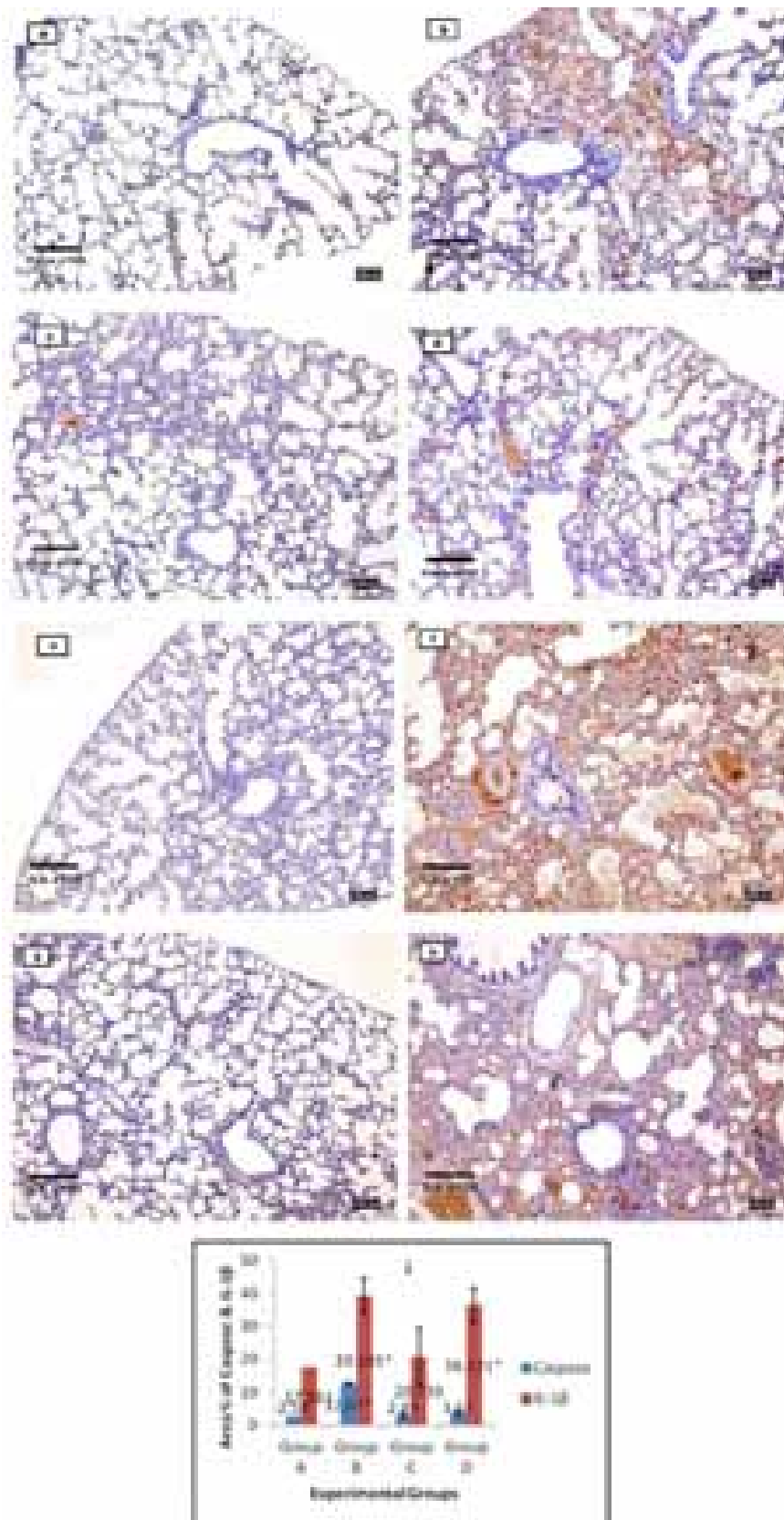
### 3.2 Morphometrical findings

Statistical comparison of the area percentage of collagen fibers (Figure 2e) and the count of alveolar macrophages (Figure 3e) revealed a highly significant increase in both parameters in group H as compared to other groups, and a significant increase



**Figure 3.** Photomicrographs of CD68 immune-stained sections of the rat's lung from different groups to detect alveolar macrophages ( $\uparrow$ ) in the lung tissue; (a) Control group (N); (b) Hyperoxic group (H); (c) Hyperoxia-CAF group (HC); (d) Hyperoxia-NAC group (HNAC); (e) The mean number of CD68 immune-stained alveolar macrophages among the studied groups;  $P < 0.05 = (*)$  Significant difference between groups HNAC and other groups;  $P < 0.001 = (**)$  High significant difference between groups H and other groups.





**Figure 4.** Photomicrographs of caspase immune-stained sections of the rat's lung from different groups; (a) Control group (N); (b) Hyperoxic group (H); (c) Hyperoxia-CAF group (HC); (d) Hyperoxia-NAC group (HNAC). Photomicrographs of IL-1 $\beta$  immune-stained sections of the rat's lung from different groups; (e) Control group (N); (f) Hyperoxic group (H); (g) Hyperoxia-CAF group (HC); (h) Hyperoxia-NAC group (HNAC); (i) The area percentage of caspase and IL-1 $\beta$  immune-reactivity among the studied groups;  $P < 0.05 = (*)$  Significant difference between groups H & HNAC and other groups.

in the mean number of alveolar macrophages in group HNAC as compared to groups N & HC. Also, the area percentage of caspase-3 expression was significantly increased in group H as compared to other groups. Whereas, the area percentage of IL-1 $\beta$  expression was significantly increased in groups H & HNAC as compared to other groups (Figure 4i).

#### 4 Discussion

Nowadays, O<sub>2</sub> supplementation is commonly used in patients of all ages, from neonates to elderly, to treat many lung diseases such as chronic obstructive pulmonary disease (COPD), pneumonia and ARDS (CORDINGLEY and KEOGH, 2002; STOLLER, PANOS, KRACHMAN et al., 2010).

In this study, exposure of rat neonates to hyperoxic condition (FiO<sub>2</sub> > 0.8) for 48 hours at normal atmospheric pressure led to severe impairment in the lung architecture, as many alveoli appeared either destructed or collapsed together with cellular infiltrations and blood extravasation into the surrounding tissues. Also, There was an excessive collagen deposition around the bronchioles and blood vessels. Neonatal hyperoxia in animals could cause lung disease resembling BPD in pre-mature infants (WARNER, STUART, PAPES et al., 1998). Congestion of blood vessels and infiltration of inflammatory cells in the lungs observed in our study might be referred to increased permeability of alveolar capillary membrane that evoked an inflammatory response via activation of many oxidative stress signaling pathways (DENEKE and FANBURG, 1980; ADAMSON, HEDGECOCK and BOWDEN, 1990). Clinically, there was an increased risk of HALI when FiO<sub>2</sub> > 0.7, and might become troublesome after prolonged breathing at FiO<sub>2</sub> > 0.8 (KALLET and MATTHAY, 2013). On the contrary, it was assumed by other authors that rats could adapt to high FiO<sub>2</sub> for long periods via many adaptive mechanisms including; proliferation of alveolar type-II cells and increased antioxidant enzymatic activity (CRAPO, BARRY, FOSCUE et al., 1980). Also, breathing of high FiO<sub>2</sub> (0.96-1.0) for 48 hours did not cause any toxic symptoms in humans (COMROE, DRIPPS, DUMKE et al., 1945).

The occurrence of HALI was referred to the release of ROS through mitochondrial oxidative phosphorylation. ROS could prevent cellular antioxidant mechanisms leading to recruitment of immune cells into the lung and damage of alveolar capillary endothelial cells, causing pulmonary inflammation and fibrosis, that finally might end by cell damage and death (MACH, THIMMESCH and PIERCE, 2011; KALLET and MATTHAY, 2013; DAVIES, KARMOUITY-QUINTANA, LE et al., 2014).

In this study, CAF administration just prior to hyperoxic exposure led to retaining of the lung architecture to its nearly normal pattern. CAF is a non-specific adenosine receptor antagonist. Adenosine is rapidly increased in case of tissue stress and injury (ZHOU, SCHNEIDER and BLACKBURN, 2009). Adenosine action is mediated by activation of four cell surface receptors (A1, A2A, A2B and A3), all of which are located in the lungs (FREDHOLM, 2007). Adenosine signalling was proved to be involved in regulation of chronic lung diseases, as lowering its level resulted in resolution of inflammation and tissue remodelling (SPICUZZA, DI-MARIA and POLOSA, 2006). On the other hand, the adenosine receptors antagonism by CAF could increase inflammation and aggravate alveolar arrest in neonatal mouse lung (DAYANIM, LOPEZ, MAISONET et al.,

2014). Another protective mechanism of CAF against HALI might be through its metabolite 1,7 di-methyl-xanthine, as Ter-Horst, Wagenaar, De-Boer et al. (2004) found that pentoxifylline as a methyl-xanthine derivative could reduce the occurrence of HALI in neonatal rats by decreasing inflammation and alveolar vascular leakage.

In our study, lung sections from group HNAC revealed moderate affection of lung architecture with interstitial cellular infiltration. Also, there was a statistically non-significant increase in collagen deposition as compared to the control group. Similarly, Langley and Kelly (1993) found that NAC could partially improve HALI, preventing the increase in bronchoalveolar lavage fluid protein concentration, leading to less oedema and inflammation. Also, they assumed that NAC effects were not mediated via increased GTH levels. NAC might exert its protective effect against HALI through attenuation of ROS-induced p38 mitogen-activated protein kinase activation (XU, TAN, KUANG et al., 2008). Although the antioxidant properties of NAC were widely accepted, hyperoxic rats treated with NAC showed some toxic signs in their lungs, especially at the epithelial side. This finding might be explained by rapid metabolism of NAC in the presence of high O<sub>2</sub> levels to cysteine that had many cellular toxic effects (VAN KLAVEREN, DINSDALE, PYPE et al., 1997).

In this study, the count of alveolar macrophages was highly significantly increased in group (H) as compared to the control group. Lung tissues of group (HC) showed more or less normal distribution of alveolar macrophages, while there was a significant increase in alveolar macrophages in group (HNAC) as compared to the control group. Alveolar macrophages could release many mediators as tumor necrotizing factor that augmented alveolar inflammatory response. Also, macrophages could release a neutrophilic chemotactic factor that could increase protease release, causing alveolar destruction (NAGATA, SUEMATSU, YOSHII et al., 1997). Moreover, hyperoxia could directly injure alveolar macrophages leading to lung damage either by generating ROS or by releasing fibronectin and alveolar macrophage-derived growth factor (TIPPING, CAMPBELL, BOYCE et al., 1988).

Caspases are a group of proteolytic enzymes that play an essential role in the transduction of apoptosis (TROY and JEAN, 2015). Caspase-3 is considered the key enzyme of the end stage of apoptosis, and its activation represents the "point of no return" within the apoptotic pathway (GUTHMANN, WISSEL, SCHACHTRUP et al., 2005; TROY and JEAN, 2015). In this study, caspase-3 activity in the lungs of the hyperoxic group was significantly increased. Similarly, previous authors stated that neonatal hyperoxia in mice could cause apoptosis in their lungs (MCGRATH-MORROW and STAHL, 2001). Also, we found that rats treated either with CAF or with NAC showed a non significant increase in caspase-3 expression in their lungs as compared to the control group. CAF is a known protein kinase inhibitor. It can inhibit protein kinases which resulted in DNA damage in case of apoptosis (SARKARIA, BUSBY, TIBBETTS et al., 1999). NAC was previously shown to block both death receptors and mitochondrial apoptotic pathways (JONES, MAELLARO, JIANG et al., 1995). Mitochondria has an important role in apoptosis progression by releasing cytochrome-c (Cyt-c), which is an inter-mitochondrial membrane protein which plays an important role in apoptosis via activation of caspase-3 (HARAGUCHI, TORII, MATSUZAWA et al., 2000). CAF administration

in mice model of neurodegenerative diseases could reduce Cyt.c levels, and subsequently reduce both caspase-9 and caspase-3 activities (ULLAH, ALI, ULLAH et al., 2015). On the contrary, Jiang, Lan, Zhang et al. (2015) found that CAF could stimulate mitochondrial release of Cyt-c that activate caspase-3 pathway, and in turn led to acceleration of cell apoptosis. Moreover, Dayanim, Lopez, Maisonet et al. (2014) assumed that CAF might induce alveolar apoptosis in the developing mouse lung exposed to hyperoxic condition. Also, NAC's anti-apoptotic activity was referred to its ability to inhibit Cyt-c release from the mitochondria, which in turn might inhibit the proteolytic processing of caspases-3 & 7 and increase the expression of Bcl-2 and other survival proteins (ROSATI, SABATINI, AYROLDI et al., 2004).

IL-1 $\beta$  belongs to interleukin-1 family of cytokines. This cytokine is an important inflammatory mediator released by activated macrophages as a pro-protein, then activated by caspase-1. IL-1 $\beta$  is involved in many cellular activities, including cell differentiation, proliferation and apoptosis (BENSI, RAUGEI, PALLA et al., 1987). In our study, IL-1 $\beta$  IHC expression in lung sections of the hyperoxic group was significantly higher than that in the control group. Previous studies revealed a correlation between elevated levels of IL-1 $\beta$  and development of BPD (CAYABYAB, JONES, KWONG et al., 2003; BOSE, DAMMANN and LAUGHON, 2008). Similarly, Cetinkaya, Cansev, Kafa et al. (2013) postulated that the pro-inflammatory cytokines IL-6, IL-1 $\beta$  and TNF- $\alpha$  were increased due to exposure to hyperoxia. Also, Piedboeuf, Horowitz, Johnston et al. (1998) observed an increase in IL-1 $\beta$  mRNA together with wide spreading of IL-1 $\beta$  IHC expression in the lungs of adult mice after 3 days of hyperoxia. In our study, group (HC) showed IL-1 $\beta$  IHC expression in lung sections nearly similar to that in the control group. Adenosine acting via A<sub>2</sub>A receptor was a chief regulator of inflammatory activity resulted in a significant increase in IL-1 $\beta$  production (OUYANG, GHANI, MALIK et al., 2013). CAF could modulate IL-1 $\beta$  release either by blocking of adenosine receptors or via phosphodiesterases inhibition and toll-like receptors modulation (CHAVEZ-VALDEZ, AHLAWAT, WILLS-KARP et al., 2016). In our study, NAC could not significantly alter the IL-1 $\beta$  positive immunoreaction observed in the hyperoxic group. The nuclear factor  $\kappa$ B (NF- $\kappa$ B) has a principal role in the immune control of inflammatory response mediated by IL-1 $\beta$  (PLEWKA, MADEJ, PLEWKA et al., 2010). NAC had no effect on IL-1 $\beta$  induced activation of NF- $\kappa$ B or signal transducer and DNA binding activity (JIANG, HAVERTY and BRECHER, 1999).

## 5 Conclusion

Our findings suggest a novel and easily applicable prophylaxis against HALI in neonates, and provide new insight into our scientific knowledge of caffeine. However, further investigations are needed to determine the proper dose and route of administration in neonates to achieve the best outcome for treatment.

## References

ADAMSON, I., HEDGECOCK, C. and BOWDEN, D. Epithelial cell-fibroblast interactions in lung injury and repair. *American Journal of Pathology*, 1990, vol. 137, n. 2, p. 385-392. PMID:1696785.

BANCROFT, J. and GAMBLE, M. *Theory and practice of histological techniques*. 5th ed. Edinburgh: Churchill Livingstone, 2002.

BENSI, G., RAUGEI, G., PALLA, E., CARINCI, V., TORNESE-BUONAMASSA, D. and MELLI, M. Human interleukin-1 beta gene. *Gene*, 1987, vol. 52, n. 1, p. 95-101. PMID:2954882.

BITTERMAN, H. Bench-to-bedside review: oxygen as a drug. *Critical Care*, 2009, vol. 13, n. 1, p. 205. PMID:19291278.

BOSE, C., DAMMANN, C. and LAUGHON, M. BPD and inflammatory biomarkers in the premature neonate. *Archives of Disease in Childhood. Fetal and Neonatal Edition*, 2008, vol. 93, n. 6, p. 455-461. PMID:18676410.

CATTORETTI, G., PILERI, S., PARRAVICINI, C., BECKER, M., POGGI, S., BIFULCO, C., KEY, G., D'AMATO, L., SABATTINI, E., FEUDALE, E., REYNOLDS, F., GERDES, J. and RILKE, F. Antigen unmasking on formalin-fixed, paraffin-embedded tissue sections. *The Journal of Pathology*, 1993, vol. 171, n. 2, p. 83-98. PMID:7506771.

CAYABYAB, R., JONES, C., KWONG, K., HENDERSHOTT, C., LECART, C., MINOO, P. and RAMANATHAN, R. Interleukin-1beta in the bronchoalveolar lavage fluid of premature neonates: a marker for, maternal chorioamnionitis and predictor of adverse neonatal outcome. *The Journal of Maternal-Fetal & Neonatal Medicine*, 2003, vol. 14, n. 3, p. 205-211. PMID:14694976.

CETINKAYA, M., CANSEV, M., KAFA, I., TAYMAN, C., CEKMEZ, F., CANPOLAT, F., TUNC, T. and SARICI, S. Cytidine 5 -diphosphocholine ameliorates hyperoxic lung injury in a neonatal rat model. *Pediatric Research*, 2013, vol. 74, n. 1, p. 26-33. PMID:23598810.

CHAVEZ-VALDEZ, R., AHLAWAT, R., WILLS-KARP, M. and GAUDA, E. Mechanisms of modulation of cytokine release by human cord blood monocytes exposed to high concentrations of caffeine. *Pediatric Research*, 2016, vol. 80, n. 1, p. 101-109. PMID:26982450.

COMROE, J., DRIPPS, R., DUMKE, P. and DEMING, N. Oxygen toxicity. *Journal of the American Medical Association*, 1945, vol. 128, n. 10, p. 710-717.

CORDINGLEY, J. and KEOGH, B. The pulmonary physician in critical care. 8: ventilatory management of ALI/ARDS. *Thorax*, 2002, vol. 57, n. 8, p. 729-734. PMID:12149536.

CRAPO, J., BARRY, B., FOSCUE, H. and SHELBURNE, J. Structural and biochemical changes in rat lungs occurring during exposures to lethal and adaptive doses of oxygen. *The American Review of Respiratory Disease*, 1980, vol. 122, n. 1, p. 123-143. PMID:7406333.

DAVIES, J., KARMOUTY-QUINTANA, H., LE, T., CHEN, N., WENG, T., LUO, F., MOLINA, J., MOORTHY, B. and BLACKBURN, M. Adenosine promotes vascular barrier function in hyperoxic lung injury. *Physiological Reports*, 2014, vol. 2, n. 9, p. e12155. PMID:25263205.

DAVIS, J., BHUTANI, V., STEFANO, J., FOX, W. and SPITZER, A. Changes in pulmonary mechanics following caffeine administration in infants with bronchopulmonary dysplasia. *Pediatric Pulmonology*, 1989, vol. 6, n. 1, p. 49-52. PMID:2704583.

DAYANIM, S., LOPEZ, B., MAISONET, T., GREWAL, S. and LONDHE, V. Caffeine induces alveolar apoptosis in the hyperoxia-exposed developing mouse lung. *Pediatric Research*, 2014, vol. 75, n. 3, p. 395-402. PMID:24321990.

DENEKE, S. and FANBURG, B. Normobaric oxygen toxicity of the lung. *The New England Journal of Medicine*, 1980, vol. 303, n. 2, p. 76-86. PMID:6247652.

DOBSON, N., PATEL, R., SMITH, P., KUEHN, D., CLARK, J., VYAS-READ, S., HERRING, A., LAUGHON, M., CARLTON, D. and HUNT, C. Trends in caffeine use and association between clinical outcomes and time of therapy in very low birth weight infants. *The Journal of Pediatrics*, 2014, vol. 164, n. 5, p. 992-998. PMID:24461786.



- DRURY, R. and WALLINGTON, E. *Carleton histological techniques*. 5th ed. London: Oxford University Press, 1980.
- ELNER, S., ELNER, V., NIELSEN, J., TORCZYNSKI, E., YU, R. and FRANKLIN, W. CD68 antigen expression by human retinal pigment epithelial cells. *Experimental Eye Research*, 1992, vol. 55, n. 1, p. 21-28. PMID:1397126.
- FREDHOLM, B. Adenosine, an endogenous distress signal, modulates tissue damage and repair. *Cell Death and Differentiation*, 2007, vol. 14, n. 7, p. 1315-1323. PMID:17396131.
- GALVÃO, A., ANDRADE, A., MAIA, M., SILVA, K., BEZERRA, A., MELO, J., MORAIS, N., COSTA, T. and CASTRO, C. Antioxidant supplementation for the treatment of acute lung injury: a meta-analysis. *Revista Brasileira de Terapia Intensiva*, 2011, vol. 23, n. 1, p. 41-48. PMID:25299553.
- GUTHMANN, F., WISSEL, H., SCHACHTRUP, C., TOLLE, A., RUDIGER, M., SPENER, F. and RUSTOW, B. Inhibition of TNF alpha in vivo prevents hyperoxia-mediated activation of caspase 3 in type II cells. *Respiratory Research*, 2005, vol. 6, p. 10. PMID:15663790.
- HARAGUCHI, M., TORII, S., MATSUZAWA, S., XIE, Z., KITADA, S., KRAJEWSKI, S., YOSHIDA, H., MAK, T. and REED, J. Apoptotic protease activating factor 1 (Apaf-1) independent cell death suppression by Bcl2. *The Journal of Experimental Medicine*, 2000, vol. 191, n. 10, p. 1709-1720. PMID:10811864.
- JIANG, B., HAVERTY, M. and BRECHER, P. N-acetyl-L-cysteine enhances interleukin-1beta-induced nitric oxide synthase expression. *Hypertension*, 1999, vol. 34, n. 4, p. 574-579. PMID:10523329.
- JIANG, J., LAN, Y., ZHANG, T., YU, M., LIU, X., LI, L. and CHEN, X. The in vitro effects of caffeine on viability, cycle cycle profiles, proliferation, and apoptosis of glioblastomas. *European Review for Medical and Pharmacological Sciences*, 2015, vol. 19, n. 17, p. 3201-3207. PMID:26400523.
- JOBE, A. and IKEGAMI, M. Mechanisms initiating lung injury in the preterm. *Early Human Development*, 1998, vol. 53, n. 1, p. 81-94. PMID:10193929.
- JONES, D., MAELLARO, E., JIANG, S., SLATER, A. and ORRENIUS, S. Effect of N-acetyl-L-cysteine on T-cell apoptosis are not mediated by increased cellular glutathione. *Immunology Letters*, 1995, vol. 45, n. 3, p. 205-209. PMID:7558175.
- KALLET, R. and MATTHAY, M. Hyperoxic acute lung injury. *Respiratory Care*, 2013, vol. 58, n. 1, p. 123-141. PMID:23271823.
- KIERNAN, J. *Histological and histochemical methods: theory and practice*. 3rd ed. Oxford: Butterworth-Heinemann, 1999.
- LANGLEY, S. and KELLY, F. N-acetylcysteine ameliorates hyperoxic lung injury in the preterm guinea pig. *Biochemical Pharmacology*, 1993, vol. 45, n. 4, p. 841-846. PMID:8452559.
- LI, J., LI, G., HU, J., FU, X., ZENG, Y., ZHOU, Y., XIONG, G., YANG, N., DAI, S. and HE, F. Chronic or high dose acute caffeine treatment protects mice against oleic acid-induced acute lung injury via an adenosine A2A receptor-independent mechanism. *European Journal of Pharmacology*, 2011, vol. 654, n. 3, p. 295-303. PMID:21238452.
- MACH, W., THIMMESCH, A. and PIERCE, J. Consequences of hyperoxia and the toxicity of oxygen in the lung. *Nursing Research and Practice*, 2011, vol. 2011, p. 260482. PMID:21994818.
- MANTELL, L., HOROWITZ, S., DAVIS, J. and KAZZAZ, J. Hyperoxia-induced cell death in the lung: the correlation of apoptosis, necrosis, and inflammation. *Annals of the New York Academy of Sciences*, 1999, vol. 887, p. 171-180. PMID:10668473.
- MCGRATH-MORROW, S. and STAHL, J. Apoptosis in neonatal murine lung exposed to hyperoxia. *American Journal of Respiratory Cell and Molecular Biology*, 2001, vol. 25, n. 2, p. 150-155. PMID:11509323.
- MORADI, M., MOJTAHEDZADEH, M., MANDEGARI, A., SOLTAN-SHARIFI, M., NAJAFI, A., KHAJAVI, M., HAJIBABAYEE, M. and GHAREMANI, M. The role of glutathione S-transferase polymorphisms on clinical outcome of ALI/ARDS patient treated with N-acetylcysteine. *Respiratory Medicine*, 2009, vol. 103, n. 3, p. 434-441. PMID:18993042.
- NAGATA, N., SUEMATSU, R., YOSHII, C., MIYAZAKI, H., SUEISHI, K. and KIDO, M. Characterization of amiodarone pneumonitis as related to inflammatory cells and surfactant apoprotein. *Chest*, 1997, vol. 112, n. 4, p. 1068-1074. PMID:9377919.
- OUYANG, X., GHANI, A., MALIK, A., WILDER, T., COLEGIO, O., FLAVELL, R., CRONSTEIN, B. and MEHAL, W. Adenosine is required for sustained inflammasome activation via the A<sub>2A</sub> receptor and the HIF1 pathway. *Nature Communications*, 2013, vol. 4, p. 2909. PMID:24352507.
- PIEDBOEUF, B., HOROWITZ, S., JOHNSTON, C., GAMACHE, M., BELANGER, S., POUBELLE, P., WELTY, S. and WATKINS, R. Interleukin-1 expression during hyperoxic lung injury in the mouse. *Free Radical Biology & Medicine*, 1998, vol. 24, n. 9, p. 1446-1454. PMID:9641262.
- PLEWKA, A., MADEJ, P., PLEWKA, D., BOGUNIA, E., NOWACZYK, G., MOREK, M., CIUPINSKA-KAJOR, M. and SIERON-STOŁTNY, K. The TRAF2 and TRAF6 expression in myomas and myometrium of women in reproduction and perimenopausal age. *Folia Histochemica et Cytobiologica*, 2010, vol. 48, n. 3, p. 407-416. PMID:21071347.
- PLEWKA, A., MADEJ, P., PLEWKA, D., KOWALCZYK, A., MISKIEWICZ, A., WITTEK, P., LEKS, T. and BILSKI, R. Immunohistochemical localization of selected pro-inflammatory factors in uterine myomas and myometrium in women of various ages. *Folia Histochemica et Cytobiologica*, 2013, vol. 51, n. 1, p. 73-83. PMID:23690221.
- ROSATI, E., SABATINI, R., AYROLDI, E., TABILIO, A., BARTOLI, A., BRUSCOLI, S., SIMONCELLI, C., ROSSI, R. and MARCONI, P. Apoptosis of human primary B lymphocytes is inhibited by N-acetyl-L-cysteine. *Journal of Leukocyte Biology*, 2004, vol. 76, n. 1, p. 152-161. PMID:14726501.
- SARKARIA, J., BUSBY, E., TIBBETTS, R., ROOS, P., TAYA, Y., KARNITZ, L. and ABRAHAM, R. Inhibition of ATM and ATR kinase activities by the radiosensitizing agent, caffeine. *Cancer Research*, 1999, vol. 59, n. 17, p. 4375-4382. PMID:10485486.
- SCHMIDT, B., ROBERTS, R., DAVIS, P., DOYLE, L., BARRINGTON, K., OHLSSON, A., SOLIMANO, A. and TIN, A.W. Caffeine therapy for apnea of prematurity. *The New England Journal of Medicine*, 2006, vol. 354, n. 20, p. 2112-2121. PMID:16707748.
- SPICUZZA, L., DI-MARIA, G. and POLOSA, R. Adenosine in the airways: implications and applications. *European Journal of Pharmacology*, 2006, vol. 533, n. 1-3, p. 77-88. PMID:16458886.
- STOLLER, J., PANOS, R., KRACHMAN, S., DOHERTY, D. and MAKE, B. Oxygen therapy for patients with COPD: current evidence and the long-term oxygen treatment trial. *Chest*, 2010, vol. 138, n. 1, p. 179-187. PMID:20605816.
- TER-HORST, S., WAGENAAR, G., DE-BOER, E., VAN-GASTELEN, M., MEIJERS, J., BIEMOND, B., POORTHUIS, B. and WALTHER, F. Pentoxifylline reduces fibrin deposition and prolongs survival in neonatal hyperoxic lung injury. *Journal of Applied Physiology*, 2004, vol. 97, n. 5, p. 2014-2019. PMID:15208286.
- TIPPING, P., CAMPBELL, D., BOYCE, N. and HOLDSWORTH, S. Alveolar macrophage procoagulant activity is increased in acute hyperoxic lung injury. *American Journal of Pathology*, 1988, vol. 131, n. 2, p. 206-212. PMID:3358451.
- TROY, C. and JEAN, Y. Caspases: therapeutic targets in neurologic disease. *Neurotherapeutics*, 2015, vol. 12, n. 1, p. 42-48. PMID:25339539.

- ULLAH, F., ALI, T., ULLAH, N. and KIM, M. Caffeine prevents D-galactose-induced cognitive deficits, oxidative stress, neuro-inflammation and neuro-degeneration in the adult rat brain. *Neurochemistry International*, 2015, vol. 90, p. 114-124. PMID:26209154.
- VAN KLAVEREN, R., DINSDALE, D., PYPE, J., DEMEDTS, M. and NEMERY, B. N- acetylcysteine does not protect against type II cell injury after prolonged exposure to hyperoxia in rats. *The American Journal of Physiology*, 1997, vol. 273, n. 3, p. 548-555. PMID:9316488.
- WARNER, B., STUART, L., PAPES, R. and WISPE, J. Functional and pathological effects of prolonged hyperoxia in neonatal mice. *The American Journal of Physiology*, 1998, vol. 275, n. 1, p. 110-117. PMID:9688942.
- XU, F., TAN, L., KUANG, F., FANG, F., LU, Z. and WANG, X. Protective effect of N-acetylcysteine on hyperoxia-induced lung injury and its interaction with p38 mitogen-activated protein kinase signaling pathway. *Pediatrics*, 2008, vol. 121, n. 2, p. 155.
- XU, J., QU, J. and LI, H. N-acetylcysteine modulates acute lung injury induced by *Pseudomonas aeruginosa* in rats. *Clinical and Experimental Pharmacology & Physiology*, 2011, vol. 38, n. 5, p. 345-351. PMID:21401696.
- YANG, B., EL-NAHAS, A., THOMAS, G., HAYLOR, J., WATSON, P., WAGNER, B. and JOHNSON, T. Caspase-3 and apoptosis in experimental chronic renal scarring. *Kidney International*, 2001, vol. 60, n. 5, p. 1765-1776. PMID:11703594.
- ZHOU, Y., SCHNEIDER, D. and BLACKBURN, M. Adenosine signaling and the regulation of chronic lung disease. *Pharmacology & Therapeutics*, 2009, vol. 123, n. 1, p. 105-116. PMID:19426761.

Received February 24, 2017

Accepted June 21, 2017