

Treatment emergent obstructive sleep apnea after Chiari surgery: A case report

Hamed Amirifard
Khosro Sadeghniaat-Haghighi
Arezu Najafi*

Tehran University of Medical Sciences,
Occupational Sleep Research Center,
Baharloo Hospital - Tehran - Iran.

ABSTRACT

Patients with Chiari type I malformation may also present with sleep disordered breathing mainly central sleep apnea. Here, we report a patient with Chiari I malformation referred to our clinic because of snoring and sleep disordered breathing. He was a 28-year-old man referred to us for evaluation of snoring. An overnight polysomnography revealed central sleep apnea. On further evaluation of central sleep apnea, the patient found to have Chiari malformation type I on brain MRI. The patient developed obstructive sleep apnea after surgery for Chiari malformation. Accordingly, pap titration was performed for the patient's obstructive sleep apnea. In patients with central sleep apnea comprehensive evaluation of predisposing causes is required. Lesions of central nervous system including Chiari malformation should not be overlooked. Furthermore, after treatment of central sleep apnea follow up PSG is warranted to confirm newly emerged sleep breathing disorder such as obstructive sleep apnea.

Keywords: Sleep Disorders; Central Sleep Apnea; Chiari Malformation Type I.

***Corresponding author:**
Arezu Najafi
E-mail: najafecaz@gmail.com

Received: March 11, 2019;
Accepted: October 03, 2019.

DOI: 10.5935/1984-0063.20190140

INTRODUCTION

Chiari type I malformation is herniation of cerebellar tonsils^{1,2}. The herniation is a ≥ 5 mm downward displacement of cerebellar tonsils through the foramen magnum^{2,3}. The cause is attributed to decrease in volume of posterior skull fossa and prevalence is estimated to be 0.24- 3.6% in the general population³⁻⁵.

Chiari malformation presents with signs and symptoms of lesions located in cerebellum, brainstem or cervical cord. There are studies that reported patients with Chiari malformation and complaints related to sleep disordered breathing such as snoring⁶. Prevalence of sleep disordered breathing in the population is relatively high, 23.4% and 49.7% in women and men, respectively⁷. However, sleep disordered breathing is usually reported in association with neurological problems including syringomyelia, lower cranial nerve palsies, ataxia, long tract signs, paralyzed hemi diaphragm and autonomic dysfunction in this malformation⁶. Disorders of craniocervical junction such as Chiari malformation could cause sleep disordered breathing through affecting pathways in charge of respiration. 67.4 - 73% of patients with Chiari malformation may have sleep apnea syndrome⁸. Here, we report a man presenting with symptoms and signs of sleep apnea. He was revealed as a case of central sleep apnea with Chiari malformation in further follow up. Approach to diagnosis and treatment of a patient with central sleep apnea and Chiari malformation is presented and discussed here. Efficacy of surgery and importance of follow up in symptomatic patients with type I Chiari malformation and central sleep apnea is further discussed^{8,9}.

CASE REPORT

The patient was a 28-year-old man who referred to our sleep clinic with complaints including snoring, witnessed apnea, poor sleep quality, and excessive day time sleepiness. These symptoms have been considered by the patient since about three months ago.

He also mentioned the history of headache since four years ago. Location of headache was in occipital region and back of the neck. He mentioned that the headache is present most of the time during the day, but it was most severe after waking up. Headache was aggravated with Valsalva maneuver and flexion of the neck. Severe lightening pain radiating to both upper arms and low back (Lhermit's sign) was negative. Headache was not accompanied by photophobia, phonophobia, visual scotoma, or nausea and vomiting. The patient had no history of smoking, alcohol consumption or substance abuse. Patient was living in a town located in 1189m above sea level.

On physical examination his weight was 85 Kg and height was 170 cm and BMI 29.41 (Kg/m²). He had short neck and neck circumference was 40 cm. His STOP-BANG score was 5 and he had excessive daytime sleepiness when assessed by ESS (Epworth Sleepiness Scale) with a score of 15. Mallampati and tonsils classification were either 2, respectively. In neurologic examination, mental status, cranial nerves, and fundoscopy was normal. On motor examination the force of the four limbs was in normal range. Deep tendon reflexes increased, Hoffman

sign and non-sustained clonus was presented in upper and lower limbs, respectively. Plantar reflexes were downward and cutaneous reflexes were intact. Cerebellar, sensory, and gait examinations were also in normal range.

For the evaluation of snoring and sleep related characteristics, an overnight full polysomnography was performed with Nicolet 1A97 (Nicolet Instrument Corp, Madison and Wis) in sleep laboratory and the test was interpreted by two trained sleep medicine fellows and edited by a sleep medicine specialist with RPSGT certificate. PSG was conducted using EEG, electrooculography (EOG), electromyography (EMG) (legs and chin), movements of thoracic cage and abdomen, electrocardiography (EKG), and O₂ saturation. The recorded tests were analyzed according to American Academy of Sleep Medicine (AASM) 2015 scoring manual¹⁰.

In polysomnography, total measured sleep time was 440.4 min. with 11 awakenings (19.8 min. WASO). Sleep onset latency and REM latency were 18.1 and 253.9 min., respectively. The patient spent 460.2 min. in bed and had a sleep efficacy 95.7% (Table 1).

Table 1. Patient's baseline and post-surgery polysomnographic characteristics.

Parameter	Baseline	3 months later
Weight (Kg)	85	79
Total sleep time (min.)	440	414
Sleep onset latency (min.)	12.8	13.4
Sleep efficiency (%)	95.7	86.1
REM latency (min.)	241	245
Stage 1%	21.4	24.2
Stage 2%	57.9	51
Stage 3%	4.9	9.5
REM %	11.5	15.2
ApneaS		
Obstructive	26	65
Mixed	88	0
Central	423	0
Hypopnea		
Obstructive	68	172
Mixed	0	0
Central	0	0
Apnea index (/h)	73.2	9.4
Apnea-hypopnea index (/h)	82.4	34.3
Oxygen saturation		
Events<90%	52.9	65.1
Minimum	73	90
Arousals (/h)	11	11.9

The patient had 423 central apneas, 68 obstructive hypopneas and Respiratory effort related arousals (RERAs), 26 obstructive apneas, and 88 mixed apneas. Total measured Respiratory Disturbance Index (RDI) was 82.4/h. Average O₂ saturation in wakefulness was 91.5% and in sleep 89.1% and lowest O₂ saturation in sleep was 73%.

As the patient was diagnosed with central sleep apnea, a complete approach towards the etiology was performed. Cardiac evaluation for assessment of cardiac causes of central apnea was normal (Ejection Fraction: 65 %). Fasting blood glucose, thyroid and renal function tests were normal. In arterial blood gas analysis (ABG) test, PH was 7.44, PCO_2 : 34 (mmHg) and HCO_3^- : 23.1 (mEq/L). According to neurologic symptoms and signs brain and cervical MRI was performed. Sagittal brain images revealed downward tonsillar herniation of cerebral peduncles from foramen magnum and compression of lower medulla and upper cervical cord leading to signal change of these sites on T2 images. Mild central syringomyelia on upper thoracic cord was observed. All of the findings was in favor of type I Chiari Malformation (CM) (Figure 1). It seemed that central apnea was due to Chiari type I malformation. Subsequently, neurosurgery consult was performed. Suboccipital craniotomy with C1-2 laminectomy and duraplasty were carried out (Figure 2). After four weeks patient was followed up. Headache and excessive daytime sleepiness was prominently decreased (ESS:6). After 10 weeks post-surgery, polysomnography was repeated for the patient.

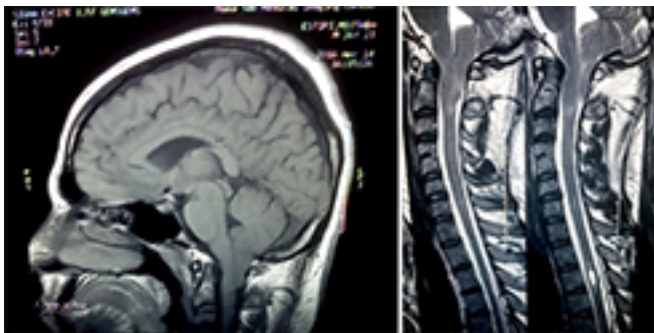


Figure 1. Sagittal T1 brain and T2 cervical MRI.

On follow up polysomnography total measured sleep time was 414 min. with 17 awakenings. Sleep onset latency and REM latency were 13.4 and 245 min., respectively. The patient spent 482 min. in bed and had a sleep efficacy of 86.1% (Table 1).

The patient had 65 obstructive apneas and 172 obstructive hypopneas and RERAs and no Central and mixed apneas. Patient's total RDI was 34.3/h. Average O_2 saturation in wakefulness and sleep were 90 and 89.7%, respectively. Lowest O_2 saturation in sleep was 89.5%. Pap titration was performed for the patient and he started using CPAP for treatment of emerging obstructive sleep apnea after the Chiari surgery.

DISCUSSION

Central sleep apnea is defined by cessation of airflow without respiratory effort which is due to absent or lack of ventilatory drive¹. Syndromes that consist CSA are categorized into two groups based on wakefulness CO_2 (Hypercapnic *vs.* Nonhypercapnic). The causes comprise a wide variety of clinical entities ranging from physiologic central sleep apnea to high altitude, congestive heart failure, medication; medical disorders and CNS causes of decreased ventilatory drive⁵.

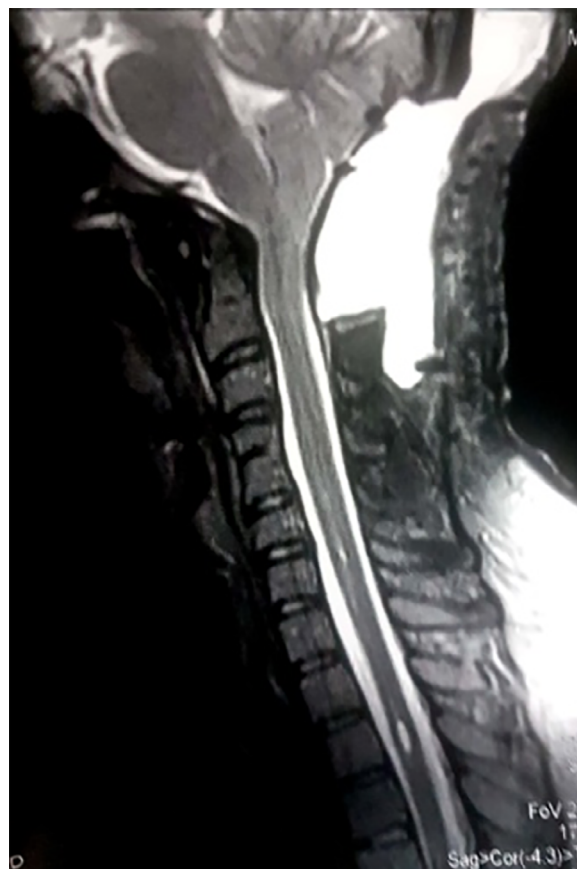

Figure 2. Sagittal T2 Cervical MRI.

Our patient presented with snoring and headache and according to history and physical examination and we decided to evaluate respiratory events during sleep. Polysomnography was performed and dominantly central sleep apnea was observed. The diagnosis of sleep apnea requires either, signs/symptoms or associated medical or psychiatric (e.g. depression) disorder coupled with five or more predominantly respiratory events (central, obstructive and mixed apneas, hypopneas, or respiratory effort-related arousals, as defined by the AASM scoring manual) per hour of sleep during PSG¹⁰. Alternatively, a frequency of respiratory events 15/h satisfies the criteria, even in the absence of associated symptoms or disorders and our patient met these criteria^{5,8,11}. Thus, we evaluated possible causes of CSA (Central Sleep Apnea) and such cardiac, metabolic, and systemic diseases. Echo Cardiography was performed and routine laboratory tests were done. CNS (Central Nervous System) evaluation was also performed. Arterial blood gases and drug use and patient altitude of living place was evaluated. Patient's brain MRI (Magnetic Resonance Imaging) revealed Chiari malformation type I. As the other causes were excluded and the patient was symptomatic, we approached to patient CNS lesion for management of CSA.

Craniocervical disorders show a wide variety of symptoms due to cerebellar, cranial nerve, high cervical dysfunction and also by affecting respiratory drive can lead to respiratory symptoms during sleep like central and obstructive apnea⁴.

Chiari disease or malformation is a congenital anatomic defect of skull base that presents with herniation of different levels of cerebellum depending on its type. The onset is in second or third decades of life. It is classified to five subtypes. Type I malformation is herniation of the cerebellar tonsils exceeding 5 mm below the foramen magnum. This malformation is typically associated with hydrosyringomyelia. It is not usually accompanied by descent of the brain stem or IV ventricle, nor associated with the presence of hydrocephalus.

Symptoms generally have an insidious onset and a progressive course. There is high clinical variability among patients, ranging from asymptomatic patients, patients with non-specific clinical manifestations, to patients with severe neurologic deficits¹². Our patient was symptomatic at time of first visit and had downward herniation of cerebellum from foramen magnum and compression of lower medulla and upper cervical cord was detected that lead to some signal change in T2 MRI sequences on MRI.

Suboccipital headache is the most frequent symptom in these patients. Neck pain, vertigo, diplopia, photopsia, blurred vision, dysphagia, ataxia, nystagmus, symptoms of involvement of the motor or sensory pathways, or lower cranial nerves are the other symptoms and signs. However, except headache our patient did not report other associating symptoms of this disease. Breathing-related sleep disorders are frequently reported in patients with craniocervical junction malformations. Chiari type I malformation should be considered in the differential diagnosis of central apneas in infants and adults, especially when they are associated with other neurological signs or symptoms^{1,6,8,12}. It is estimated that prevalence of sleep apnea syndrome in Chiari malformation is about 24-70% according to various studies and also obstructive apnea is more prevalent^{9,13,14}.

Patients with Chiari type I malformation that are asymptomatic are not considered for surgery of the lesion⁸. However, our patient was symptomatic with CSA dominant apnea syndrome on PSG. Thus, after consult with neurosurgery department, craniotomy and removing pressure from brainstem was considered for management of this patient. Previous studies have shown that surgical treatment in central sleep apnea in the case of Chiari malformation can improve symptoms¹⁵⁻¹⁷.

In our patient surgery decreased subjective symptoms such as snoring, witnessed apnea and excessive day time sleepiness. On PSG three months after surgery, we observed disappearance of CSA events. However, obstructive events increased in follow up PSG. That may be due to treatment of the cause of central events and revealing obstructive events. Previous Case reports have reported such findings. However, the interesting point is that the number of obstructive events increased in follow up PSG (emerging obstructive events). It may be due to treatment of central parts of patients' mixed apneas and emergence of obstructive events. The entity that needs more evaluation in future studies¹⁸⁻²⁰.

As the patient had severe obstructive sleep apnea in follow up PSG, treatment of obstructive apnea, CPAP after in-lab titration study was started and with 8 cm/H₂O pressure,

and nearly total of obstructive apneas resolved. Patients' AHI decreased to 1.5 events/hour.

This patient is an example of central nervous system cause of central apnea due to structural anomaly. It is important that medical team should be aware of disorders of the cervico-medullary junction that are potent to present as sleep-disordered breathing and may be fatal if they are overlooked by management team. It is also recommended to perform PSG after surgery to determine the rate of improvement or alteration of sleep apnea pattern after surgical treatment from central to obstructive pattern. The interesting point in present patient was emerging obstructive sleep apnea after Chiari malformation surgery. In previous and available studies, it is indicated that central apnea may arise after treatment of obstructive sleep apnea with positive airway pressure and the common pathophysiology between these two entities seems to be the cause²¹⁻²⁴. However, in our patient, obstructive sleep apnea emerged after elimination of central sleep apneas. Management of central parts of mixed apneas of the patient and the remaining obstructive events is speculated as a possible cause, but this pattern needs more investigation.

Summary

Chiari type I malformation has traditionally been defined as a downward herniation of the cerebellar tonsils through the foramen magnum. Craniocervical junction disorders such as Chiari malformation can cause sleep disordered breathing. In this presentation 28-year-old man with headache, snoring, and witnessed apnea was evaluated for sleep apnea. He had severe central apnea on PSG (AHI 82). After brain imaging Chiari type I malformation with compressive effect on central respiratory centers on brain stem was detected. Craniotomy and decompression was performed. Central apnea was resolved and remaining obstructive sleep apnea was treated with CPAP.

Authors declare conflict of interest. Informed consent was obtained from the patient prior to submitting the information.

REFERENCES

1. Botelho RV, Bittencourt LR, Rotta JM, Tufik S. The effects of posterior fossa decompressive surgery in adult patients with Chiari malformation and sleep apnea. *J Neurosurg*. 2010;112(4):800-7.
2. Adelman S, Dinner DS, Goren H, Little J, Nickerson P. Obstructive sleep apnea in association with posterior fossa neurologic disease. *Arch Neurol*. 1984;41(5):509-10.
3. Ali MM, Russell N, Awada A, McLean D. A cranio-cervical malformation presenting as acute respiratory failure. *J Emerg Med*. 1996;14(5):569-72.
4. Miyamoto M, Miyamoto T, Hirata K, Katayama S. A case of Arnold-Chiari Type I malformation presenting with dysrhythmic breathing during sleep. *Psychiatry Clin Neurosci*. 1998;52(2):212-6.
5. Berry RB, Brooks R, Gamaldo CE, Harding SM, Marcus CL, Vaughn BV, et al.; American Academy of Sleep Medicine (AASM). The AASM Manual for the Scoring of Sleep and Associated Events: Rules, Terminology and Technical Specifications. Darien: AASM; 2012.
6. Nohria V, Oakes WJ. Chiari I malformation: a review of 43 patients. *Pediatr Neurosurg*. 1990-1991;16(4-5):222-7.
7. Heinzer R, Vat S, Marques-Vidal P, Marti-Soler H, Andries D, Tobback N, et al. Prevalence of sleep-disordered breathing in the general population: the HypnoLaus study. *Lancet Respir Med*. 2015;3(4):310-8.
8. Dyste GN, Menezes AH, VanGilder JC. Symptomatic Chiari malformations. An analysis of presentation, management, and long-term outcome. *J Neurosurg*. 1989;71(2):159-68.

9. Dauvilliers Y, Stal V, Abril B, Coubes P, Bobin S, Touchon J, et al. Chiari malformation and sleep related breathing disorders. *J Neurol Neurosurg Psychiatry*. 2007;78(12):1344-8.
10. Berry RB, Gamaldo CE, Harding SM, Brooks R, Lloyd RM, Vaughn BV, et al. AASM Scoring Manual Version 2.2 Updates: New Chapters for Scoring Infant Sleep Staging and Home Sleep Apnea Testing. *J Clin Sleep Med*. 2015;11(11):1253-4.
11. Sateia MJ. International classification of sleep disorders-third edition: highlights and modifications. *Chest*. 2014;146(5):1387-94.
12. Bindal AK, Dunsker SB, Tew JM Jr. Chiari I malformation: classification and management. *Neurosurgery*. 1995;37(6):1069-74.
13. Losurdo A, Dittoni S, Testani E, Di Blasi C, Scarano E, Mariotti P, et al. Sleep disordered breathing in children and adolescents with Chiari malformation type I. *J Clin Sleep Med*. 2013;9(4):371-7.
14. Ferré Á, Poca MA, de la Calzada MD, Moncho D, Romero O, Sampol G, et al. Sleep-Related Breathing Disorders in Chiari Malformation Type 1: A Prospective Study of 90 Patients. *Sleep*. 2017;40(6).
15. Lam B, Ryan CF. Arnold-Chiari malformation presenting as sleep apnea syndrome. *Sleep Med*. 2000;1(2):139-44.
16. Spence J, Pasterkamp H, McDonald PJ. Isolated central sleep apnea in type I Chiari malformation: improvement after surgery. *Pediatr Pulmonol*. 2010;45(11):1141-4.
17. Kitamura T, Miyazaki S, Kadotani H, Kanemura T, Okawa M, Tanaka T, et al. Type I Chiari malformation presenting central sleep apnea. *Auris Nasus Larynx*. 2014;41(2):222-4.
18. Doherty MJ, Spence DP, Young C, Calverley PM. Obstructive sleep apnoea with Arnold-Chiari malformation. *Thorax*. 1995;50(6):690-1.
19. Levitt P, Cohn MA. Sleep apnea and the Chiari I malformation: case report. *Neurosurgery*. 1988;23(4):508-10.
20. Ely EW, McCall WV, Haponik EF. Multifactorial obstructive sleep apnea in a patient with Chiari malformation. *J Neurol Sci*. 1994;126(2):232-6.
21. Gay PC. Complex sleep apnea: it really is a disease. *J Clin Sleep Med*. 2008;4(5):403-5.
22. Kuzniar TJ, Pusalavidyasagar S, Gay PC, Morgenthaler TI. Natural course of complex sleep apnea--a retrospective study. *Sleep Breath*. 2008;12(2):135-9.
23. Morgenthaler TI, Kagramanov V, Hanak V, Decker PA. Complex sleep apnea syndrome: is it a unique clinical syndrome? *Sleep*. 2006;29(9):1203-9.
24. Kuźniar TJ, Kovačević-Ristanović R, Freedom T. Complex sleep apnea unmasked by the use of a mandibular advancement device. *Sleep Breath*. 2011;15(2):249-52.