

Surgical Treatment of Dermatomal Capillary Malformations in the Adult Face

Yoojeong Kim, Suk Joon Oh, Junsang Lee, Jihoon Yang, Sung Hoon Koh, Sung Won Jung

Department of Plastic and Reconstructive Surgery, Hallym University Sacred Heart Hospital, Hallym University College of Medicine, Anyang, Korea

Original Article

Background Facial capillary malformations (CMs) rarely recede; they often become darker and raised in proportion to their growth. These malformations may hypertrophy in adulthood, resulting in increased disfigurement and dysfunction. Laser treatment is considered a first-line therapy for focal CMs, but thick wide lesions, which are accompanied by hypertrophy and have a well-circumscribed nodularity, may be treated with surgical excision and reconstruction.

Methods We retrospectively reviewed the records of 25 consecutive patients who had undergone complete or partial excisions of facial capillary malformations in our unit. After the excisions, the defects that encompassed their facial aesthetic units were subsequently covered by various methods, including primary closures, local flaps, expanded flaps, split-thickness skin grafts, and full thickness skin grafts.

Results The data demonstrated satisfactory results and reliability. Our patients were treated without significant complications, and all of the patients were moderately or fully satisfied with the outcome of their surgeries.

Conclusions Among the many reconstructive options for adult patients with facial capillary malformations, thick split-thickness skin grafts can be a good choice for the coverage of widely excised wounds.

Keywords Vascular malformations / Skin transplantation / Surgical flap

Correspondence: Suk Joon Oh
Department of Plastic and Reconstructive Surgery,
Hallym University Sacred Heart Hospital, Hallym University College of Medicine, 22 Gwanpyeong-ro 170beon-gil, Dongan-gu, Anyang 431-796, Korea
Tel: +82-31-380-3780
Fax: +82-31-380-5980
E-mail: sjoh@hallym.or.kr

This article was presented at the 67th Congress of The Korean Society of Plastic and Reconstructive Surgeons on November 19-21, 2009 in Seoul, Korea.

No potential conflict of interest relevant to this article was reported.

Received: 1 Oct 2011 • Revised: 31 Jan 2012 • Accepted: 2 Feb 2012

pISSN: 2234-6163 • eISSN: 2234-6171 • <http://dx.doi.org/10.5999/aps.2012.39.2.126> • Arch Plast Surg 2012;39:126-129

INTRODUCTION

Vascular anomalies have been classified into vascular malformations and vascular tumors [1,2]. Vascular malformations rarely recede and grow more often with advancing years. These include capillary malformations (port-wine stains), venous malformations, lymphatic malformations, and arteriovenous malformations.

Facial capillary malformations (CMs) usually appear along the distribution of the sensory trigeminal nerve within 3 key areas: the ophthalmic region, including the forehead and upper

eyelid (V1), the maxillary region (V2), and the mandibular region (V3) [3]. CMs are commonly found on the face and may hypertrophy in adulthood, resulting in increased disfigurement and dysfunction. They also cause a significant psychological burden and social problems. In these circumstances, patients or their families often seek treatment [4].

Laser treatment is considered a first-line therapy for focal CMs because it offers safe and selective vascular destruction [4]. However, many lesions persist despite repeated treatment. The depth of laser light penetration is less than 2 mm, which likely limits its usefulness to very early superficial lesions [5]. Thick,

wide lesions, which are accompanied by hypertrophy and have a well-circumscribed nodularity, may be treated with surgical excision and reconstruction.

METHODS

We retrospectively reviewed the records of 25 consecutive patients who had undergone complete or partial excisions of facial CMs in our unit from March, 1996 to November, 2010. The patients included 11 men and 14 women who were between 22 and 60 years old (mean, 41.9 years). These CMs were located on the right in 12 patients and on the left in 9 patients. Four patients were affected bilaterally. The patients in their 20s and 30s had flat and pinkish-colored CMs, whereas patients in their 40s and

50s had more bumpy, convoluted, and purplish-colored CMs.

Segmental facial capillary malformations (facial dermatomal capillary malformations) affected sensory trigeminal nerve distribution and resulted in the following categories: V1 (n=1), V2 (n=11), V3 (n=2), V1 and V2 (n=6) (Fig. 1), V2 and V3 (n=2) (Fig. 2), and V1, V2, and V3 (n=3). Among the three V1, V2, and V3 patients, two were diagnosed with Sturge-Weber syndrome. Both had frontal lobe atrophy with expansion of the choroid plexus on computed tomography and magnetic resonance imaging of the brain. One of the two patients also had glaucoma. Neither patient had a history of seizures.

After excision of the facial CMs, the skin defects were subsequently covered by various methods, which included five primary closures, seven local flaps (including three cervicofacial

Fig. 1. V1 and V2 capillary malformation patient

(A, B) A 54-year-old man with nodular hypertrophied capillary malformation covering the V1 and V2 areas of the left face. (C) A purse-string suspension suture with 2-0 prolene was applied in the excision wound for the correction of the drooping upper lip and nasal ala. (D, E) An excellent appearance was noted at 15 months after excision and thick split-thickness skin graft (STSG). The purse-string sutures maintained facial symmetry without a contour deformity. Residual lesions were improved by 10 additional sessions of laser therapy. (F) A minimal hypertrophic scar of the lateral thigh was noted at the donor site of thick STSG.

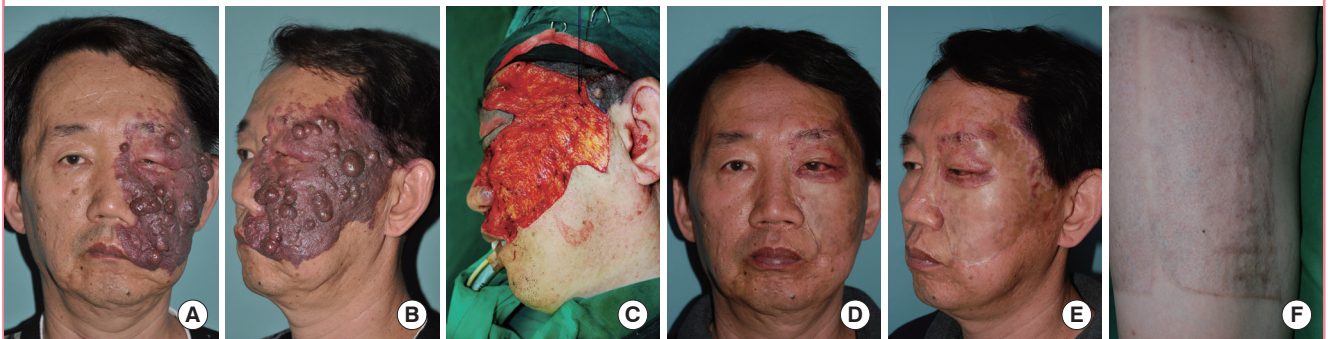
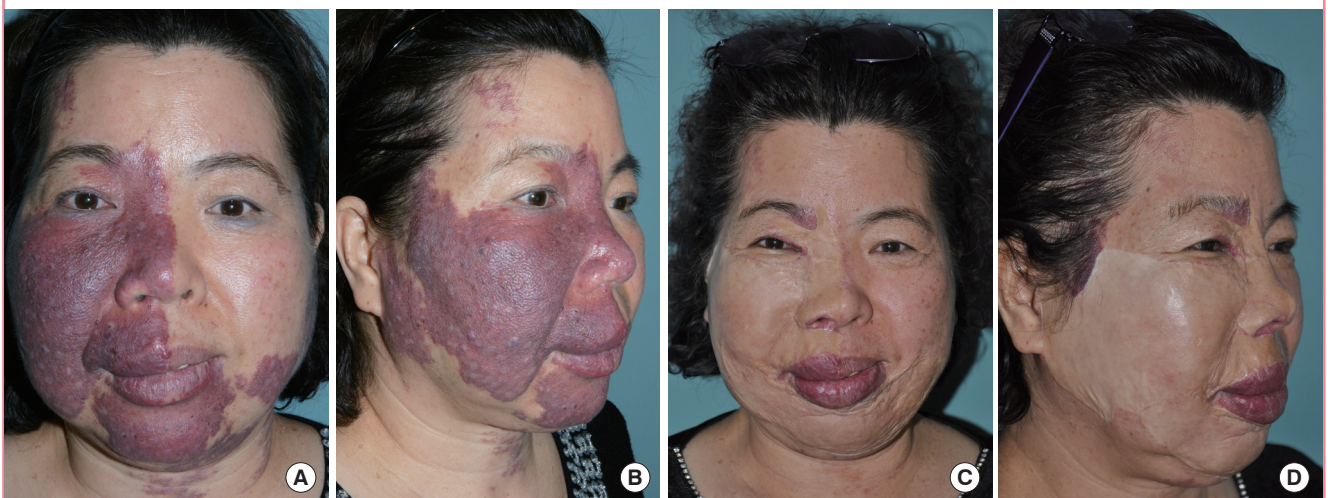

Fig. 2. V2 and V3 capillary malformation patient

A 56-year-old woman with a purplish-colored capillary malformation (CM) distributed on the V2 and V3 areas of the right face with nodular hypertrophy, ulceration, and bleeding. The contralateral side of chin area was also involved. (A) Frontal view. (B) Three-quarter view. The facial CM was initially excised and covered with thick split-thickness skin grafts. Marginal scars and wrinkles were improved by marginoplasty. Appearance one year after secondary surgeries. (C) Frontal view. (D) Three-quarter view.



flaps), one expanded flap, 10 full thickness skin grafts (FTSGs), and 14 thick split-thickness skin grafts (STSGs). Thirty-Seven surgeries were performed in 25 patients.

RESULTS

The data demonstrated satisfactory results and reliability. The average follow-up period in 25 patients was 13.2 months (from 2 to 34 months). Our patients were treated without significant complications, and all of the patients were moderately or fully satisfied with the outcome of their surgeries. Twenty-four patients were satisfied with the results (17 rated their outcomes as excellent, and seven described their results as good). One patient was moderately satisfied, and none of the patients were dissatisfied (considering the result poor or unacceptable). The patient who was moderately satisfied was treated with thick STSG for a buccal and cervical capillary malformation. He complained about postinflammatory hyperpigmentation of the grafted skin. However, hyperpigmentation was reduced by applying hydroxyquinone in a few months.

Primary closures and local flaps were performed in one step for focal lesions. If the lesions were medium-sized or wide, we often used serially combined surgeries. We used the expanded flap in a patient with medium-sized buccal capillary malformation. After removal of the tissue expanders, we covered the skin defect with local flaps. Afterward, secondary FTSGs were used to cover the remaining lesions (lower eyelid, philtrum and nasolabial fold). When we performed cervicofacial flaps for the V2 area (maxillary division), we covered the remaining lesions of the periorbital area with secondary FTSGs. In this case, the donor site of the FTSG was the supraclavicular area.

We used one-stage surgery with thick STSGs (20/1,000 inch thickness) for widely distributed facial CMs (Figs. 1, 2). To prevent drooping of the cheek after the skin grafts, we adopted face lift techniques (MACS-lift short scar rhytidectomy). Purse-string sutures were used to suspend the tissues under the grafted skin (Fig. 1C). The anchor point was the temporal fascia. In particular, the vertical, oblique, and malar suture loops were helpful for lifting buccal and perioral lesions. Tie-over dressing was maintained on the grafted site for 72 hours postoperatively and pressure dressings were applied for two weeks.

The lateral thigh served as the donor site for the thick STSGs in 14 patients. These donor wounds were covered by thin split-thickness (6-8/1,000 inch thickness) skin harvested from the adjacent thigh (Fig. 1F). The inguinal areas served as the donor site for the FTSGs in seven patients, and the lower abdominal skin obtained after abdominoplasty was used in two patients. In one patient, skin from the supraclavicular area was used for

secondary FTSGs.

Eight patients had lesions that involved the lips and gum. These lesions may grow larger with advancing age and lead to macrocheilia with lip incompetence and epulis with gingival bleeding. Therefore, we overcame difficulties with the lips and gum by using wedge resections of the lips and gingivoplasty, respectively.

DISCUSSION

Capillary malformations are composed of mature dilated capillaries and venules in the dermis layer, which impart a pink or purple hue to the involved skin. The pathogenesis is not clearly understood; however, several studies suggest that the autonomic nervous system is involved by means of altered neural modulation [6,7]. This suggestion may explain the dermatomal distribution of the lesions. Smoller and Rosen [8] proposed that a reduction in perivascular neural innervations (Schwann cells) leads to an altered modulation of vascular tone, causing progressive ectasia over time in CMs. Our patients noted purplish hypertrophic changes resulting in progressive disfigurement.

In general, laser treatments can be the first choice of treatment to improve the color of the lesions. The pulsed dye laser has been regarded as the most accepted laser for CMs [9,10]. However, it has considerable limitations when large areas or dermatomal patterns are involved [10]. Laser treatments require many sessions over 2-3 years, and, despite a promising initial response to the laser treatments, some CMs gradually develop several years after treatments [9].

Surgery can be employed for CMs that are resistant to laser treatments or to treat the soft tissue hypertrophy that occurs in certain cervicofacial locations.

A large capillary malformation was first treated by cutaneous dermal over-grafting by Adamson et al. [11] in 1978. Clodius [12] reported that a series of 50 patients were treated by subtotal excision of their port-wine stains and covering of the defect with selected FTSGs in 1985. In 1983, Argenta et al. [13] used tissue-expanding prostheses to augment local tissues in reconstructions of the head and neck. Cutaneous expansion might be used before the excision of moderately-sized CMs to permit linear closure along the border of a facial unit. Recently, some authors reported treatment of cervicofacial CMs using expanded flaps [14-16].

The surgical treatment of these lesions utilizes the entire spectrum of plastic surgery techniques from the simplest to the most complicated; these techniques include single or repeated excisions and coverage by skin grafts, and use of tissue expansion techniques with local flaps [15]. Surgical excision can be performed along the

dermatomal distribution and facial aesthetic units.

Primary closures and local flaps can be performed in small areas. STSGs, FTSGs, and expanded flaps can be used for larger areas. Some studies [13,15,17] have reported cases that were treated with FTSGs, but a major disadvantage of the use of FTSGs is limited donor harvesting. We experienced partial loss of full-thickness grafted skin harvested from abdominoplasties in two patients. At that time, secondary STSG was inevitable due to necrotic grafted skin. Therefore we considered an alternative to FTSGs, attempted thick STSGs for widely distributed facial CMs. The merit of the thick STSGs included the following: 1) There is no limit to donor harvesting, 2) The success rates of graft take are higher than FTSGs, and 3) A reconstruction can be performed by one-stage surgery. All the grafts survived without any complications and there were no concerns about recontracture, unlike thin or medium STSGs.

The results of thick STSG were satisfactory and reliable. The major disadvantage of using an STSG was the resulting unintended hypertrophic scars at the donor sites. Therefore, we harvested thin split-thickness skin (6-8/1,000 inch thickness) adjacent to the donor sites of thick STSGs and used that skin to cover the deep skin defects to prevent scar formation.

In addition, we performed marginoplasty at conspicuous marginal linear scars or wrinkles of the grafted skin according to the patients' needs several months after the first surgery. In two patients, laser therapy was also used to improve the color of CMs in locations where surgical intervention was not advisable, such as the periocular areas (Pulsed dye laser; 585 nm wavelength, 6 to 10 J/cm² fluence, 450 μsec pulse duration, 7 mm spot size; total of 10 treatment sessions).

Capillary malformations of the adult face can be aesthetically improved by wide excision and various reconstructive options. Primary closures and local flaps can be performed in focal facial CMs. If the lesions are medium-sized, expanded flaps, FTSGs, and STSGs can be used to cover the facial defects. Among the various reconstructive methods, thick STSGs can be a good choice in particularly thick, hypertrophic, and widely distributed facial CMs.

REFERENCES

- Mulliken JB, Glowacki J. Hemangiomas and vascular malformations in infants and children: a classification based on endothelial characteristics. *Plast Reconstr Surg* 1982;69:412-22.
- Enjolras O, Mulliken JB. Vascular tumors and vascular malformations (new issues). *Adv Dermatol* 1997;13:375-423.
- Enjolras O, Riche MC, Merland JJ. Facial port-wine stains and Sturge-Weber syndrome. *Pediatrics* 1985;76:48-51.
- Kelly KM, Choi B, McFarlane S, et al. Description and analysis of treatments for port-wine stain birthmarks. *Arch Facial Plast Surg* 2005;7:287-94.
- Batta K. Management of large birthmarks. *Semin Neonatol* 2000;5:325-32.
- Rydh M, Malm M, Jernbeck J, et al. Ectatic blood vessels in port-wine stains lack innervation: possible role in pathogenesis. *Plast Reconstr Surg* 1991;87:419-22.
- Lanigan SW, Cotterill JA. Objective assessments of port wine stains: response to temperature change. *Br J Dermatol* 1988;118:803-9.
- Smoller BR, Rosen S. Port-wine stains. A disease of altered neural modulation of blood vessels? *Arch Dermatol* 1986;122:177-9.
- Stier MF, Glick SA, Hirsch RJ. Laser treatment of pediatric vascular lesions: Port wine stains and hemangiomas. *J Am Acad Dermatol* 2008;58:261-85.
- Hennedige AA, Quaba AA, Al-Nakib K. Sturge-Weber syndrome and dermatomal facial port-wine stains: incidence, association with glaucoma, and pulsed tunable dye laser treatment effectiveness. *Plast Reconstr Surg* 2008;121:1173-80.
- Adamson JE, Wysocki JP, Ashbell TS. Treatment of a large hemangioma by dermal overgrafting: case report. *Plast Reconstr Surg* 1978;62:902-4.
- Clodius L. Surgery for the extensive facial port-wine stain? *Aesthetic Plast Surg* 1985;9:61-8.
- Argenta LC, Watanabe MJ, Grabb WC. The use of tissue expansion in head and neck reconstruction. *Ann Plast Surg* 1983;11:31-7.
- Low DW. Management of adult facial vascular anomalies. *Facial Plast Surg* 2003;19:113-30.
- Berwald C, Salazard B, Bardot J, et al. Port wine stains or capillary malformations: surgical treatment. *Ann Chir Plast Esthet* 2006;51:369-72.
- Kim JT, Kim SK. Surgical treatment of venous malformation and misdiagnosed superficial vascular anomalies. *J Korean Soc Plast Reconstr Surg* 1998;25:286-98.
- Yoo WJ, Lim SY, Pyon JK, et al. Usefulness of full-thickness skin graft from anterolateral chest wall in the reconstruction of facial defects. *J Korean Soc Plast Reconstr Surg* 2010;37:589-94.