

and XIIIa. Low-grade myxofibrosarcoma is positive for vimentin, but it is negative for CD34 and desmin. Myxoid neurofibroma is a tumor of neural origin, showing positive immunohistochemistry for S100, which is of help in making a differential diagnosis of SAF [1-5].

It is known that SAF has a benign natural course, for which the standard treatment modality is complete surgical removal. Incomplete surgical removal might cause a recurrence. Patients with SAF should be under regular follow-up. Prescott et al. reported that SAF had nuclear pleomorphism or mitotic activity showing malignant potential, but its malignant transformation or metastasis has not been described [1-5].

References

1. Fetsch JF, Laskin WB, Miettinen M. Superficial acral fibromyxoma: a clinicopathologic and immunohistochemical analysis of 37 cases of a distinctive soft tissue tumor with a predilection for the fingers and toes. *Hum Pathol* 2001;32:704-14.
2. Ashby-Richardson H, Rogers GS, Stadecker MJ. Superficial acral fibromyxoma: an overview. *Arch Pathol Lab Med* 2011;135:1064-6.
3. Hollmann TJ, Bovee JV, Fletcher CD. Digital fibromyxoma (superficial acral fibromyxoma): a detailed characterization of 124 cases. *Am J Surg Pathol* 2012;36:789-98.
4. Goo J, Jung YJ, Kim JH, et al. A case of recurrent superficial acral fibromyxoma. *Ann Dermatol* 2010;22:110-3.
5. Choi JH, Lee HJ, Jung SY, et al. A case of superficial acral fibromyxoma occurring after trauma in a childhood patient. *Korean J Dermatol* 2010;48:123-6.

Multiple Sparganosis in an Immunosuppressed Patient

Hong Sang Yoon¹, Byung Joon Jeon², Bo Young Park¹

¹Department of Plastic Surgery, Samsung Medical Center, Sungkyunkwan University School of Medicine, Seoul;

²Department of Plastic and Reconstructive Surgery, Ansan Hospital, Korea University College of Medicine, Ansan, Korea

Correspondence: Bo Young Park
Department of Plastic Surgery, Samsung Medical Center,
Sungkyunkwan University School of Medicine, 81 Irwon-ro, Gangnam-gu,
Seoul 135-710, Korea
Tel: +82-2-3410-2235, Fax: 82-2-3410-0036
E-mail: byps.park@samsung.com

No potential conflict of interest relevant to this article was reported.

Received: 14 Mar 2013 • Revised: 23 Apr 2013 • Accepted: 26 Apr 2013
pISSN: 2234-6163 • eISSN: 2234-6171
<http://dx.doi.org/10.5999/aps.2013.40.4.479> • Arch Plast Surg 2013;40:479-481

Copyright © 2013 The Korean Society of Plastic and Reconstructive Surgeons
This is an Open Access article distributed under the terms of the Creative Commons Attribution Non-Commercial License (<http://creativecommons.org/licenses/by-nc/3.0/>) which permits unrestricted non-commercial use, distribution, and reproduction in any medium, provided the original work is properly cited.

Most of the parasitic infections that occur in Far East Asia including China, Japan, and Korea result from ingestion of infected water or the raw flesh of snakes or frogs.

The most common clinical manifestation of sparganosis is a subcutaneous mass or lump in the breast, abdominal wall, scrotum, lower extremity, or chest wall. The larvae can invade tissues including muscle, intestine, eye, brain, and spinal cord and can also cause pericardial effusion. The mass may be mistaken for a malignant tumor, thereby causing difficulty in terms of diagnosis and treatment. In this article, we report an interesting case of sparganosis that presented as two separate subcutaneous masses involving the axillary and inguinal area in an immunosuppressed patient 45 years after the initial ingestion of contaminated food. A 61-year-old man visited our clinic with two 3 cm painless, movable, hard masses

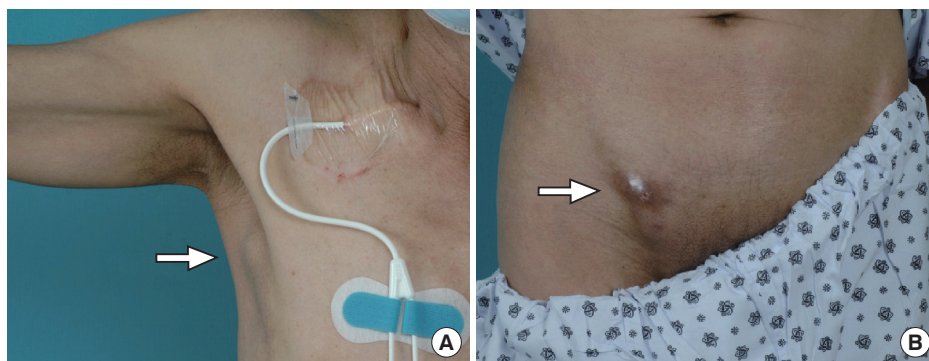


Fig. 1. Preoperative (A) right axillary, (B) inguinal masses (white arrow).

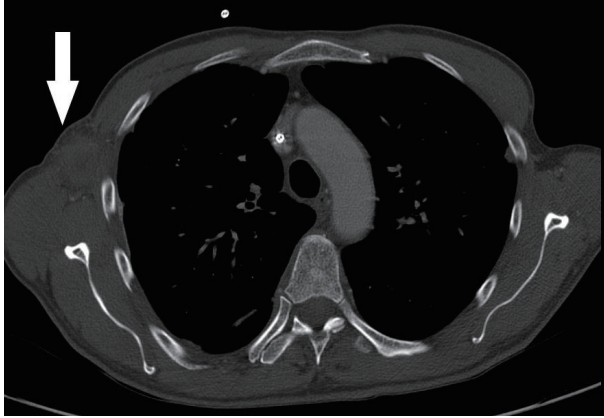


Fig. 2. Chest contrast computed tomography findings (white arrow). 5 cm × 3 cm × 2 cm mass indicative of sparganosis in the right axillary area.

in the right axilla and inguinal area (Fig. 1). He had a medical history of acute lymphoma and had received an allo-peripheral stem cell transplant (PBSCT) 1 week prior to visiting our clinic. Immunosuppressive therapy was maintained with cyclosporine after PBSCT. The masses in the inguinal and axillary regions were suddenly observed following PBSCT, and the size of the masses increased during the first week. Routine laboratory tests were unremarkable and no eosinophilia was noted. Computerized tomography showed two 5 cm × 3 cm × 2 cm round nodules located in the subcutaneous layer (Fig. 2). Recent results from a punch biopsy from the inguinal area revealed sparganosis and suggested the potential for axillary lymphadenopathy, which was also diagnosed by computerized tomography as sparganosis. The patient subsequently recalled that he had eaten the raw flesh of a snake about 45 years earlier, during his childhood.

During the operation, small elliptical incisions were made on the upper portion of each mass. White and shiny masses were observed through the incision and the well-demarcated hard masses were completely removed along with hard palpable lymph nodes around the masses. The histological examination confirmed sparganosis, showing degenerative parasitic organisms with chronic inflammation consisting of numerous eosinophils (Fig. 3). Spargana larvae were found within the masses and granulation tissue with endothelial enlargement was also observed (Fig. 4). No antihelminthic drug was used, and the postoperative course was uneventful. One year postoperatively, the patient had no symptoms and showed no signs of recurrence of any lesion. Sparganosis caused by the migrating proceroid

larvae of *Diphyllobothrium mansonii* is an extremely rare disease. The most common route of infection is via ingestion of contaminated water containing proceroids, which can penetrate into the intestine and migrate to the muscle or subcutaneous tissue [1]. The second route is from ingestion of raw or partially cooked fish, frogs, snakes, and chickens. Infection in this case also occurs from migration of the proceroid through the intestine. The third route of infection may occur from poultice application that may be infested with *Cyclops* containing proceroids that are utilized to open wounds or eyes.

Ingestion of the raw flesh of frogs or snakes is the most important infection route in East Asia. Interestingly, Korea experiences more frequent occurrences of sparganosis than any other Asian country.

Sparganosis manifests as a migrating subcutaneous nodule in the abdominal wall, breast, lower extremity, or scrotum [2-4]. The ingested spargana can invade various organs, such as the eye, subcutaneous tissues, abdominal wall, brain, spinal cord, lung, or breast [1-3]. In the case of the genitourinary system, the involvement of the epididymis, spermatic cord, penis, retroperitoneum, and ureter have been reported [2-4]. Patients with sparganosis present clinically with vague or indeterminate symptoms. Importantly, distinguishing sparganosis from malignancy remains a significant concern.

While the rate of sparganosis has decreased with economic development and advancements in sanitation, surgeons still encounter patients with sparganosis in the clinical setting. Furthermore, the most frequent infection route is also changing. Therefore, a careful history is required in order to diagnose sparganosis. A definite diagnosis of sparganosis can be performed by excisional biopsy. Utilizing magnetic resonance imaging or computed tomography reveals characteristic signs of sparganosis: a band-like structure with a coiled hypo-echoic body. However, these imaging studies provide limited evidence for making a diagnosis. In a recent article, screening using enzyme-linked immunosorbent assay from the serum was reported as a reasonable method for diagnosis with high sensitivity and specificity.

Sparganum larvae can penetrate anywhere in the body, where they can migrate anywhere, including subcutaneous tissue. When the sparganum is ingested, it penetrates the intestinal wall to reach the peritoneal cavity and begins to migrate systemically. The longevity of spargana is thought to be under 1 year. However, some articles have reported finding a live worm after

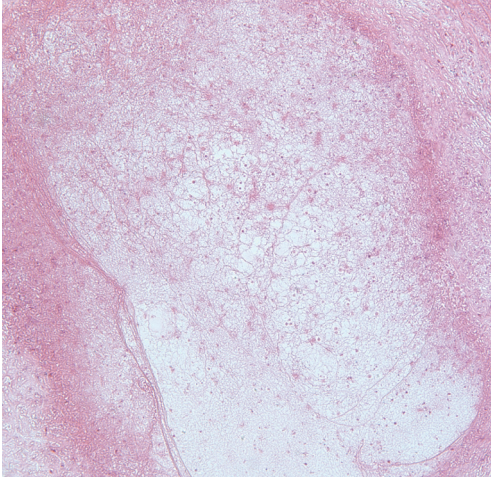


Fig. 3. Histologic findings of the right inguinal area. Degenerated larvae with chronic inflammation are shown (H&E, $\times 40$).

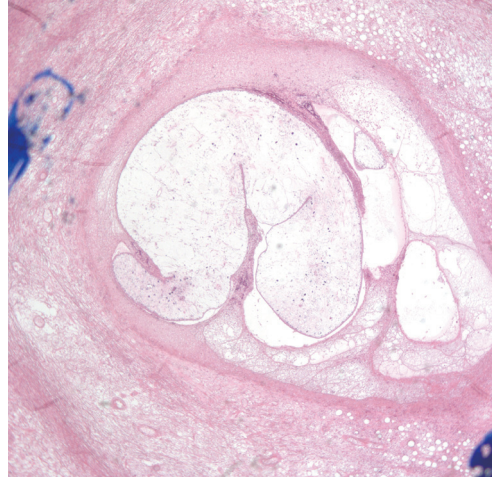


Fig. 4. Histologic findings of the right axillary area. Degenerated larvae with chronic inflammation are shown (H&E, $\times 40$).

more than 10 years. Kubota and Itoh [4] reported a case of orbital sparganosis with the patient suffering from a painful nodule after 10 years and Koo et al. [2] also reported a case that mimicked a varicose vein after 10 years. We experienced an interesting case of sparganosis that had been latent for 45 years without symptoms but manifested with subcutaneous nodules after immunosuppressive therapy. In this case, we concluded that the larvae were dead in the lymph nodes and the immunosuppressant therapy might have caused lymphadenopathy. Although the exact length of latency is not specific in most published articles, our case could be the longest known latent period of sparganosis. The long-term survival of the parasites could result from their immunomodulatory ability with respect to the host. Further research is required in order to understand the role of sparganum as a valuable model for alleviating symptoms of immune-mediated disease.

Human sparganosis is an extremely rare disease, even in endemic countries, and the clinical presentations are diverse, including non-specific pain, vague discomfort, palpable masses, headache, or symptoms related to the involved organs [5]. The infection route,

latent period, and symptoms of the disease are changing with economic development. Therefore, surgeons should be aware of the clinical characteristics in order to make a diagnosis. In this respect, a careful patient history is most important. In our case, we speculate that the longevity of spargana could have been up to 45 years with a parasitic infection occurring in two sites following a change in the patient's immune status.

References

1. Yun SJ, Park MS, Jeon HK, et al. A case of vesical and scrotal sparganosis presenting as a scrotal mass. *Korean J Parasitol* 2010;48:57-9.
2. Koo M, Kim JH, Kim JS, et al. Cases and literature review of breast sparganosis. *World J Surg* 2011;35:573-9.
3. Cho JH, Lee KB, Yong TS, et al. Subcutaneous and musculoskeletal sparganosis: imaging characteristics and pathologic correlation. *Skeletal Radiol* 2000;29:402-8.
4. Kubota T, Itoh M. Sparganosis associated with orbital myositis. *Jpn J Ophthalmol* 2007;51:311-2.
5. Sarukawa S, Kawanabe T, Yagasaki A, et al. Case of subcutaneous sparganosis: use of imaging in definitive preoperative diagnosis. *J Dermatol* 2007;34:654-7.