

is large and deep. In these cases, it is usually detected intraoperatively. However, smaller tears are detected during the postoperative period.

The exact site and size of the abovementioned laceration is determined by bronchoscopy; this knowledge helps in planning the therapeutic approach.

Nonoperative indications are stable vital signs, no difficulty ventilating while intubated or respiratory distress while extubated, no evidence of esophageal injury, minimal mediastinal fluid collection, nonprogressive pneumomediastinum or subcutaneous emphysema, and no signs of sepsis [5].

In our case, the tracheal laceration could have arisen after elective operation or uncomplicated intubation, as the patient had no underlying diseases. Her risk factors were only the head and neck surgery and her gender. These risk factors are common in patients who undergo operations in plastic surgery. We assume two possible causes in this case. First, potadine and bleeding could have irritated the trachea and triggered a cough and gag reflex. Secondly, repeated sterilization for reuse may have increased the stiffness of the intubation tube.

A plastic surgeon must be familiar with the causes and the symptoms of tracheal laceration. In particular, such a laceration could have occurred during a short operation such as a closed reduction of the nasal bone. For the prevention of tracheal laceration, we need to determine a patient's underlying disease. Further, plenty of irrigation is required for the removal of the potadine and blood before extubation.

References

- Gomez-Caro Andres A, Moradiellos Diez FJ, Ausin Herrero P, et al. Successful conservative management in iatrogenic tracheobronchial injury. *Ann Thorac Surg* 2005;79:1872-8.
- Harris R, Joseph A. Acute tracheal rupture related to endotracheal intubation: case report. *J Emerg Med* 2000;18:35-9.
- Kaloud H, Smolle-Juettner FM, Prause G, et al. Iatrogenic ruptures of the tracheobronchial tree. *Chest* 1997;112:774-8.
- Minambres E, Buron J, Ballesteros MA, et al. Tracheal rupture after endotracheal intubation: a literature systematic review. *Eur J Cardiothorac Surg* 2009;35:1056-62.
- Ross HM, Grant FJ, Wilson RS, et al. Nonoperative management of tracheal laceration during endotracheal intubation. *Ann Thorac Surg* 1997;63:240-2.

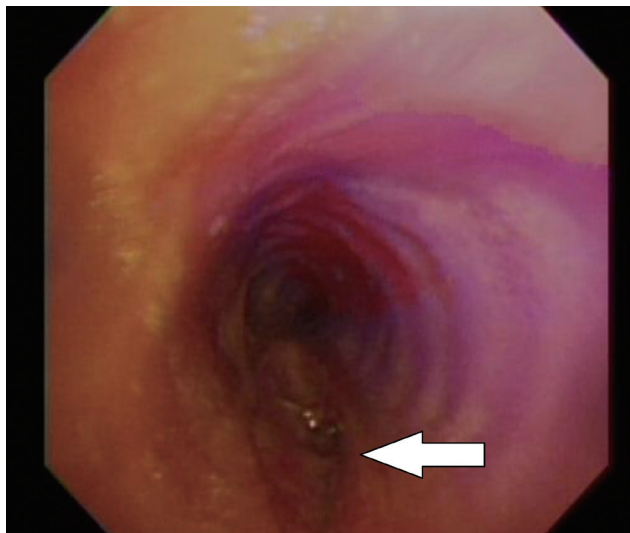


Fig. 2.

Diagnostic bronchoscopy. A lacerated wound (white arrow) can be observed above the carina. It is approximately 1.5 cm vertically and has split thickness.

Surgical Resection of Acquired Vulvar Lymphangioma Circumscriptum

Chan Kwon, Sang Hun Cho, Su Rak Eo

Department of Plastic and Reconstructive Surgery, Dongguk University School of Medicine, Goyang, Korea

Correspondence: Su Rak Eo
Department of Plastic and Reconstructive Surgery, Dongguk University Graduate School of Medicine, 27 Dongguk-ro, Ilsandong-gu, Goyang 410-773, Korea
Tel: +82-31-961-7330, FAX: +82-31-961-7347, E-mail: surakeo@yahoo.com

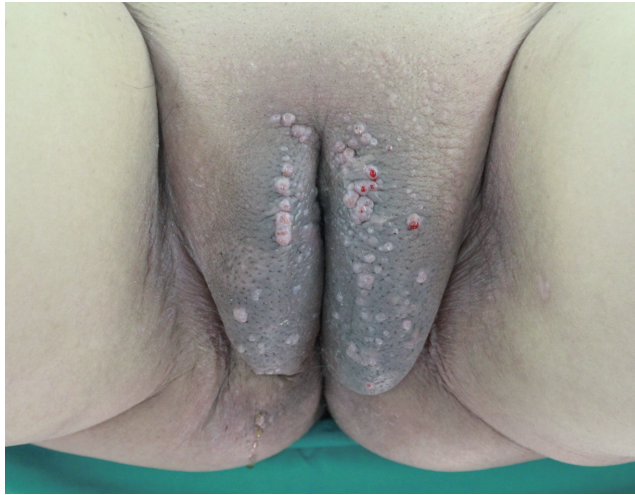This article was presented as a poster at the 70th Congress of the Korean Society of Plastic and Reconstructive Surgery on November 9–11, 2012 in Seoul, Korea.

No potential conflict of interest relevant to this article was reported.

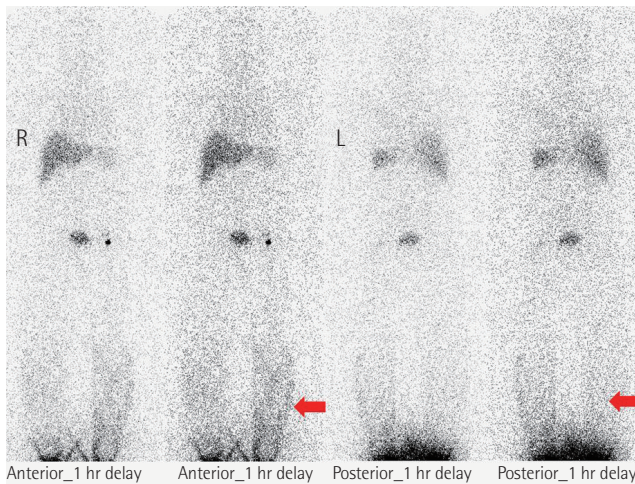
Received: 22 Jul 2013 • Revised: 5 Sep 2013 • Accepted: 20 Sep 2013
pISSN: 2234-6163 • eISSN: 2234-6171
<http://dx.doi.org/10.5999/aps.2014.41.2.183> • Arch Plast Surg 2014;41:183-186

Copyright © 2014 The Korean Society of Plastic and Reconstructive Surgeons
This is an Open Access article distributed under the terms of the Creative Commons Attribution Non-Commercial License (<http://creativecommons.org/licenses/by-nc/3.0/>) which permits unrestricted non-commercial use, distribution, and reproduction in any medium, provided the original work is properly cited.

The predominant types of lymphangioma are lymphangioma circumscriptum (LC), cavernous lymphangioma, cystic hygroma, and lymphangioendothelioma. These entities account for approximately 26% of benign vascular tumors in children but are rarer in adults [1]. LC is the most common form of cutaneous lymphangioma and is characterized by superficial lymphatic ducts protruding through the epidermis.

**Fig. 1.**

A 71-year-old female with bilateral vulvar lymphangioma circumscriptum.

**Fig. 2.**

Radioisotope lymphoscintigraphy showing dermal back flow (red arrows) of the lymphatics in both legs.

Whimster postulated that lymph sacs that are lined by muscle fibers contract and result in outpouching, which eventually causes skin protrusions to become what are clinically described as vesicles [2]. This condition results in clusters of clear fluid-filled vesicles resembling frog spawn and associated tissue edema. It is usually found on the proximal extremity, trunk, and axilla, which has an abundant lymphatic system, but rarely involves the vulva, penis, scrotum, gingiva, tongue, and even the conjunctiva. Vulvar LC is a debilitating condition, causing lymphedema, itching, eczema, oozing, sexual dysfunction, and infection. It is very rare and either a congenital or an acquired

condition following damage to previously normal lymphatics. Radical hysterectomy with subsequent radiotherapy appears to be the only recently recognized acquired risk factor. Although there are many other treatment modalities, surgery, particularly major labiectomy, has been reported to be the best treatment option for the potential of early rehabilitation and low recurrence. A 71-year-old female presented to our outpatient clinic with persistent edema of both lower limbs, clusters of pink labial papules, pruritus, and watery lymph oozing. Her condition had been deteriorating for 5 years without any treatment. These cutaneous symptoms began with a few vesicles 24 years after radical hysterectomy with adjuvant pelvic radiation therapy under the diagnosis of stage IIb squamous cell carcinoma of the cervix (Fig. 1). There was no history of sexually transmitted disease or gastrointestinal disease. Bilateral vulvar edema with vesicular skin eruption was found on colposcopy and a cervical smear showed normal findings. Radioisotope lymphoscintigraphy showed a decreased lymphatic uptake in the pelvis and the dermal back flow of lymphatics in both lower legs, which implied lymphatic obstruction (Fig. 2). Preoperative biopsy revealed probable cavernous lymphangioma. Surgery was performed under general anesthesia in the lithotomy position with a urinary catheter. We removed all the papules by performing bilateral major labiectomy down to the level of Colles' fascia, sparing the clitoris and fourchette (Fig. 3). The extent of the subcutaneous excision was determined by preoperative pelvic computed tomography and intraoperative findings such as wetness, presence of cysts, and fibrous components. After the excision, the wound was closed primarily. Surgical biopsy showed multiple dilated lymph vessels, which is a histological feature of LC. There was no endothelial swelling representing lymphangitis or a granulomatous reaction. The postoperative course was uneventful. There was a clear improvement in the symptoms such as oozing, itching, and rubbing by the time of follow-up at 6 months after surgery, yet further follow-up is considered necessary (Fig. 4). Vulvar LC is an uncommon entity with various clinical mimics like genital warts, herpes zoster, molluscum contagiosum, leiomyoma, and recurrent carcinoma. Further, this makes the biopsy of the lesion essential to differentiate various infective diseases and other tumors. Since the lesions may appear papillary upon histological analysis, a specific lymphatic endothelial marker such as D2-40 is necessary to reduce the diagnostic difficulty [3]. In our

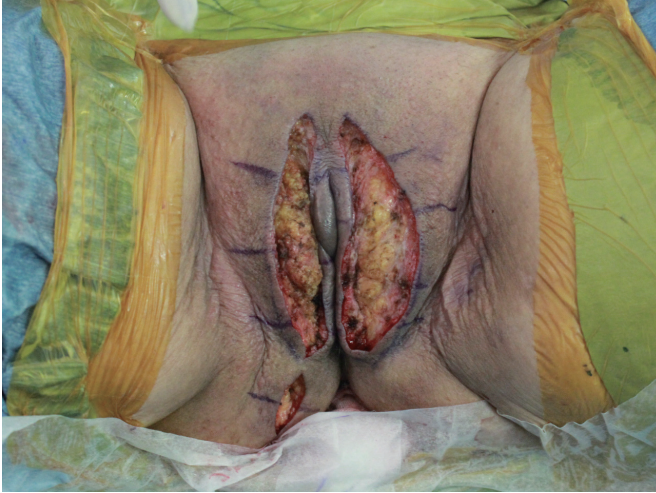

Fig. 3. Operation on bilateral vulvar lymphangioma circumscriptum with major labiectomy.

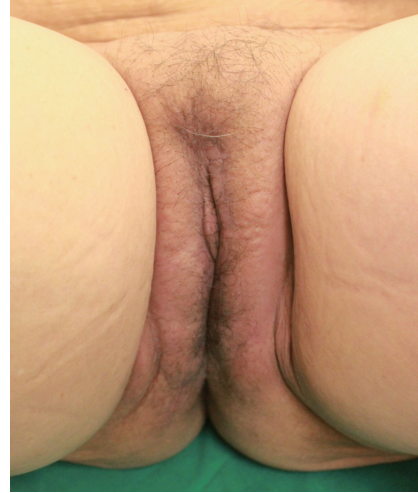

Fig. 4. Follow-up at 6 months after major labiectomy; no recurrence or adverse effects.

case, we used D2-40 stains as is and obtained positive findings (Fig. 5). When lymph nodes are affected, fluid formation exceeds the lymphatic transport capacity, and this makes the affected region more prone to infection and the consequent fibrosis. However, it is not known why most patients who have undergone regional node dissection do not develop lymphedema. Although radical hysterectomy with or without radiotherapy is believed to be the only recognized cause of LC, there are various other reported conditions that lead to LC, such as Crohn's disease, urogenital tuberculosis, bacterial infections, and non-gynecologic tumors. Thus, thorough patient history-taking is essential to identify factors suggesting this rare condition and prevent delay in treatment. Thus far, there is no definite treatment of choice for LC because the number of reported LC cases is too small to conclusively determine the best treatment modality. There are various non-surgical treatments ranging from conservative management with massage, exercise, compression, and sclerotherapy, to CO₂ laser therapy depending on the type and extent of LC. Recently, CO₂ laser therapy has been used often as the main alternative to surgery. However, in some cases, particularly in those with deep lesions, it caused pain and exacerbation of vesicles and vulvar keloid formation [4]. Unlike conservative treatment options, surgical management offers a more permanent solution. Although many other surgical treatment modalities, including the insertion of polythene tubes, lymphovenous anastomosis, and lymph angioplasties have been reported, labial reduction or excision of edematous tissue seems to show more

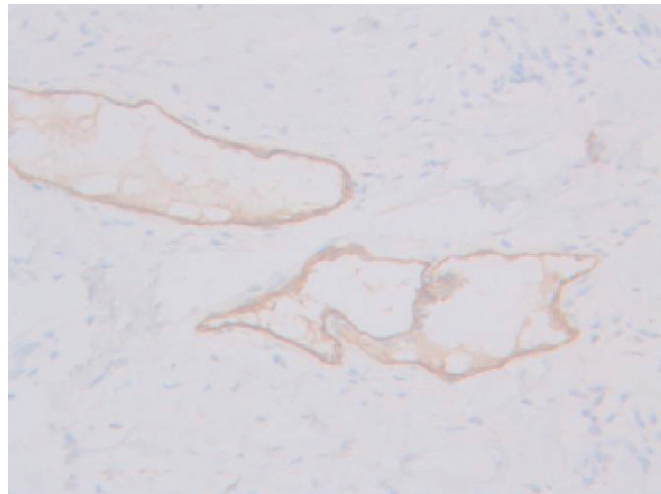


Fig. 5. D2-40 staining marking lymphatic endothelial cells lining the dilated intra-epidermal lymphatic space ($\times 200$).

promising results since it can be repeated as necessary until both the functional and the aesthetic goals are achieved. It is known that the size of the lesion also affects the surgical outcome and the recurrence rate. Browne et al. [5] reported a high recurrence rate after radical excision when the initial lesion was larger than 7 cm compared with a lesion less than 7 cm in size for which only a local excision was performed. However, in our case, no recurrence was found despite the fact that the lesion was approximately 9 cm \times 3 cm in size. We reported our experience of major labiectomy as the surgical management of LC in one patient who had remission with no recurrence. This might be just another

case report of surgical resection of LC, but because of a lack of cases, we believe that this report can contribute to finding the best modality for the management of LC.

References

1. Haroon S, Hasan SH. Lymphangioma circumscriptum in the scrotum: a case report. *J Med Case Rep* 2012;6:233.
2. Whimster IW. The pathology of lymphangioma circumscriptum. *Br J Dermatol* 1976;94:473-86.
3. Ikeda M, Muramatsu T, Shida M, et al. Surgical management of vulvar lymphangioma circumscriptum: two case reports. *Tokai J Exp Clin Med* 2011;36:17-20.
4. Ghaemmaghami F, Karimi Zarchi M, Mousavi A. Major labiaectomy as surgical management of vulvar lymphangioma circumscriptum: three cases and a review of the literature. *Arch Gynecol Obstet* 2008;278:57-60.
5. Browse NL, Whimster I, Stewart G, et al. Surgical management of 'lymphangioma circumscriptum'. *Br J Surg* 1986;73:585-8.

An Unexpected Complication after Periorbital Tumor Surgery in a Patient Later Discovered to Have Myelodysplasia

Süleyman Taş, Hüsamettin Top

Department of Plastic, Reconstructive and Aesthetic Surgery
Trakya University Medicine Faculty, Edirne, Turkey

Correspondence: Süleyman Taş
Department of Plastic, Reconstructive and Aesthetic Surgery,
Trakya University Medicine Faculty, Edirne 22030, Turkey
Tel: +90-284-235-7641, Fax: +90-284-235-3451
Email: drsuleymantas@live.com

No potential conflict of interest relevant to this article was reported.

Received: 27 May 2013 • Revised: 30 Jun 2013 • Accepted: 9 Jul 2013
pISSN: 2234-6163 • eISSN: 2234-6171
<http://dx.doi.org/10.5999/aps.2014.41.2.186> • *Arch Plast Surg* 2014;41:186-187

Copyright © 2014 The Korean Society of Plastic and Reconstructive Surgeons
This is an Open Access article distributed under the terms of the Creative Commons Attribution Non-Commercial License (<http://creativecommons.org/licenses/by-nc/3.0/>) which permits unrestricted non-commercial use, distribution, and reproduction in any medium, provided the original work is properly cited.

The myelodysplastic syndromes (MDS) comprise a complex group of stem cell disorders that involve the ineffective production of one or more of the myeloid

class of blood cells. Patients with myelodysplasia often develop severe anemia and require frequent blood transfusions. One-third of these patients have a risk of developing acute myelogenous leukemia, usually within a few months to years of developing MDS. Thrombocytopenia is a common feature of MDS in which platelets mature abnormally. Bleeding in these patients is generally due to thrombocytopenia or intrinsic platelet dysfunction. The size, shape, and granulation of platelets are variable. Platelet aggregation is also impaired. The incidence of MDS is approximately 1 case per 1,000 people per year in patients who are more than 80 years old [1].

We encountered a case of a 94-year-old who presented with basal cell carcinoma (BCC) of the right medial canthus with a normal hematologic work-up and history (Fig. 1A). The preoperative hematologic work-up included a complete blood count, activated partial thromboplastin time, and prothrombin time. The patient had the current lesion for 3 years, and the lesion had been diagnosed as BCC with incisional biopsy 1 month before. She underwent excision with a wide margin (at least 5 mm of skin clearance) and full thickness, and immediate reconstruction with a forehead flap. Hemostasis was meticulously performed during the procedure. Within 4 hours of the operation, exaggerated ecchymosis, edema, and hematoma under the flap were observed (Fig. 1B). The hematoma was drained immediately, and the hematologic work-up was evaluated and detected to be above the minimum threshold. The bleeding time was prolonged (more than 10 minutes) clinically. A hematology consultation was requested, and the recommendations were performed. Based on a peripheral blood smear, MDS was diagnosed for the first time. Thirty units of platelet suspensions were given until the bleeding time reached the normal level (Table 1). Daily blood tests were repeated for 2 weeks postoperatively, and the signs and symptoms of bleeding and wound complications were observed closely. At the 3-week follow-up, the flap and the wound had a satisfactory appearance and had healed uneventfully, and the patient had no further bleeding episodes (Fig. 1C).

Clotting disorders are an important cause of flap failure in reconstructive surgery. In patients with thrombocytopenia or an increased bleeding tendency, postoperative flap complications are well known [2,3]. The existing literature lacks reports of MDS patients undergoing reconstructive surgery, with only one report mentioning this clinical scenario. Murphy et al. [4] reported reconstruction of an extensive periorbital