

case report of surgical resection of LC, but because of a lack of cases, we believe that this report can contribute to finding the best modality for the management of LC.

References

1. Haroon S, Hasan SH. Lymphangioma circumscriptum in the scrotum: a case report. *J Med Case Rep* 2012;6:233.
2. Whimster IW. The pathology of lymphangioma circumscriptum. *Br J Dermatol* 1976;94:473-86.
3. Ikeda M, Muramatsu T, Shida M, et al. Surgical management of vulvar lymphangioma circumscriptum: two case reports. *Tokai J Exp Clin Med* 2011;36:17-20.
4. Ghaemmaghami F, Karimi Zarchi M, Mousavi A. Major labiaectomy as surgical management of vulvar lymphangioma circumscriptum: three cases and a review of the literature. *Arch Gynecol Obstet* 2008;278:57-60.
5. Browse NL, Whimster I, Stewart G, et al. Surgical management of 'lymphangioma circumscriptum'. *Br J Surg* 1986;73:585-8.

An Unexpected Complication after Periorbital Tumor Surgery in a Patient Later Discovered to Have Myelodysplasia

Süleyman Taş, Hüsamettin Top

*Department of Plastic, Reconstructive and Aesthetic Surgery
Trakya University Medicine Faculty, Edirne, Turkey*

Correspondence: Süleyman Taş
Department of Plastic, Reconstructive and Aesthetic Surgery,
Trakya University Medicine Faculty, Edirne 22030, Turkey
Tel: +90-284-235-7641, Fax: +90-284-235-3451
Email: drsuleymantas@live.com

No potential conflict of interest relevant to this article was reported.

Received: 27 May 2013 • Revised: 30 Jun 2013 • Accepted: 9 Jul 2013
pISSN: 2234-6163 • eISSN: 2234-6171
<http://dx.doi.org/10.5999/aps.2014.41.2.186> • Arch Plast Surg 2014;41:186-187

Copyright © 2014 The Korean Society of Plastic and Reconstructive Surgeons
This is an Open Access article distributed under the terms of the Creative Commons Attribution Non-Commercial License (<http://creativecommons.org/licenses/by-nc/3.0/>) which permits unrestricted non-commercial use, distribution, and reproduction in any medium, provided the original work is properly cited.

The myelodysplastic syndromes (MDS) comprise a complex group of stem cell disorders that involve the ineffective production of one or more of the myeloid

class of blood cells. Patients with myelodysplasia often develop severe anemia and require frequent blood transfusions. One-third of these patients have a risk of developing acute myelogenous leukemia, usually within a few months to years of developing MDS. Thrombocytopenia is a common feature of MDS in which platelets mature abnormally. Bleeding in these patients is generally due to thrombocytopenia or intrinsic platelet dysfunction. The size, shape, and granulation of platelets are variable. Platelet aggregation is also impaired. The incidence of MDS is approximately 1 case per 1,000 people per year in patients who are more than 80 years old [1].

We encountered a case of a 94-year-old who presented with basal cell carcinoma (BCC) of the right medial canthus with a normal hematologic work-up and history (Fig. 1A). The preoperative hematologic work-up included a complete blood count, activated partial thromboplastin time, and prothrombin time. The patient had the current lesion for 3 years, and the lesion had been diagnosed as BCC with incisional biopsy 1 month before. She underwent excision with a wide margin (at least 5 mm of skin clearance) and full thickness, and immediate reconstruction with a forehead flap. Hemostasis was meticulously performed during the procedure. Within 4 hours of the operation, exaggerated ecchymosis, edema, and hematoma under the flap were observed (Fig. 1B). The hematoma was drained immediately, and the hematologic work-up was evaluated and detected to be above the minimum threshold. The bleeding time was prolonged (more than 10 minutes) clinically. A hematology consultation was requested, and the recommendations were performed. Based on a peripheral blood smear, MDS was diagnosed for the first time. Thirty units of platelet suspensions were given until the bleeding time reached the normal level (Table 1). Daily blood tests were repeated for 2 weeks postoperatively, and the signs and symptoms of bleeding and wound complications were observed closely. At the 3-week follow-up, the flap and the wound had a satisfactory appearance and had healed uneventfully, and the patient had no further bleeding episodes (Fig. 1C).

Clotting disorders are an important cause of flap failure in reconstructive surgery. In patients with thrombocytopenia or an increased bleeding tendency, postoperative flap complications are well known [2,3]. The existing literature lacks reports of MDS patients undergoing reconstructive surgery, with only one report mentioning this clinical scenario. Murphy et al. [4] reported reconstruction of an extensive periorbital

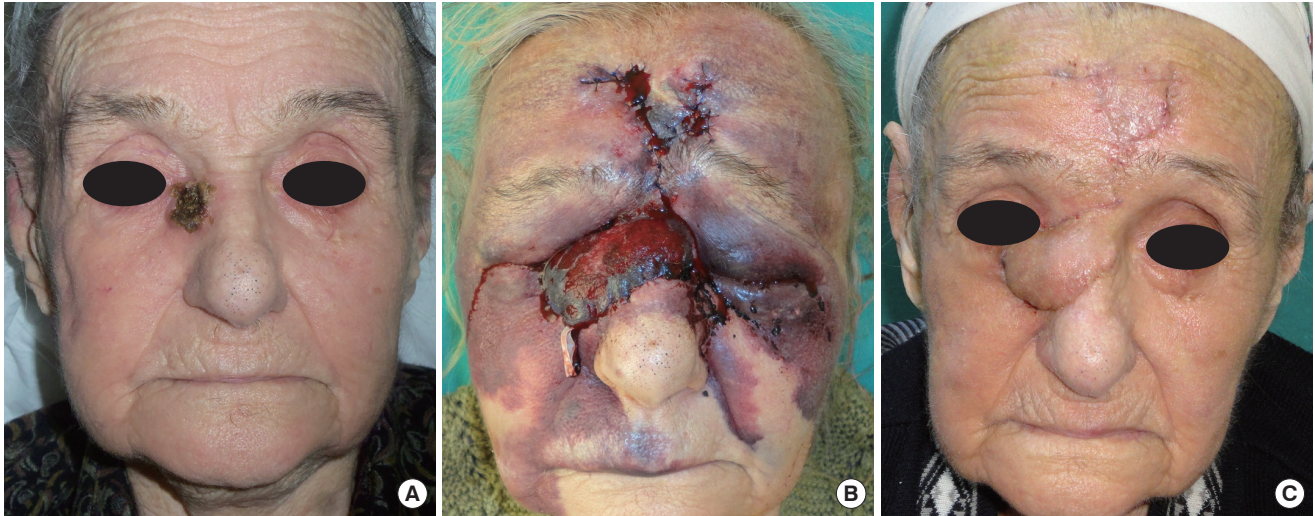


Fig. 1. Views preoperatively (A), 4 hours postoperatively (B), and at 3-week follow-up (C).

defect secondary to mucormycosis by free flap in a patient with previously diagnosed MDS. In this case, thrombocytopenia was controlled with thromboelastography (TEG). They concluded that the low platelet count implied a high complication rate. However, our case had normal platelet levels and underwent a minor intervention; this demonstrates that platelet dysfunction should be kept in mind in MDS treatment. In addition, this clinical scenario makes it difficult to diagnose MDS because a preoperative blood test cannot detect platelet dysfunction. It can only be determined by bleeding time test, thromboelastometry (TEM), and TEG, but these are not among the routine preoperative tests [5]. The authors suggest that in older patients, prior to surgery, a simple bleeding time test should be performed, even if the results of the laboratory tests are within the baseline values. If MDS is suspected, a hematology consultation and peripheral blood smear should be requested to search for MDS, or viscoelastic whole-blood assays such as TEM and TEG should be performed if possible, regardless of the size of the surgical intervention. Thus, the bleeding complications can be avoided, and the number of blood transfusions can be reduced. Nevertheless, if there is no possibility of TEG, a close monitoring of the bleeding time for detecting the amount of transfusion is still helpful.

Lack of experience can disrupt the provision of an optimal treatment plan for MDS patients. Upon the recommendation of hematologists, frequent platelet transfusions were given and a satisfactory outcome was achieved. This report proves the importance of

Table 1. A summary of the clinical situation in accordance with bleeding time and platelet level

Blood count	Preoperative	Postoperative	Posttransfusion
Platelet level (per mm ³)	107 × 10 ³	105 × 10 ³	150 × 10 ³
Bleeding time (min)	Not studied	> 10	3

closely monitoring the bleeding time and bleeding tendencies in these patients after surgery.

References

1. Kasner MT, Luger SM. Update on the therapy for myelodysplastic syndrome. *Am J Hematol* 2009;84:177-86.
2. Ozkan O, Chen HC, Mardini S, et al. Microvascular free tissue transfer in patients with hematological disorders. *Plast Reconstr Surg* 2006;118:936-44.
3. Herold C, Gohritz A, Meyer-Marcotty M, et al. Is there an association between comorbidities and the outcome of microvascular free tissue transfer? *J Reconstr Microsurg* 2011;27:127-32.
4. Murphy AD, Williamson PA, Vesely M. Reconstruction of an extensive peri-orbital defect secondary to mucormycosis in a patient with myelodysplasia. *J Plast Reconstr Aesthet Surg* 2013;66:e69-71.
5. National Collaborating Centre for Acute Care (UK). Preoperative tests: the use of routine preoperative tests for elective surgery [Internet]. London: National Collaborating Centre for Acute Care (UK); 2003 [cited 2013 Dec 23]. Available from: <http://www.nice.org.uk/nicemedia/live/10920/29094/29094.pdf>.