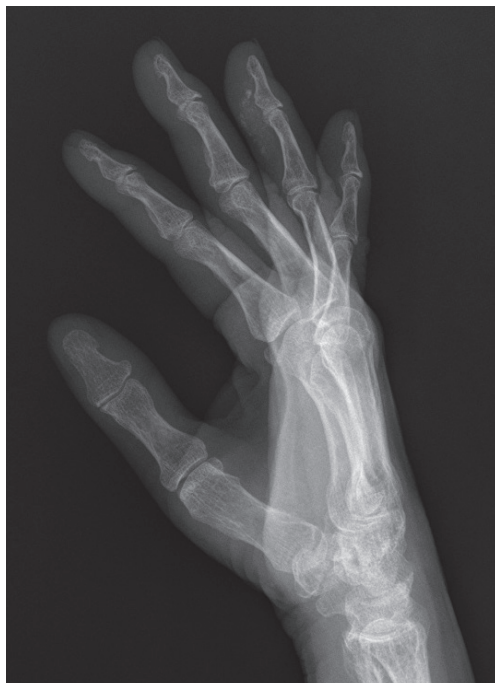



**Fig. 4.** Follow-up radiographic findings after two months showed the spontaneous resolution of the calcification.

appearance of the calcification had become mottled (Fig. 3), and the patient's C-reactive protein level decreased gradually. After one week of treatment, the patient experienced a complete resolution of pain and exhibited a full range of motion without difficulty. Follow-up radiographic findings after two months showed spontaneous resolution of the calcification (Fig. 4) [5].

Acute calcific tendinitis of the DIP joint is a rare condition, and, to the best of our knowledge, has not previously been reported in this anatomical location. Careful attention to the history of the patient and simple radiography helped us to diagnose this case of acute calcific tendinitis correctly. Misdiagnosis of this disease can lead to unnecessary surgical treatment and delay symptom relief. Based on reports of this condition in other regions, such as the shoulder, elbow, and wrist, conservative management with NSAIDs and a local injection of an anesthetic agent and a corticosteroid were able to relieve the symptoms dramatically in our patient. In light of our experience, acute calcific tendinitis of the hand should be considered as part of the differential diagnosis of a painful finger joint.

## References

1. Dilley DF, Tonkin MA. Acute calcific tendinitis in the hand and wrist. *J Hand Surg Br* 1991;16:215-6.
2. Harris AR, McNamara TR, Brault JS, et al. An unusual presentation of acute calcific tendinitis in the hand. *Hand (N Y)* 2009;4:81-3.
3. Shields JS, Chhabra AB, Pannunzio ME. Acute calcific tendinitis of the hand: 2 case reports involving the abductor pollicis brevis. *Am J Orthop (Belle Mead NJ)* 2007;36:605-7.
4. Lee HO, Lee YH, Mun SH, et al. Calcific tendinitis of the hand and foot: a report of four cases. *J Korean Soc Magn Reson Med* 2012;16:177-83.
5. Holt PD, Keats TE. Calcific tendinitis: a review of the usual and unusual. *Skeletal Radiol* 1993;22:1-9.

## Multiple Epidermal Cysts in the Volar Skin of the Thumb

Hong Jin Kim, Sung Hoon Koh, Sung Won Jung, Jihoon Yang, Hyoseob Lim

*Department of Plastic and Reconstructive Surgery, Hallym University Sacred Heart Hospital, Hallym University College of Medicine, Anyang, Korea*

**Correspondence:** Hyoseob Lim  
Department of Plastic and Reconstructive Surgery, Hallym University Sacred Heart Hospital, Hallym University College of Medicine, 22 Gwanpyeong-ro 170beon-gil, Dongan-gu, Anyang 14068, Korea  
Tel: +82-31-380-3781, Fax: +82-31-380-3783  
E-mail: hyoseob.lim@gmail.com

No potential conflict of interest relevant to this article was reported.

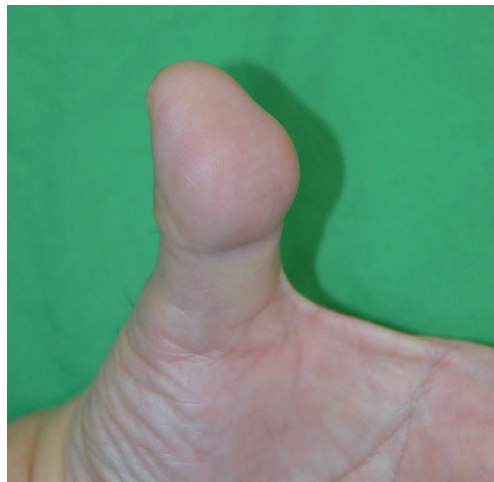Received: 27 Aug 2015 • Revised: 25 Dec 2015 • Accepted: 4 Jan 2016  
pISSN: 2234-6163 • eISSN: 2234-6171  
<http://dx.doi.org/10.5999/aps.2016.43.3.303>  
*Arch Plast Surg* 2016;43:303-305

Copyright © 2016 The Korean Society of Plastic and Reconstructive Surgeons  
This is an Open Access article distributed under the terms of the Creative Commons Attribution Non-Commercial License (<http://creativecommons.org/licenses/by-nc/4.0/>) which permits unrestricted non-commercial use, distribution, and reproduction in any medium, provided the original work is properly cited.

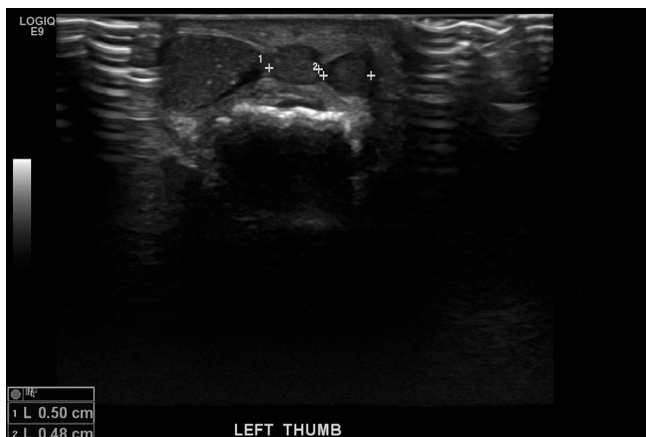Epidermal cysts most commonly occur in hair-bearing areas, such as the scalp, face, neck, trunk, and scrotum, where many pilosebaceous glands are present [1,2]. Epidermal cysts do not commonly develop in the palmoplantar skin due to the absence of pilosebaceous glands. The etiology of epidermal cysts on the palms and soles may not involve inflammation of the hair follicle, but the traumatic implantation of epidermal elements [1,3]. In this report, we describe a case of multiple epidermal cysts

that developed in the volar skin of the thumb.

A 53-year-old man visited our outpatient plastic surgery clinic, presenting with a slow-growing protruding mass on the left thumb (Fig. 1). He was a carpenter by occupation, and the mass developed after recurrent mechanical trauma by hammering for several decades. The 2.5 × 2-cm mass was located on the volar side of the distal phalanx of the left thumb. Upon physical examination, the mass was movable, without tenderness, redness, or a sense of warmth. We performed a simple X-ray of the hand to evaluate potential bony abnormalities and ultrasonography to determine the characteristics of the mass. The simple X-ray showed a normal bony appearance without bony erosion due to mass effect. We also found three subcutaneous low echoic masses on ultrasonography (Fig. 2). The overlying skin was incised horizontally



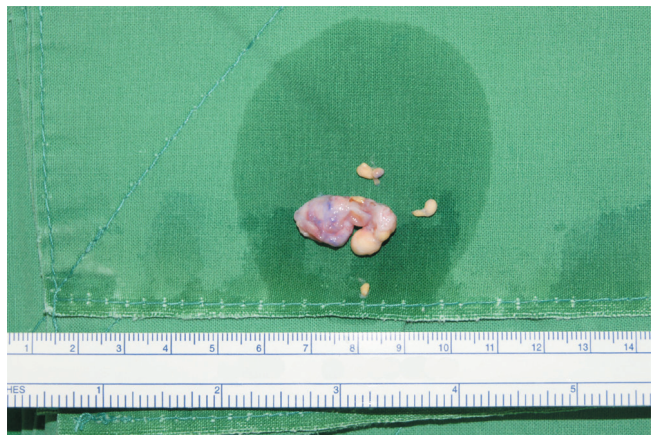**Fig. 1.**  
A 2.5 × 2-cm protruding subcutaneous mass on the left thumb without an abnormal skin lesion.



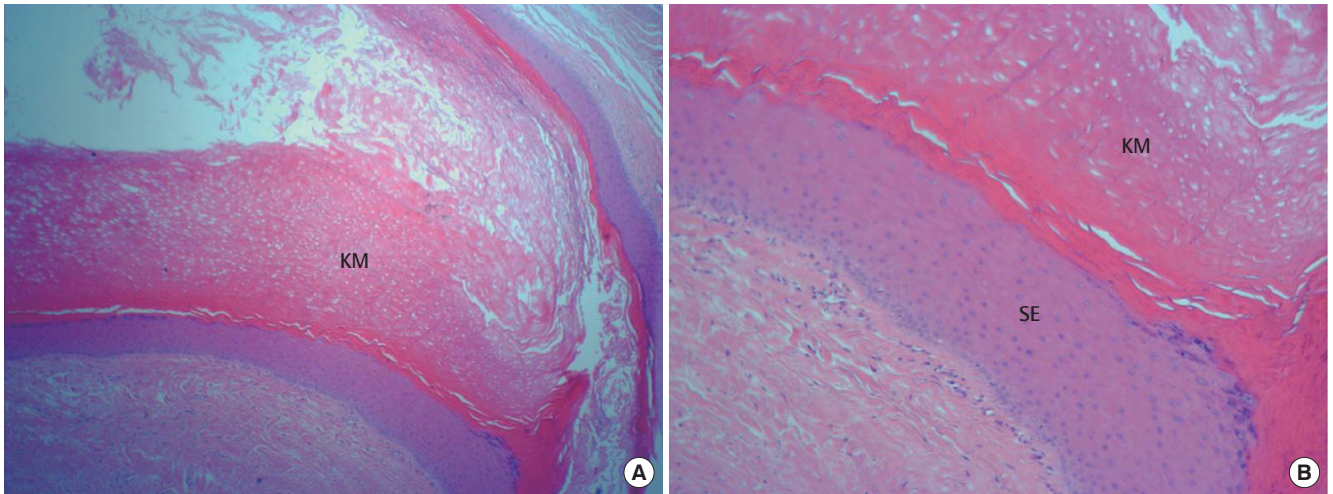
**Fig. 2.**  
Three lobulated heterogeneous hypoechoic masses were seen on ultrasonography. The size of the largest mass was 1.3 × 0.6 × 1.2 cm and the other two small masses measured 0.5 × 0.5 cm each.

and four masses were resected (Fig. 3). Mild adhesion was noted between the masses and the surrounding tissue, which was completely resected. The light microscopic examination of hematoxylin-eosin-stained sections was performed for all masses, which were diagnosed as epidermal cysts by a pathologist (Fig. 4). The wound was closed directly and followed up for two weeks. No complications, such as dehiscence, necrosis, hematoma, tingling sensation or hypoesthesia, or motility dysfunction occurred.

Epidermal cysts usually result from inflammation around pilosebaceous follicles [4]. However, no pilosebaceous follicles are present in the skin of the palm and the sole of the foot. Epidermal cysts in the palmoplantar skin have been assumed to result from the implantation of epidermal fragments due to a penetrating injury or another form of epidermal trauma [1,5]. Recently, some palmoplantar epidermal cysts have been reported to be caused by human papilloma virus (HPV) infection [4,5]. The pathophysiology of the epidermal cyst in this patient was presumed to be the implantation of an epidermal fragment, since the patient in this case had a history of recurrent occupational mechanical trauma [1,3]. We did not test for HPV infection because the patient did not present any symptoms or signs thereof. Epidermal cysts in the palmoplantar skin are easily confused with warts or calluses. Surgeons should be aware of the possibility of epidermal cysts in palmoplantar skin and be able to diagnose them correctly and design an appropriate treatment strategy.



**Fig. 3.**  
During the operation, a total of four masses were removed without any remnants.



**Fig. 4.** A postoperative biopsy showed keratin material (KM) surrounded by stratified squamous epithelium (SE) and a granular cell layer adjacent to the keratin-containing cyst lumen. The result was compatible with an epidermal cyst. H&E stain. (A)  $\times 40$ . (B)  $\times 100$ .

## References

1. Shimizu Y, Sakita K, Arai E, et al. Clinicopathologic features of epidermal cysts of the sole: comparison with traditional epidermal cysts and trichilemmal cysts. *J Cutan Pathol* 2005;32:280-5.
2. Vergles D, Horzic M, Cupurdija K, et al. Epidermoid cyst on top of the left arm thumb. *Am J Dermatopathol* 2009;31:723-4.
3. Fisher BK, Macpherson M. Epidermoid cyst of the sole. *J Am Acad Dermatol* 1986;15:1127-9.
4. Haga T, Okuyama R, Tagami H, et al. Demonstration of human papillomavirus type 60 in an epidermoid cyst developing in the finger pulp of the thumb. *Dermatology* 2005;211:296-7.
5. Lee KM, Park JH, Min KH, et al. Epidermal cyst on the sole. *Arch Plast Surg* 2013;40:475-6.