

**IMAGES****A child with type I ulnar ray deficiency**

Gyu Hyeong Lee, Ja Hea Gu

*Department of Plastic Surgery, Dankook University Hospital, Cheonan, Korea***Correspondence:** Ja Hea GuDepartment of Plastic Surgery, Dankook University Hospital, 201 Manghyang-ro, Dongnam-gu, Cheonan 31116, Korea  
Tel: +82-41-550-3873, Fax: +82-41-554-6477  
E-mail: jaheagu@gmail.com

This article was presented as a poster at the Federation of European Societies for Surgery of the Hand meeting on June 22–25, 2016, in Santander, Spain.

Received: 14 Feb 2017 • Revised: 27 Jul 2017 • Accepted: 22 Aug 2017

pISSN: 2234-6163 • eISSN: 2234-6171

<https://doi.org/10.5999/aps.2017.00234>

Arch Plast Surg 2018;45:191-193

Copyright © 2018 The Korean Society of Plastic and Reconstructive Surgeons  
This is an Open Access article distributed under the terms of the Creative Commons Attribution Non-Commercial License (<http://creativecommons.org/licenses/by-nc/4.0/>) which permits unrestricted non-commercial use, distribution, and reproduction in any medium, provided the original work is properly cited.

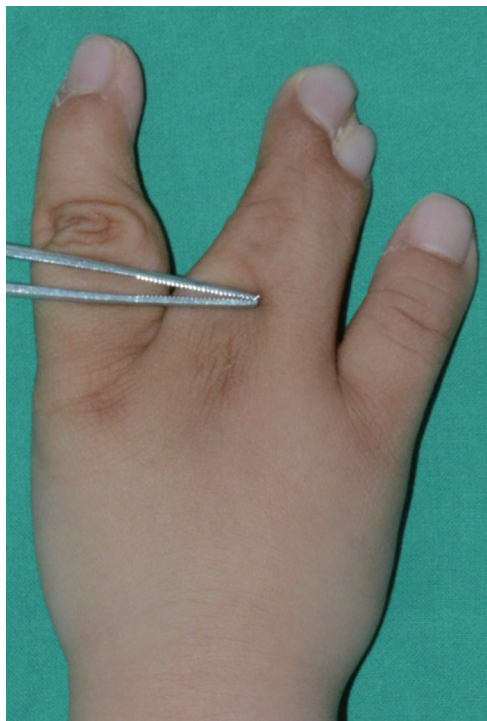Ulnar ray deficiency is the least common type of congenital longitudinal deficiency, and it shows several distinct manifestations, including various finger deformities [1].

To date, no reports have been published describing ulnar ray deficiency with multiple finger deformities, including central polysyndactyly, ectrodactyly, and first-web space narrowing. We describe the case of a patient with type I multiple-finger deformities.

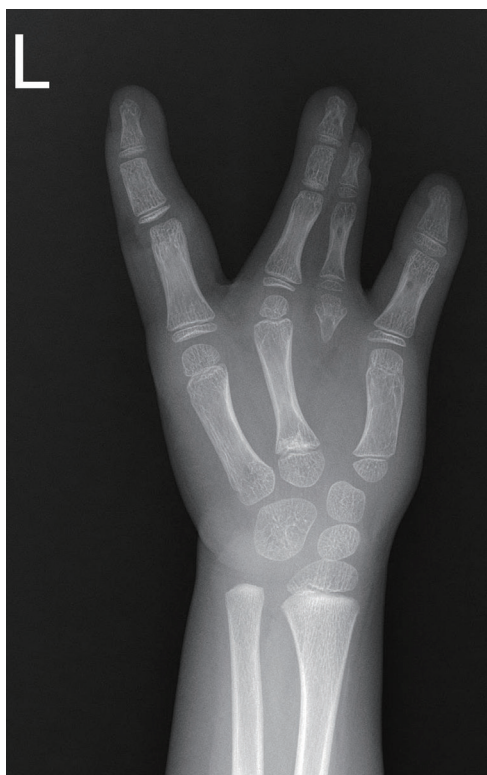A 6-year-old girl had a shorter left arm and 3 digits, with central polysyndactyly on her left hand (Fig. 1). The radiographic findings are presented in Fig. 2. The extra digit interfered with her ability to grasp and pinch, and she was only able to use the thumb and middle finger for these purposes. Therefore, excision of the non-functional index finger was performed, and the web space was reconstructed to improve the range of motion (Figs. 3, 4).

At 1 year postoperatively, her index finger still had limitations of motion and joint function, and power had not recovered. She usually used her thumb and middle finger to grab, pinch, and grip (Fig. 5).

Although the appropriate treatment of ulnar ray deficiency is not clear-cut, previous studies have emphasized the importance of operating upon hand deformities to improve functionality, and it has been stated that syndactyly should be released between 6 and 12 months of life [2,3]. In this case, the patient's index finger did not have normal anatomy, and the operation was delayed until 6 years of age. At that

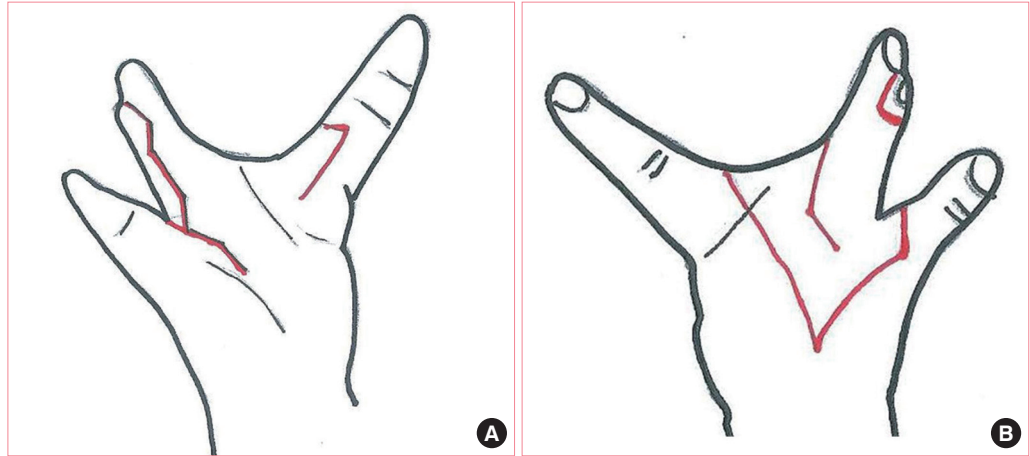


**Fig. 1.** Clinical photograph of the left hand. The index finger was present in the form of central polysyndactyly, and the ring and little fingers were absent.

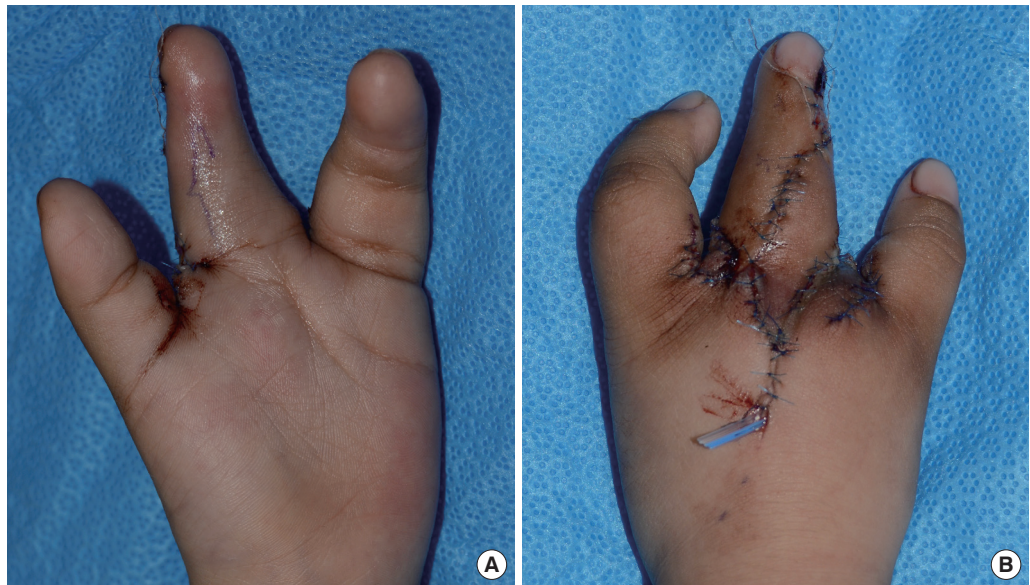


**Fig. 2.** Radiograph of the left extremities. The supernumerary digit on the index finger had a short proximal and distal phalanx and only the head of the metacarpal bone. The hamate, pisiform, triquetrum, and lunate were absent.

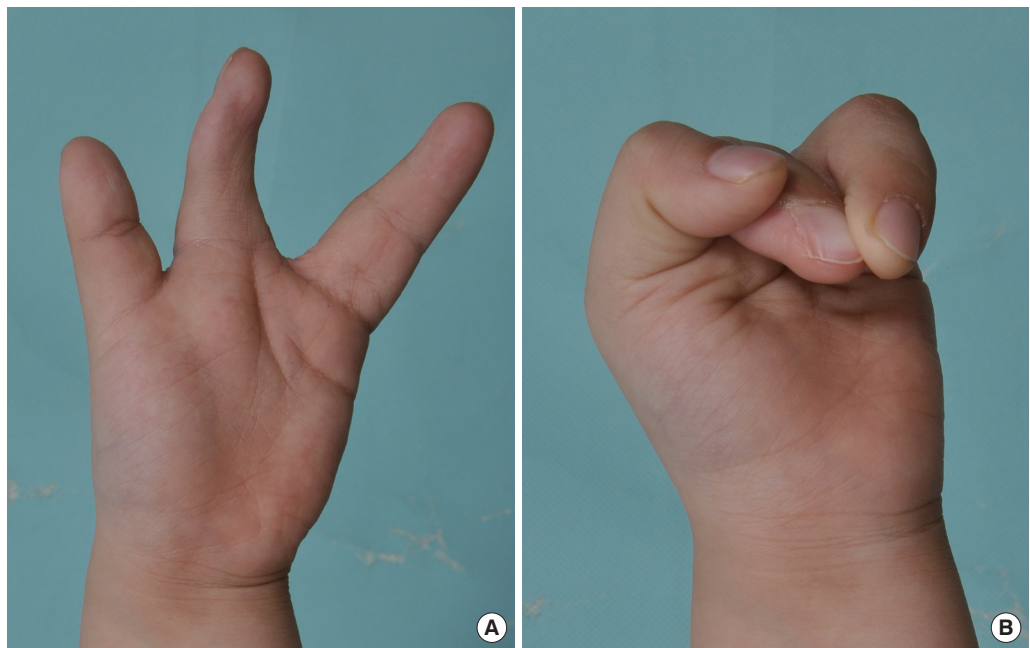
time, it could be conducted in a way that would not affect her finger movement. Based on this case, the timing of surgical treatment of complicated hand deformities should be planned carefully in order to maximize function.



**Fig. 3.**  
Operative design for reconstruction of web space and correction of syndactyly.



**Fig. 4.**  
Findings at 1 day postoperatively. (A) Palmar side and (B) dorsal side.



**Fig. 5.**  
Findings at 1 year postoperatively. (A) Resting position and (B) grasping position.

## Notes

### Conflict of interest

No potential conflict of interest relevant to this article was reported.

### Ethical approval

The study was performed in accordance with the principles of the Declaration of Helsinki. Written informed consent was obtained.

### Patient consent

The patients provided written informed consent for the publication and the use of their images.

## References

1. Malik S, Afzal M. Ulnar aplasia, dysplastic radius and paraxial oligodactyly: rare longitudinal limb defect in a sporadic male child. *J Res Med Sci* 2013;18:818-21.
2. Christopher CS, Neufeld SK. Ulnar ray deficiency. *Hand Clinics* 1998;14:65-75.
3. Broudy AS, Smith RJ. Deformities of the hand and wrist with ulna deficiency. *J Hand Surg Am* 1979;4:304-15.

## Early definitive treatment of partial-thickness alkali burns with tangential excision and biobrane

Yee Onn Kok<sup>1</sup>, Si Jack Chong<sup>1</sup>, Adi Basuki<sup>2</sup>, Bien Keem Tan<sup>1</sup>

<sup>1</sup>Department of Plastics, Reconstructive and Aesthetic Surgery, Singapore General Hospital, Singapore; <sup>2</sup>Faculty of Medicine, Universitas Indonesia, Jakarta, Indonesia

**Correspondence:** Yee Onn Kok  
Department of Plastics, Reconstructive and Aesthetic Surgery, Singapore General Hospital, Outram road, Singapore  
Tel: +6590065798, Fax: +62740094  
E-mail: kokyeonn@gmail.com

Received: 14 Mar 2017 • Revised: 17 Jul 2017 • Accepted: 5 Sep 2017  
pISSN: 2234-6163 • eISSN: 2234-6171  
<https://doi.org/10.5999/aps.2017.00507>  
*Arch Plast Surg* 2018;45:193-195

Copyright © 2018 The Korean Society of Plastic and Reconstructive Surgeons  
This is an Open Access article distributed under the terms of the Creative Commons Attribution Non-Commercial License (<http://creativecommons.org/licenses/by-nc/4.0/>) which permits unrestricted non-commercial use, distribution, and reproduction in any medium, provided the original work is properly cited.

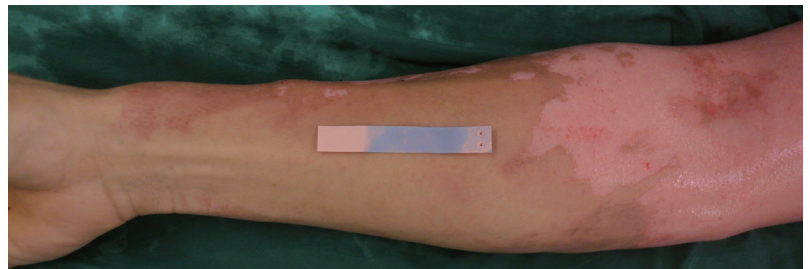
Copious irrigation, early tangential excision, and dressing are standard treatments for alkali burns [1]. Biobrane is a biosynthetic dressing widely used for partial-thickness burns. However, its use to treat alkali burns has rarely been discussed in the literature.

A 34-year-old male suffered a partial-thickness alkali burn caused by accidental paint solvent spillage (Taxite 4000, pH 10) over his face, neck, chest, and hand (11% of total body surface area). Immediate hourly copious irrigation was commenced before a same-day operative scrubdown.

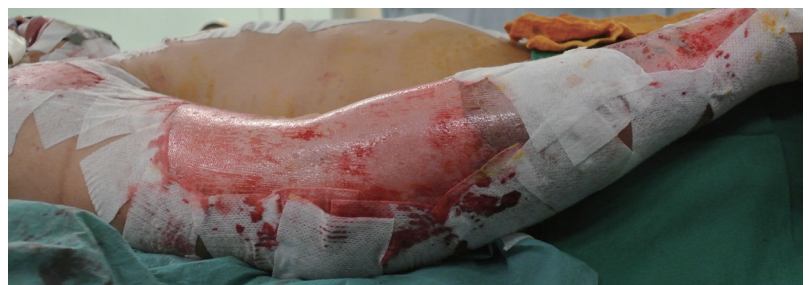After intraoperative irrigation and scrubbing with neutralizing chlorhexidine gluconate 4% liquid soap (pH 5.0–6.5), only the upper limbs were still alkaline (Fig. 1). Hence, we proceeded with ultra-thin tangential excision and debridement over the right upper limb until a litmus test indicated a neutral pH.

Biobrane was applied onto the dry clot-free wound bed with sterile Hypafix (Fig. 2). The Biobrane adhered well, was sequentially trimmed, and the wound was exposed by postoperative day 12. The right arm healed by 1 month postoperatively (Fig. 3). Minimal scars were present, only on the medial portion of the right hand, at a 1-year follow-up (Fig. 4).

After continuous irrigation, debridement via the



**Fig. 1.** Superficial alkali burns of the upper extremity. The litmus test was mildly alkaline after irrigation and a surgical scrubdown.



**Fig. 2.** The burnt area was tangentially excised with a Zimmer air dermatome set to 18/1,000 cm. Punctate bleeding was observed, and the litmus test showed a neutral pH. Biobrane was applied in the standard fashion.