

An Innovative Scalp-Dyeing Technique with Gentian Violet Solution During Follicular Unit Extraction for White-Haired Follicular Units

Min Seon Moon, Jong Pil Choi

Department of Plastic Surgery, JP Plastic Surgery Clinic, Seoul, Korea

There exist some restrictions and difficulties in performing follicular unit extraction (FUE) in white-haired patients, for several reasons. In this paper, we introduce a novel technique for visualizing white hair during the punching procedure and graft preparation in FUE for white-haired patients. In white-haired older male patients, we dyed the surrounding scalp skin purple with a gentian violet solution-stained toothpick. Our method has several advantages: surgeons can easily focus on the center of the follicular unit and rapidly perform punching, they can recognize the condition of the harvested follicular units during FUE, and the hair transplant team can secure a clear view for trimming and loading into the implanter. We suggest that scalp dyeing in difficult FUE procedures, especially in patients with white hair, may be a simple method that provides a good visualization for donor site harvesting and for microdissection.

Keywords Hair color / Androgenic alopecia / Gentian violet

Correspondence: Jong Pil Choi
 Department of Plastic Surgery, JP
 Plastic Surgery Clinic, 24 Appujeong-
 ro 28-gil, Gangnam-gu, Seoul 06030,
 Korea
 Tel: +82-2-544-9191
 Fax: +82-2-544-9355
 E-mail: pschoii@naver.com

No potential conflict of interest relevant to this article was reported.

Received: 6 Dec 2016 • Revised: 1 Feb 2017 • Accepted: 1 Feb 2017

pISSN: 2234-6163 • eISSN: 2234-6171 • <https://doi.org/10.5999/aps.2017.44.2.170> • Arch Plast Surg 2017;44:170-172

INTRODUCTION

Since William Rassman introduced follicular unit extraction (FUE) in 2002 [1], the practice of FUE has become steadily more common, at the expense of the previous technique of follicular unit strip surgery (FUSS), because it has proven to be less invasive (scarless and painless) and because its results correspond more closely to patients' preferences.

However, there exist some limitations and difficulties in performing FUE. In particular, performing FUE on patients with white hair can be very challenging, for multiple reasons. First, white hair is transparent. Second, the headlight of the practitioner can be reflected in a way that decreases visibility and thus inhibits a precise focus on the center of the hair follicle. Finally,

white hair not only obstructs the operator's visual field, but also decreases visibility during the trimming and loading procedures, because it appears transparent on the background of soft tissue [2,3].

Thus, we developed a novel technique for visualizing white hair during the punching procedure and graft preparation in FUE for white-haired patients.

IDEA

The authors first made the usual FUE design, in which the hair is cut to approximately 0.1 in or less in the "safe" donor area for a white-haired patient, and then local anesthetic and tumescent solution were injected. Gentian violet (G-V) solution (1%) for

scalp dyeing was prepared from 1 mg of G-V powder dissolved in 100 mL of ethyl alcohol. After sufficiently soaking a toothpick or cotton swab with G-V solution, we applied it over the scalp skin 2 to 3 times. The most important consideration in the G-V scalp-dyeing process is that painting should be conducted in the backward direction of the hair and that the solution should be allowed to dry for 1–2 minutes. This process resulted in a darker dye application and more dye pigment saturating the convex skin around the white hair follicles (Fig. 1). Then, we swiped only the dyed-skin area in the same direction of the hair with a dry cotton swab or gauze. When the authors could ensure visibility through the G-V-dyed hair follicle and the surrounding convex skin surface, the usual punching procedure was performed. Trimming was only performed for the graft slimmer by the removal of undesired perifollicular tissues in an FUE graft under a microscope.

DISCUSSION

While the etiology of white hair is still unknown, it is understood to be a manifestation of the aging process and progressive

dysfunction of melanin pigment in melanocytes [4]. Since white hairs are not only similar in color to skin, but also transparent, they can be easily injured during the delicate and highly specialized process of punching or preparing follicular units.

Several methodologies have been discussed for visualizing white-gray hair in hair transplantation. These methods include ultraviolet light, food coloring, hair dye, and external application or injection of methylene blue into the tissue prior to obtaining the donor strip [5]. Use of Meladin to increase visibility is another method that was introduced at the International Society for Hair Restoration Surgery Annual Meeting in 2012 [2].

While continuous efforts have been made to ensure visibility in white-haired transplantation patients, it is often the case that these efforts have been discussed in the context of post-FUSS microdissection. Unlike previous trials, the authors of the present study describe a G-V solution dyeing technique and its usefulness in FUE for patients with white hair.

G-V solution was invented in 1880. Currently, it is most often used in Gram staining for bacteria. In addition, it is used for other clinical purposes, including marking preoperative designs and Candida infection. Though it leaves a stain or a small mark in rare clinical cases, it is non-toxic and water-soluble.

Fig. 2 presents before-and-after pictures of the first patient. The punching visibility is quite interrupted because of the presence of many white hairs, but simple dyeing of the scalp skin is sufficient for clear visualization. The second patient (Fig. 3) dyed his hair at home, but it is hard to obtain a visualization with punching only, as there were some missing spots and dyeing to the root of the white hair was incomplete. However, after scalp skin dyeing, some dye pigment remained at the convex skin surface around the white hair follicles. It is also possible to see a clear contrast between the hair follicle and the scalp skin.

This technique can help improve the clarity of the author's view in the process of hair harvesting, as well as trimming and loading into the implanter. As shown here (Fig. 4), the follicular

Fig. 1. Scalp skin dyeing with 1% G-V solution

Scalp skin dyeing with 1% gentian violet (G-V) solution. We applied the solution with a toothpick or cotton swab.

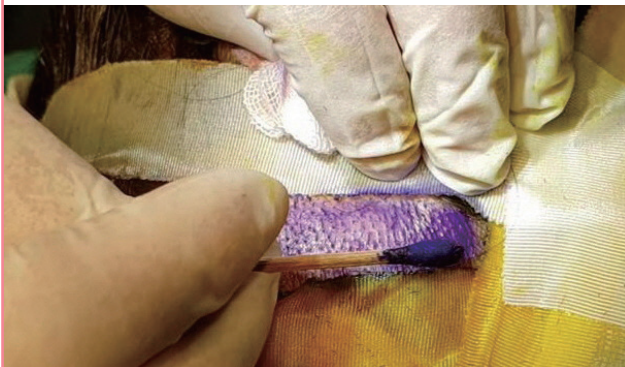

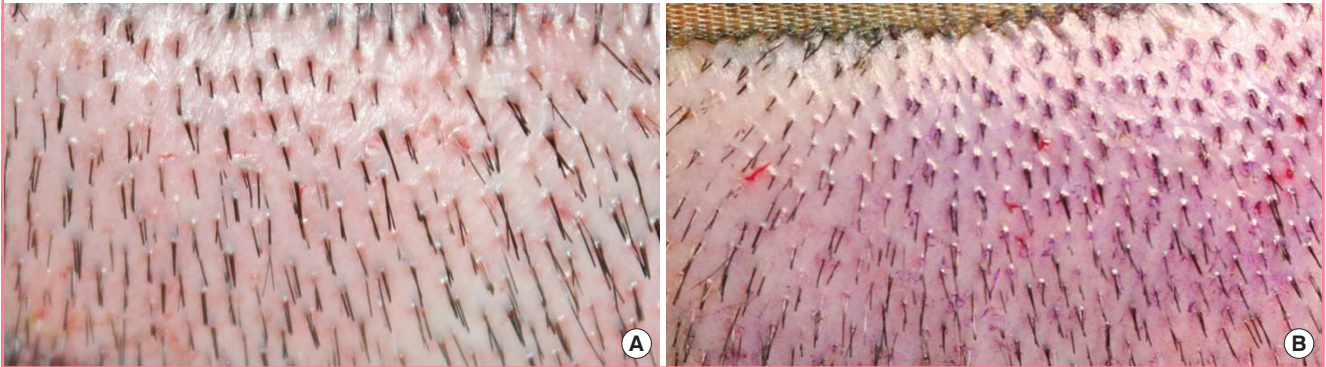
Fig. 2. Pre- and post-dyeing of the first patient

Pre- and post-dyeing of the scalp skin in the first patient. (A) Imperfect visualization due to the presence of many white hairs. (B) Clear visual donor area after dyeing.

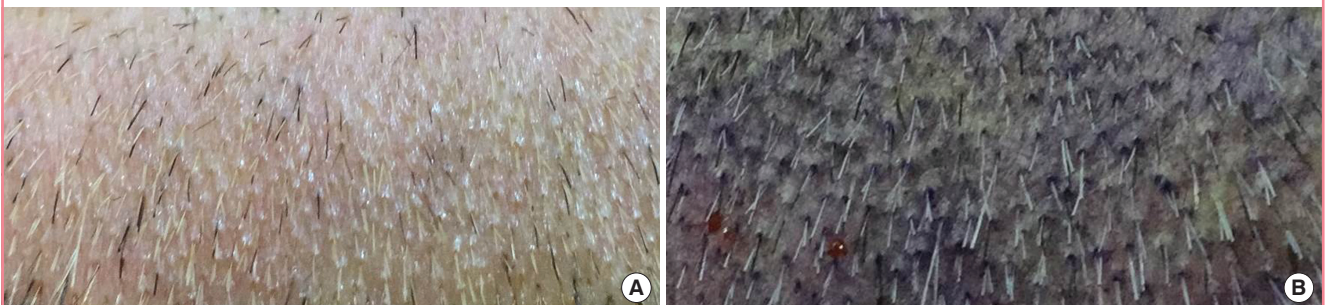

Fig. 3. Pre- and post-dyeing of the second patient

Pre- and post-dyeing of the scalp skin in the second patient: (A) Partially imperfect visualization due to incomplete hair dyeing. (B) A clear view as the dye pigment remained at the convex skin surface around the white hair follicles.

**Fig. 4. A clear view during the trimming procedure**

The white hair follicles are transparent. During scalp dyeing, the soft tissue was also dyed, enabling the hair transplant team to have a clear view.



units of white hair are too white or transparent to be distinguished from the surrounding soft tissue. However, after 1% G-V dyeing of the scalp skin, the soft tissue is also dyed, allowing for a clear view when trimming and loading into the implanter.

In summary, G-V dyeing of the follicular units of white hair presents several benefits: (1) Surgeons can easily focus on the center of the follicular unit and rapidly perform punching. (2) Surgeons can recognize the condition of the harvested follicular units during FUE. (3) The hair transplant team can secure a

clear view for trimming and loading into the implanter.

Finally, further objective research and reports of clinical experiences are needed to demonstrate how this G-V scalp-dyeing technique affects the delicate punching procedure and the quality of FUE grafts.

REFERENCES

1. Rassman WR, Bernstein RM, McClellan R, et al. Follicular unit extraction: minimally invasive surgery for hair transplantation. *Dermatol Surg* 2002;28:720-8.
2. Olsen EA. Disorders of hair growth: diagnosis and treatment. Maidenhead: McGraw-Hill Education; 2003.
3. Marino A, Rios W. White hair and hair transplantation: melanin, white hair, and a new technique to visualize white hair during graft preparation. *Hair Transplant Forum Int* 2012; 22:90-2.
4. Puig C. Bringing out gray donor hair with injectable methylene blue. *Proceeding of the 2005 Orlando Live Surgery Workshop*; 2005 Mar 3-6; Orlando, FL, USA.
5. Keene S. Improving the ability to visualize white/gray hair for surgical dissection. *Proceeding of the 2001 Orlando Live Surgery Workshop*; 2001 Feb 21-24; Orlando, FL, USA.