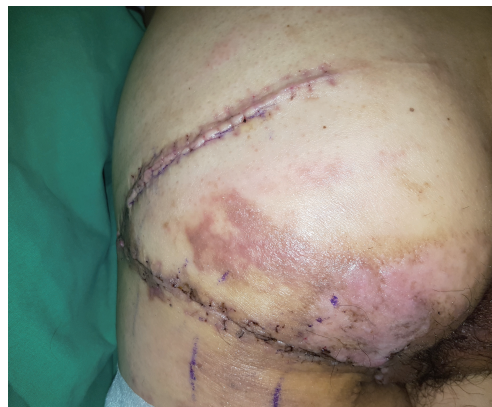
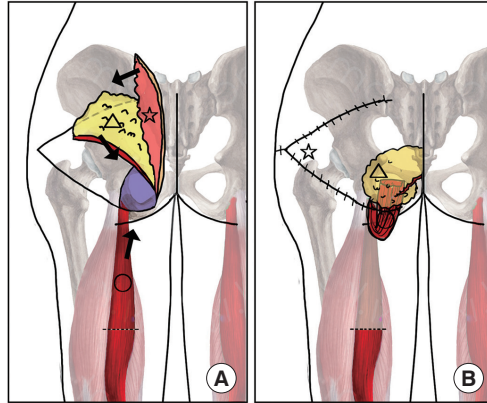


Fig. 3.

Schematic illustration of the reconstruction of a recurrent ischial sore using the 3-flap technique in an intraoperative view. (A) Elevation of 3 flaps: a semitendinosus muscle flap (circle), an inferior gluteal artery pedicled adipofascial flap that did not involve muscle (triangle), and a V-Y advancement skin flap (star). (B) Padding the ischial sore lesion using the 3 flaps (ischial sore lesion indicated by the violet color).

**Fig. 4.**

Postoperative photograph of the well-healed ischial sore lesion treated using the 3-flap technique.

and the availability and efficacy of various tissue types to increase the diversity of flap reconstruction.

References

1. VanGilder C, Amlung S, Harrison P, et al. Results of the 2008-2009 International Pressure Ulcer Prevalence Survey and a 3-year, acute care, unit-specific analysis. *Ostomy Wound Manage* 2009;55:39-45.
2. Bamba R, Madden JJ, Hoffman AN, et al. Flap reconstruction for pressure ulcers: an outcomes analysis. *Plast Reconstr Surg Glob Open* 2017;5:e1187.
3. Lin H, Hou C, Xu Z, et al. Treatment of ischial pressure sores with double adipofascial turnover flaps. *Ann Plast Surg* 2010;64:59-61.

Usefulness of the Versajet Hydrosurgery System for the Removal of Foreign Body Granuloma

Min Choi, Kyung Min Son, Woo Young Choi, Ji Seon Cheon

Department of Plastic and Reconstructive Surgery, Chosun University College of Medicine, Gwangju, Korea

Correspondence: Kyung Min Son

Department of Plastic and Reconstructive Surgery, Chosun University College of Medicine, 309 Pilmun-daero, Dong-gu, Gwangju 61452, Korea
Tel: +82-62-220-3180, Fax: +82-62-225-0996
E-mail: 8love17@hanmail.net

No potential conflict of interest relevant to this article was reported.

Received: 4 Apr 2017 • Revised: 31 May 2017 • Accepted: 7 Jun 2017
pISSN: 2234-6163 • eISSN: 2234-6171
<https://doi.org/10.5999/aps.2017.44.4.352>
Arch Plast Surg 2017;44:352-353



Copyright © 2017 The Korean Society of Plastic and Reconstructive Surgeons
This is an Open Access article distributed under the terms of the Creative Commons Attribution Non-Commercial License (<http://creativecommons.org/licenses/by-nc/4.0/>) which permits unrestricted non-commercial use, distribution, and reproduction in any medium, provided the original work is properly cited.

Materials used for cosmetic/reconstructive purposes can elicit foreign body reactions, resulting in granulomas. Foreign body granulomas are treated with intralesional corticosteroid injections and excisional surgery [1].

A 44-year-old woman presented with irregularities and areas of hardness across the forehead, glabella, and temple. She had undergone a cosmetic procedure involving the injection of an unknown material into these sites 10 years before. We diagnosed the case as foreign body granuloma. We administered 2 intralesional triamcinolone injections (20 mg/mL) at 1-month intervals, but the discomfort persisted. Therefore, we performed surgery using the Versajet hydrosurgery system. The patient was administered anesthesia via propofol, followed by local anesthesia with lidocaine. After 1-cm incisions in both suprabrow areas and 2-cm incisions in the temple area were made, dissection was performed subcutaneously (Fig. 1). We approached the target areas with the 15° Versajet handpiece to remove approximately 5 mL of granuloma fluid (Fig. 2). A postoperative compression dressing was maintained for 3 days to prevent hematoma. The swelling persisted for 1 month. After 3 months of follow-up, the irregularities had improved, and the patient was satisfied with the cosmetic outcomes (Fig. 3).

Versajet uses a razor-thin saline jet for tissue

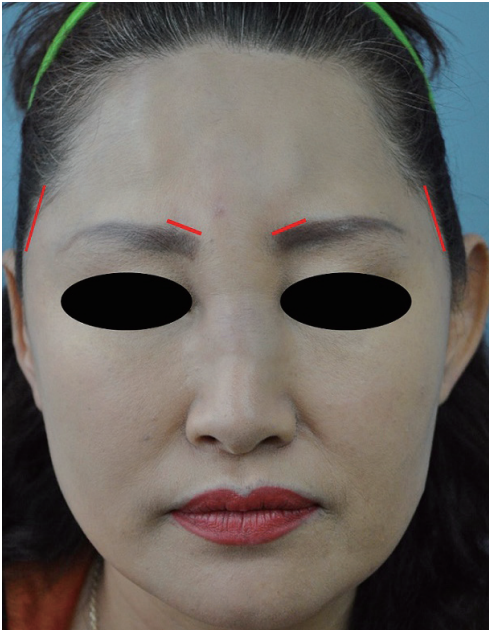

Fig. 1. Incision site on both the temporal area and the suprabrow area (red line).

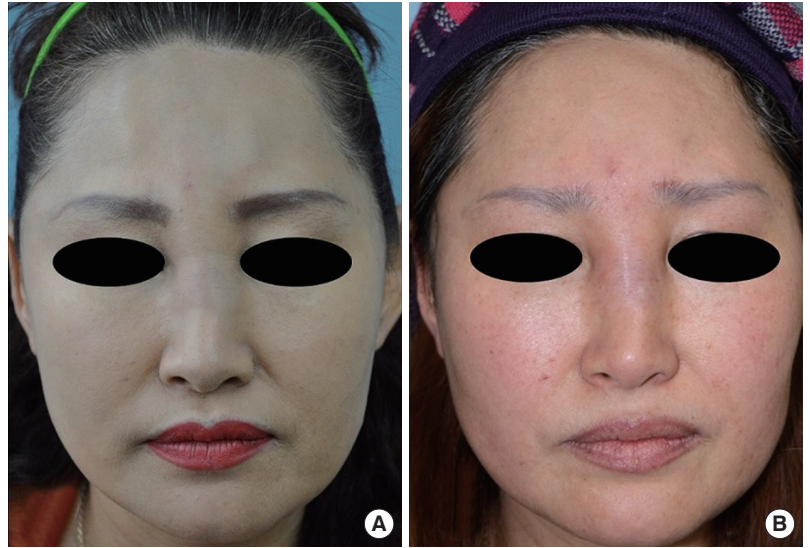


Fig. 3. (A) Preoperative full-face anteroposterior view. (B) Postoperative view.



Fig. 2. Versajet hydrosurgery system and the 15° handpiece device.

debridement and involves reduced scarring because of the smaller incisions. Sterile saline is used for tissue irrigation while the granulomas are removed; the remaining debris is washed out through a localized vacuum effect. The procedure can be completed quickly because the number of debridement sessions required decreases during the procedure [2,3]. Versajet may be a useful tool for the surgical removal of foreign body granulomas.

References

1. Lee JM, Kim YJ. Foreign body granulomas after the use of dermal fillers: pathophysiology, clinical appearance, histologic features, and treatment. *Arch Plast Surg* 2015;42:232-9.
2. Siemers F, Stang FH, Namdar T, et al. Removal of accidental inclusions following blast injury by use of a hydrosurgery system (Versajet™). *Injury Extra* 2010;41:83-4.
3. Cubison TC, Pape SA, Jeffery SL. Dermal preservation using the Versajet hydrosurgery system for debridement of paediatric burns. *Burns* 2006;32:714-20.