



# Recycling of flap pedicle in complex lower extremity reconstruction: A proof of free muscle flap neovascularization

Georgios Pafitanis<sup>1,2</sup>, Alexandros Vris<sup>3</sup>, Dimitris Reissis<sup>2</sup>, Amir Sadri<sup>2</sup>, Reza Alamouti<sup>2</sup>, Simon Myers<sup>1,2</sup>, Parviz Sadigh<sup>2</sup>

<sup>1</sup>Group for Academic Plastic Surgery, The Blizard Institute, Barts' and The London School of Medicine and Dentistry, Queen Mary University of London, London; Departments of <sup>2</sup>Plastic Surgery and <sup>3</sup>Orthopedics, The Royal London Hospital, Barts Health NHS Trust, London, UK

This article portrays the authors' clinical experience of a complex case of lower extremity reconstruction using a recycled pedicle from 10 years old free latissimus dorsi musculocutaneous flap to supply a new free anterolateral thigh flap for proximal tibia wound defect reconstruction. It provides clinical evidence that muscle neovascularization occurs and supports the dogma peripheral tissue neovascularization. This case stipulates that recycling of pedicle is feasible, when used with appropriate strategy and safety and also provides evidence for the long-term survival of greater saphenous vein grafts in lower extremity reconstruction.

**Keywords** Muscle neovascularization / Vein graft / Recycle flap / Flap pedicle

**Correspondence:** Georgios Pafitanis  
Group for Academic Plastic Surgery,  
The Blizard Institute, Barts' and The  
London School of Medicine and  
Dentistry, Queen Mary University of  
London, 4 Newark Street,  
Whitechapel, E12AT, London, UK  
Tel: +44-20-7882-2586  
E-mail: g.pafitanis@qmul.ac.uk

Case Report

Received: February 19, 2018 • Revised: May 16, 2020 • Accepted: June 18, 2020

pISSN: 2234-6163 • eISSN: 2234-6171 • <https://doi.org/10.5999/aps.2018.00171> • Arch Plast Surg 2020;47:619-621

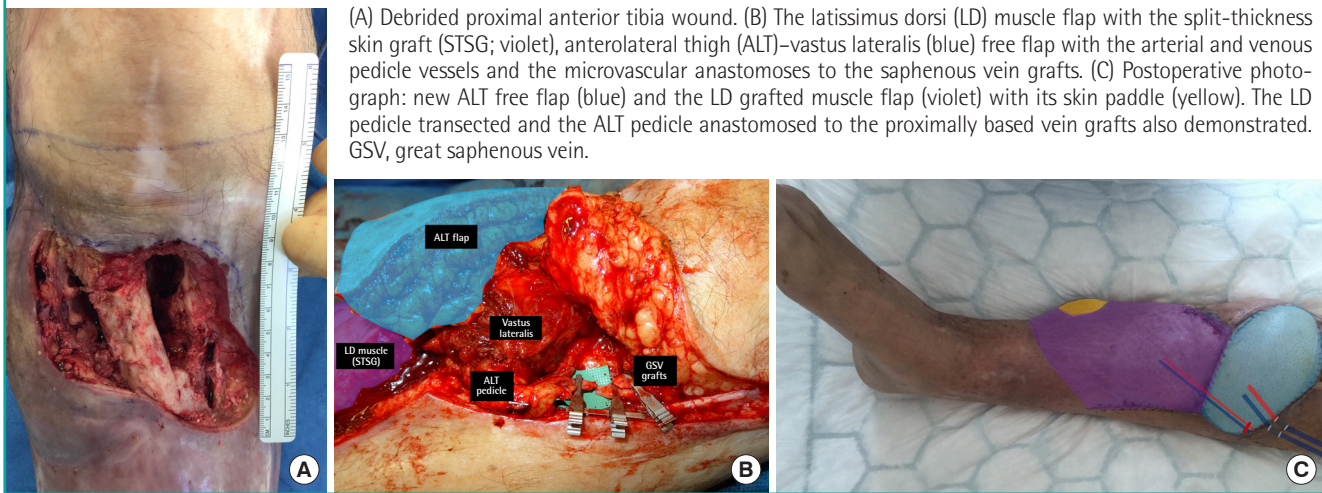
## INTRODUCTION

The mechanism and extent of neovascularization occurring in free flaps postoperatively is yet to be proven. Until recently it was thought that neovascularization of musculocutaneous flaps occurs by angiogenesis at the peripheral skin edges, with very little new blood supply developing to the muscle itself. This dogma has been based on reported cases of partial or complete flap failure after division of the major pedicle [1,2]. However, a recent experimental study by Gundeslioglu et al. [3] has demonstrated that muscle flaps can survive independently of their major pedicle as soon as a week from tissue transfer, as revascularization occurs from well-nourished adjacent tissues. This is of direct clinical relevance when revision surgery is required in the vicinity of a previous free muscle flap, where the pedicle to that

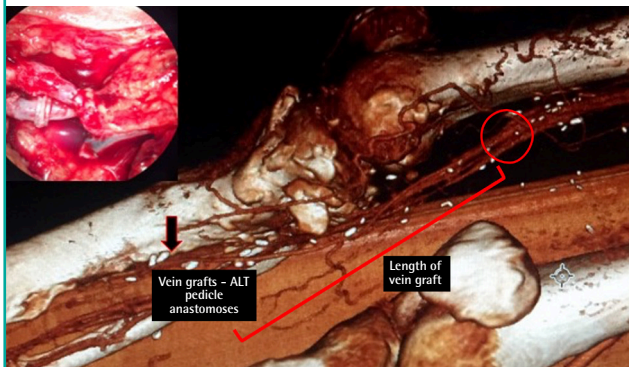
flap becomes compromised or is required for further anastomosis to supply a new free flap.

## CASE

We report a case of recycling the pedicle of a previous free latissimus dorsi (LD) myocutaneous free flap to act as the recipient vessels for a new free anterolateral thigh (ALT) flap in the adjacent region of the same lower limb, with complete survival of both free flaps to allow definitive soft tissue reconstruction. The 43 years old patient, following informed consent, had undergone the free LD myocutaneous flap 10 years previously to cover an extensive soft tissue defect overlying concomitant Gustilo-Anderson Type IIIb proximal and middle third right tibial and fibula comminuted fractures, sustained following a high energy

**Fig. 1. Recycled flap pedicle in lower extremity reconstruction****Fig. 2. CTA confirming flow through GSV graft**

Computed tomography angiogram (CTA) demonstrating good filling through the vein graft, starting from the adductors hiatus and also demonstrated the level of the anastomoses with the pedicle of the new free anterolateral thigh (ALT) flap. Microvascular coupler device for great saphenous vein (GSV)-venous comitant and end-to-end anastomosis vein graft-descending branch of lateral circumflex femoral artery (top left).



road traffic accident. The lack of loco-regional recipient vessels necessitated the use of great saphenous vein (GSV) grafts to anastomose the thoracodorsal pedicle to the recipient superficial femoral artery (SFA). Seven years postoperatively he presented with recurring blisters and discharging sinuses overlying the proximal tibia fracture site. Chronic osteomyelitis was confirmed on magnetic resonance imaging scan and treated with debridement and filling of the defect with polymethylmethacrylate spacer with gentamycin beads, leaving an overlying soft tissue defect 10 × 15 cm at the level of the tibial metaphysis (Fig. 1). Computed tomography angiogram demonstrated flow through the GSV graft (caliber 3–4 mm), extending between the SFA or a large branch, such as the descending genicular artery, towards the anastomosis with the LD muscle flap pedicle, at the level of

the middle third of the tibia (> 20 cm) (Fig. 2). A free ALT flap was used for definitive soft tissue reconstruction to cover the exposed fracture site. Intra-operatively proximal and inferior exploration failed to identify pulsatile anterior tibial or medial genicular arteries. The previously used GSV grafts remained patent and robust following surgical dissection. A microclamp perfusion test, to both inflow and outflow, confirmed neovascularization of the LD flap via peripheral perfusion of its skin paddle, which was surrounded by split-thickness skin graft LD muscle. Thus, a decision was taken to recycle this GSV graft pedicle as the recipient vessels for the new free ALT flap [4]. Arterial anastomosis was performed using 8-0 nylon suture between the GSV graft (from the SFA) and the donor descending lateral circumflex femoral artery. Venous anastomosis was performed using a 4.0 mm coupler between the second GSV graft (to the femoral vein) to the venae comitantes of the descending lateral circumflex femoral artery. The patient made a full recovery with robust soft tissue coverage and survival of both free flaps (Supplementary Figs. 1, 2).

## DISCUSSION

This case demonstrates a clinical proof of neovascularization of a musculocutaneous LD free flap. Thus, its major supplying pedicle could be effectively recycled to act as recipient and successfully supply a new free flap. We also note that this relies on the continued patency and 10-year survival of this high-flow GSV large caliber graft, which could adequately re-perfuse the newly transferred free ALT flap. Vlastou et al. [5] demonstrated the value and efficacy of long vein grafting, with either the short or GSVs, for lower extremity reconstruction. Precisely, demonstrate that when local recipient vessels are not suitable, vein

grafts may provide the only solution. This study further reports that an average length of 20 cm (range, 3–30 cm) was proven reliable, and their success appear to be unrelated to the length of the venous system; and the flap survival is highly related to the severity of the trauma.

The nature and mechanism of this neovascularization of muscle free tissue transfer is not yet clear and requires further trials investigating the nature of neo-vessel angiogenesis, both from the underlying bed and the wound edges. It is essential to establish the basic science behind muscle flap neovascularization and understand the time-frame in which it occurs, as such cases provide salvage options for recycling old free flap pedicles to successfully supply new free flaps required for similar cases of chronic osteomyelitis or repeat trauma in the same affected limb.

## NOTES

### Conflict of interest

No potential conflict of interest relevant to this article was reported.

### Ethical approval

The study was performed in accordance with the principles of the Declaration of Helsinki. Written informed consent was obtained.

### Patient consent

The patient provided written informed consent for the publication and the use of his images.

### Author contribution

Conceptualization: Georgios P, Alexandros V, Simon M, Parviz S. Data curation: Georgios P, Dimitris R. Formal analysis: Georgios P, Simon M. Methodology: Georgios P, Alexandros V, Amir R. Project administration: Georgios P, Alexandros V, Dimitris R. Visualization: Georgios P. Writing - original draft: all authors. Writing - review & editing: all authors. Approval of final manuscript: all authors.

## ORCID

Georgios Pafitanis <https://orcid.org/0000-0003-4712-277X>

Alexandros Vris <https://orcid.org/0000-0001-9723-9533>

Parviz Sadigh <https://orcid.org/0000-0003-2872-5129>

## Supplementary material

Supplementary Fig. 1. Immediate postoperative outcome photography. Postoperative on-table photograph demonstrating the free anterolateral thigh skin paddle, the free latissimus dorsi muscle covered with split-thickness skin graft and its skin paddle. Supplemental data can be found at: <https://doi.org/10.5999/aps.2018.00171>.

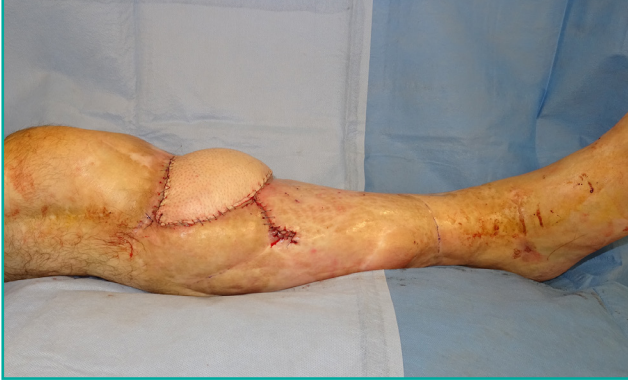Supplementary Fig. 2. Day 7 postoperative outcome photograph. Postoperative day 7 photograph of the reconstructed lower limb. Supplemental data can be found at: <https://doi.org/10.5999/aps.2018.00171>.

## REFERENCES

1. Manrique OJ, Chen SH, Ciudad P, et al. Neovascularization failure of an interposed free intestinal colon flap 10 years after esophageal reconstruction. *J Reconstr Microsurg Open* 2017;2:e35-6.
2. Burns A, Avery BS, Edge CJ. Survival of microvascular free flaps in head and neck surgery after early interruption of the vascular pedicle. *Br J Oral Maxillofac Surg* 2005;43:426-7.
3. Gundeslioglu AO, Selimoglu N, Toy H, et al. Neo-vascularisation of musculocutaneous and muscle flaps after division of the major vascular supply: an experimental study. *J Plast Reconstr Aesthet Surg* 2013;66:978-86.
4. de Vries MR, Simons KH, Jukema JW, et al. Vein graft failure: from pathophysiology to clinical outcomes. *Nat Rev Cardiol* 2016;13:451-70.
5. Vlastou C, Earle AS, Jordan R. Vein grafts in reconstructive microsurgery of the lower extremity. *Microsurgery* 1992; 13:234-5.

**Supplementary Fig. 1. Immediate postoperative outcome photography**

Postoperative on-table photograph demonstrating the free antero-lateral thigh skin paddle, the free latissimus dorsi muscle covered with split-thickness skin graft and its skin paddle.



**Supplementary Fig. 2. Day 7 postoperative outcome photograph**

Postoperative day 7 photograph of the reconstructed lower limb.

