

LETTER**Optimizing aesthetic outcomes after Goldilocks mastectomy: A new method of nipple reconstruction**

Nicola Zingaretti^{1,2}, Gianni Franco Guarneri¹, Francesco De Francesco^{2,3}, Michele Riccio^{2,3}, Emanuele Rampino Cordaro¹, Pier Camillo Parodi^{1,2}

¹Department of Medical Area (DAME), Clinic of Plastic and Reconstructive Surgery, Academic Hospital of Udine, University of Udine, Udine; ²Accademia del Lipofilling, Research and Training Center in Regenerative Surgery, Montelabbate;

³Department of Plastic Reconstructive Surgery and Hand Surgery, Azienda Ospedaliero Universitaria Ospedali Riuniti, Ancona, Italy

Correspondence: Nicola Zingaretti

Clinic of Plastic and Reconstructive Surgery, Academic Hospital of Udine, University of Udine, c/o Ospedale "S. Maria della Misericordia", Piazzale Santa Maria della Misericordia 15, 33100 Udine, Italy

Tel: +39-3391190024, Fax: +39-432552510, E-mail: zingarettin@gmail.com

We sincerely thank Lavinia Bucciarelli (graphic designer; Udine, Italy) for her assistance with the illustration presented in Fig. 1.

Received: March 23, 2020 • Revised: April 19, 2020 • Accepted: April 29, 2020

pISSN: 2234-6163 • eISSN: 2234-6171

<https://doi.org/10.5999/aps.2020.00486> • Arch Plast Surg 2020;47:629-630



Copyright © 2020 The Korean Society of Plastic and Reconstructive Surgeons

This is an Open Access article distributed under the terms of the Creative Commons Attribution Non-Commercial License (<https://creativecommons.org/licenses/by-nc/4.0/>) which permits unrestricted non-commercial use, distribution, and reproduction in any medium, provided the original work is properly cited.

To the Editor,

We read with interest the article by Zavala et al. [1] on the satisfactory aesthetic results achieved with the Goldilocks technique.

In recent years, as increasingly many obese and elderly women are affected by breast cancer, it has become more common to perform the Goldilocks mastectomy, which was first described in 2012 as a way to provide post-mastectomy reconstruction by locally contouring completely autologous breast tissue. In this technique, a breast mound is created by preserving and de-epithelializing the residual mastectomy flap [2].

This technique is suitable for women who decline, or are unsuited for, traditional post-mastectomy reconstruction, especially those with significant medical comorbidities. It is a safe, effective option in patients with a higher than average body mass index and is a safe alternative when reconstruction of breast mounds has been unsuccessful [3].

The Goldilocks breast reconstruction offers good aesthetic outcomes and long-term results [1,4]. Although this technique achieves a good appearance, the removal of the nipple-areolar complex often has a traumatic effect on the patient. After breast reconstruction, most patients proceed to have nipple reconstruction because it can recreate the impression of the original breast [5].

The Goldilocks technique may be preferred for patients with excess local breast tissue who opt for single-stage reconstruction. These

patients often are not in favor of further operations, even nipple reconstruction under local anesthesia. We therefore started to reconstruct the nipple at the same time as the Goldilocks mastectomy.

Although Oliver et al. [3] already discussed staged nipple reconstruction, they did not provide any details about the technique. Therefore, through this communication, we aim to present a new method of nipple reconstruction during Goldilocks breast reconstruction procedures.

The first step is to mark the Wise pattern in the usual manner, with the patient standing erect. We mark the breast meridian on both sides. Then, we mark the apex of the reduction pattern along the breast meridian, as it projects anteriorly from the level of the inframammary fold. We draw the vertical limbs at an angle of 80°.

We draw a triangle at the top of the vertical limbs (Fig. 1A). The length of the lateral segments (l_1) is usually 22–25 mm, depending on the height of the contralateral nipple. Once the mastectomy has been completed, the triangle of skin at the top is left intact (Fig. 1B).

The closure of the surgical wound comes close to the sides of the triangle, in particular P_1 and P_2 (Fig. 1B and C). We therefore use a scalpel to incise the skin along the two end sides of the triangle (orange lines). The length of the incisions is l_2 (half of l_1). The flaps raised are as thin as possible, which is reasonably safe because they have such a broad base with respect to their length (Fig. 1D). One of the two flaps is de-epithelialized (the stippled area in Fig. 1E). Unlike conventional methods, when elevating the flaps, it is not necessary to attach much fat tissue under the flap, because the volume of the nipple is filled with the dermal flap instead of fat tissue. The de-epithelialized flap on one end of the lateral wings is rolled into the column of the neo-nipple to maintain the volume (Fig. 1E). The wounds are closed in two layers with 5-0 Monocryl and 6-0 Nylon (Fig. 1F). We apply antibiotic ointment to the reconstructed nipple and use a “donut” dressing to avoid compression of the nipple for 2 months after surgery.

We used this method for seven women in our clinic (two bilateral and five unilateral Goldilocks mastectomies). No cases of infection, nipple ischaemia, or other complications were recorded. The treatment left an inconspicuous scar and was much appreciated by all patients (and often by their partners).

In our experience with this technique, good projection of the nipple was achieved over the course of at least 2 years of follow-up (Supplemental Figs. 1, 2). The shape of the neo-nipple essentially maintained the form that resulted from the surgical procedure, with an average loss of projection of 20%.

This method is very simple conceptually and procedurally, does not involve a complicated design, and can be applied to both unilateral and bilateral Goldilocks mastectomies. It does not require another donor site, a great deal of time, or advanced skill. This method compensates for the loss of the nipple with a speedy and reliable procedure. We aim to confirm the advantages of our technique through a further investigation, involving a larger number of cases and a longer follow-up.

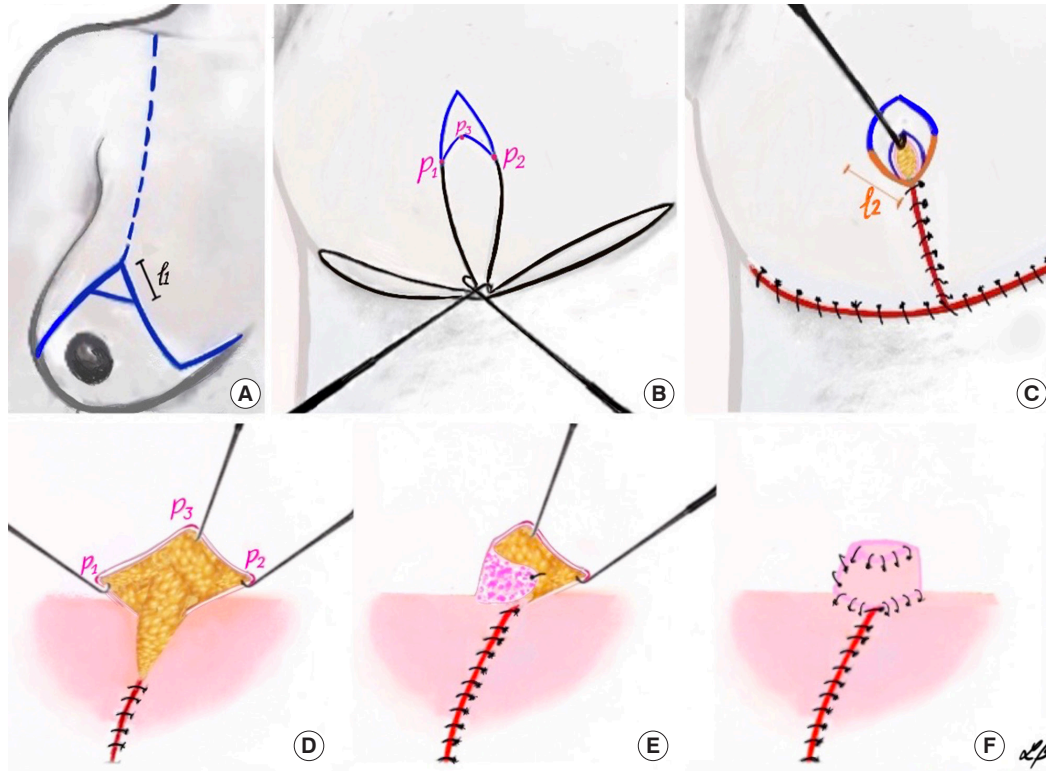


Fig. 1.

Preoperative design for nipple reconstruction. (A) Placing the design. We designed a triangle at the top of the Wise pattern. “ l_1 ” indicates the length of each segment, which was usually 22–25 mm, depending on the height of the contralateral nipple. (B) After the mastectomy was completed, the surgical wound closure approached the sides of the triangle, in particular P_1 and P_2 . (C) The skin was incised along the distal part of the lateral segments (orange lines). The length of the incisions was l_2 (half of l_1). (D) The flaps were raised and one of the two flaps was de-epithelialized (the stippled area in panel E). (E) The lateral dermal flap was rolled into the neo-nipple column. (F) Completion of the neo-nipple.

Notes

Conflict of interest

No potential conflict of interest relevant to this article was reported.

Ethical approval

The study was approved by the Institutional Review Board of University of Udine (IRB No. 2019-016-092) and performed in accordance with the principles of the Declaration of Helsinki. Written informed consents were obtained.

Patient consent

The patients provided written informed consent for the publication and the use of their images.

ORCID

Nicola Zingaretti <https://orcid.org/0000-0002-1575-0029>
 Gianni Franco Guarneri <https://orcid.org/0000-0002-5815-8439>
 Francesco De Francesco <https://orcid.org/0000-0003-2977-7828>
 Michele Riccio <https://orcid.org/0000-0001-5554-4759>
 Emanuele Rampino Cordaro <https://orcid.org/0000-0001-6024-8647>
 Pier Camillo Parodi <https://orcid.org/0000-0002-4677-8198>

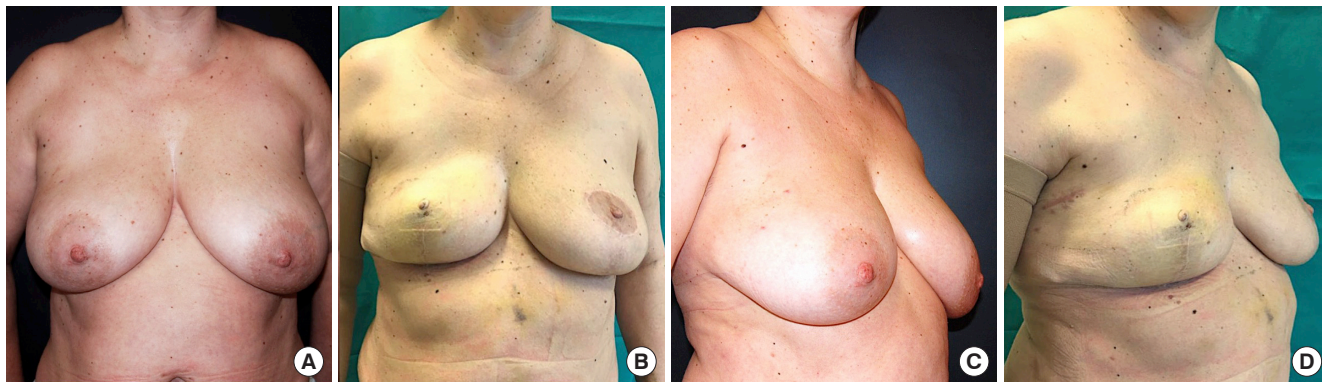Supplementary material

Supplemental Fig. 1. Clinical case 1. Supplemental data can be found at: <https://doi.org/10.5999/aps.2020.00486>.

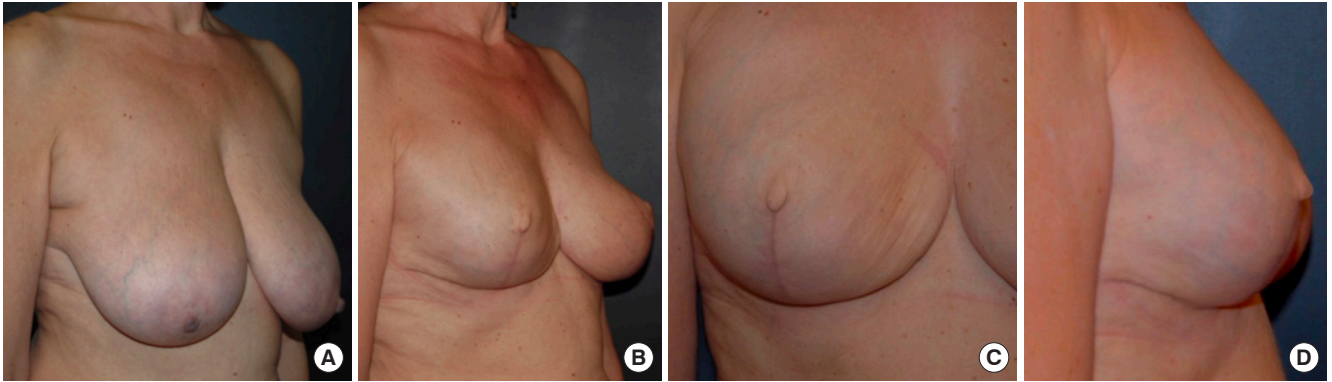
Supplemental Fig. 2. Clinical case 2. Supplemental data can be found at: <https://doi.org/10.5999/aps.2020.00486>.

References

- Zavala KJ, Kwon JG, Han HH, et al. The Goldilocks technique: an alternative method to construct a breast mound after prosthetic breast reconstruction failure. *Arch Plast Surg* 2019;46:475-9.
- Richardson H, Ma G. The Goldilocks mastectomy. *Int J Surg* 2012; 10:522-6.
- Oliver JD, Chaudhry A, Vyas KS, et al. Aesthetic Goldilocks mastectomy and breast reconstruction: promoting its use in the ideal candidate. *Gland Surg* 2018;7:493-5.
- Chaudhry A, Oliver JD, Vyas KS, et al. Outcomes analysis of Goldilocks mastectomy and breast reconstruction: a single institution experience of 96 cases. *J Surg Oncol* 2019;119:1047-52.
- De Biasio F, Zingaretti N, Mura S, et al. A new method of salvaging nipple projection after secondary nipple reconstruction using locoregional flap. *Indian J Plast Surg* 2017;50:107-8.

**Supplemental Fig. 1.**

Clinical case 1. A 52-year-old patient had a body mass index of 36.1 kg/m^2 and ductal carcinoma *in situ* on the right side. She was treated with a unilateral Goldilocks mastectomy and contralateral breast reduction preoperatively (A, C) and at 24 months postoperatively (B, D). In the same operation, the right nipple was reconstructed using the technique described herein. Noteworthy outcomes included good nipple projection and a minimal scar.

**Supplemental Fig. 2.**

Clinical case 2. A 62-year-old patient who had a body mass index of 36.8 kg/m². (A) Preoperative view of this patient with ductal carcinoma *in situ* on the right side. (B) Postoperative view 16 months after unilateral Goldilocks mastectomy and contralateral breast reduction. (C, D) The right nipple was reconstructed using the technique described herein.