



The molecular pathophysiology of vascular anomalies: Genomic research

Jong Seong Kim¹, Su-Kyeong Hwang², Ho Yun Chung^{1,3}

Departments of ¹Plastic and Reconstructive Surgery and ²Pediatrics, ³Cell & Matrix Research Institute, School of Medicine, Kyungpook National University, Daegu, Korea

Vascular anomalies are congenital localized abnormalities that result from improper development and maintenance of the vasculature. The lesions of vascular anomalies vary in location, type, and clinical severity of the phenotype, and the current treatment options are often unsatisfactory. Most vascular anomalies are sporadic, but patterns of inheritance have been noted in some cases, making genetic analysis relevant. Developments in the field of genomics, including next-generation sequencing, have provided novel insights into the genetic and molecular pathophysiological mechanisms underlying vascular anomalies. These insights may pave the way for new approaches to molecular diagnosis and potential disease-specific therapies. This article provides an introduction to genetic testing for vascular anomalies and presents a brief summary of the etiology and genetics of vascular anomalies.

Keywords Vascular anomalies / Genomic research / DNA sequencing / Next generation sequencing / Signaling pathway

Correspondence: Ho Yun Chung
Department of Plastic and Reconstructive Surgery, School of Medicine, Kyungpook National University, 130 Dongdeok-ro, Jung-gu, Daegu 41944, Korea
Tel: +82-53-420-5692
Fax: +82-53-425-3879
E-mail: hy-chung@knu.ac.kr

This work was supported by the National Research Foundation of Korea (NRF) grant funded by the Korea government (MSIT) (No. 2020R1A2C2009496).

Received: April 6, 2020 • Revised: April 30, 2020 • Accepted: April 30, 2020
pISSN: 2234-6163 • eISSN: 2234-6171 • <https://doi.org/10.5999/aps.2020.00591> • Arch Plast Surg 2020;47:203-208

INTRODUCTION

The clinicopathological classification of vascular anomalies, which was first proposed by Mulliken and Glowacki in 1982 [1], has continued to be a basic standard. The classification of these anomalies into two broad categories—tumors and vascular malformations—was the basis of the 2018 classification proposed by the International Society for the Study of Vascular Anomalies (ISSVA). However, there are still many limitations of pathophysiological analyses on the basis of clinical and histological findings [2-4]. Since recent studies have identified many genes potentially linked to vascular anomalies, several pathophysiological analyses based on these genes have been conducted, and potential new treatments have also been proposed. Since the 1990s, the genetic basis for vascular anomalies has been eluci-

dated, and as a result, mutations associated with numerous types of lesions have been reported over the past few years [3]. Recent developments in sequencing technologies have opened new horizons in terms of genomic studies, and research in this field is actively expanding [5]. This article presents an introduction to genetic testing for vascular anomalies and a brief summary of the etiology and genetics of vascular anomalies.

GENETIC TESTS FOR VASCULAR ANOMALIES

In the past few decades, remarkable and unexpected advances in genetic testing have been made. The completion of the Human Genome Project in 2003 was followed by a veritable flood of discoveries regarding the genetic basis of various diseases [6]. Even-

tually, patients' genomes will be sequenced to identify genetic diseases, to analyze the causes of complex multifactorial diseases, and to predict the best treatment and prognosis for each individual.

There are two major classes of genetic variations: copy number variations (CNVs) and single-nucleotide variants (SNVs). A CNV is defined as a change in length of 1,000 or more base sequences. Genome-wide CNVs can be detected using a chromosomal microarray (CMA) with high resolution. SNVs take place when a single nucleotide (e.g., A, T, C, or G) is altered in the DNA sequence. SNVs are the most frequent genomic variations.

Sequencing refers to reading the DNA base sequence containing genetic information in order. DNA sequencing can be broadly divided into Sanger sequencing and next-generation sequencing (NGS) [7]. The Sanger method involves sequencing single strands of DNA, whereas in NGS, one long DNA strand is cut into millions of strands, and then genes are amplified and sequenced at once [7,8]. NGS is composed of four basic steps. The first step is library preparation, in which extracted DNA is cut into millions of pieces randomly and then adapters are attached to the 5' and 3' ends of DNA for further polymerase chain reaction (PCR). Second, in the cluster generation step, each of the millions of DNA fragments is amplified through PCR to create clonal clusters. Third, in the sequencing step, complementary nucleotides are generated by DNA polymerase from the DNA strand cluster and the nucleotide type is identified with fluorescence. Fourth, in the data analysis step, the sequence data of millions of short reads are arranged using the reference genome and sequencing results are obtained through bioinformatics. Sanger sequencing reads hundreds of nucleotide sequences in detail, whereas NGS can quickly identify sequences across genomes at a low cost. The general category of NGS includes whole exome sequencing (WES), targeted gene panel sequencing (TS), and whole genome sequencing (WGS).

Applicable genetic testing methods for vascular anomalies are Sanger sequencing for a defined phenotype with a monogenic disorder, CMA, TS, WES, and WGS. The testing method should be carefully chosen according to the purpose of testing. Usually, CNVs are analyzed by CMA or WGS, whereas SNVs and small insertions/deletions are more suitable for analysis by sequencing, WES, or WGS. Genetic testing can follow an orderly progression if the diagnosis remains unclear.

Mutations can be classified into germline mutations and somatic mutations. Germline mutations pass from the parent to the offspring through germ cells, and can therefore be found in almost every cell in an individual. Somatic mutations occur only in a subgroup of cells (excluding germ cells) in an individual. Therefore, these mutations are not transmitted to the next generation. Instead, they are only transmitted to the offspring of the

affected cells, giving rise to somatic mosaicism, which plays a major role in the development of vascular lesions. Somatic mutations can cause disease, as exemplified by cancer, where cells acquire somatic mutations and develop into tumors.

Although familial inheritance has also been reported, most vascular anomalies are sporadic. Germline mutations can be tested using blood, buccal mucosal cells, or lesion tissue samples; however, somatic mutations can only be found in lesion tissue samples. NGS has proven to be a valuable tool for discovering somatic mutations [9,10].

GENETICS OF VASCULAR ANOMALIES

The causal genes of vascular anomalies known to date are well organized in the ISSVA classification of vascular anomalies (c2018 ISSVA, available from: issva.org/classification) [11].

Vascular tumors

Infantile hemangioma

Infantile hemangioma (IH) arises from the proliferation of endothelial cells (ECs). Two main proposals have been made regarding the origins of ECs in IH: embolic placental angioblasts, which share placental markers (glucose transporter protein 1 [GLUT1], Fcγ receptor II, Lewis Y antigen, and merosin), and endothelial progenitor cells (CD133⁺/CD34⁺ circulating progenitor cells and stem cells) [12,13]. Vascular endothelial growth factor (VEGF)-A signaling is associated with IH. In the ECs in IH, the formation of IH has been shown to be caused by changes in the VEGF-A signaling pathway that are related to missense mutations in the genes encoding VEGFR2 (*KDR*) and TEM8 (*ANTXR1*) [14,15].

Congenital hemangioma

There are three types of congenital hemangioma (CH) that appear fully formed at birth: non-involuting CH, partially involuting CH, and rapidly involuting CH [15,16]. They are all GLUT1-negative. It has been reported that there is a mutation at the glutamine 209 (Gln209) position in *GNAQ* or *GNAI1*, and the Gln209 missense mutation is known to activate GTP-dependent signaling, which leads to the constitutive activation of MAPK and/or YAP signaling [17].

Pyogenic granuloma

Pyogenic granuloma (PG) may be isolated or associated with a capillary malformation (CM). It has been reported that PGs associated with CM (secondary PGs) show a somatic *GNAQ* mutation reflecting an origin from CM cells. Furthermore, *BRAF*

somatic mutations were found in eight of 10 secondary PGs and *NRAS* mutations in one of 10. However, isolated PGs were associated with *BRAF* (four of 25) or *KRAS* (one of 25) mutations [18]. A somatic activating *GNA14* mutation has been reported in one case and a *GNA11* mutation in two cases [19].

Kaposiform hemangioendothelioma

Kaposiform hemangioendothelioma (KHE) is usually present at birth and is typically diagnosed in infancy or early childhood. The incidence of the Kasabach-Merritt phenomenon has been estimated at 42% to 71% in KHE [20]. *GNA14* mutations were found in one of three KHE specimens and one of four closely related tufted angiomas [19].

Vascular malformations

Capillary malformation

CM is the most common type of vascular malformation [21]. *GNAQ* mutations were found in 80%–90% of cases with a sporadic or syndromic (Sturge-Weber syndrome) etiology [22]. *GNA11* mutations were identified in three of eight specimens with diffuse CM and overgrowth of an extremity [23]. The *GNAQ* mutations in CM primarily present in ECs [24]. Atypical CM may co-occur with arteriovenous malformation (AVM) in a single patient. This entity, which is referred to as CM-AVM, can be subdivided into CM-AVM1 and CM-AVM2. CM-AVM1 is inherited in an autosomal dominant pattern and is caused by a *RASA1* mutation [25]. One-third of patients with CM-AVM1 have fast-flow lesions; in contrast, the risk of fast-flow malformations is lower in CM-AVM2, which is caused by a loss-of-function mutation in *EPHB4* [26].

Lymphatic malformations

Lymphatic malformations (LMs) are sporadic slow-flow lesions that are composed of multiple cystic structures, which can be macroscopic, microscopic or combined [27]. *PIK3CA* mutations were found in 16 of 17 specimens. Mutations in the *PIK3CA* gene can enhance the ability of its protein product to bind to the cell membrane or activate its kinase, which results in activation of the AKT/mTOR signaling pathway [28,29]. Rapamycin (sirolimus), which is well known as an mTOR inhibitor, has shown good efficacy and a favorable safety profile when used in patients [10]. Primary lymphedema is a type of vascular malformation that can be hereditary. Several mutations (*VEGFR3/FLT-4*, *FOXC2*, *SOX18*, *CCBE1*, etc.) have been identified in patients with primary lymphedema [15].

Venous malformations

Venous malformations (VMs) are usually sporadic, but can be

familial [30]. Cutaneomucosal autosomal dominant VM was found to be caused by *TIE2* mutations, which were found in 80 of 130 specimens of sporadic VMs. Activating somatic mutations of *PIK3CA* have also been identified in sporadic VMs that lacked *TEK/TIE2* mutations [3,15,31]. Verrucous VMs associated with the *MAP3K3* mutation are hyperkeratotic abnormalities that affect the skin of limbs [32]. Glomuvenous malformation (GVM) is an autosomal dominant disease in which several small lesions are caused by germline or somatic loss-of-function mutations in glomulin (*GLMN*) [33]. GVMs have reported as requiring somatic second-hit mutations to trigger disease onset; the first mutation is inherited in an autosomal dominant manner, while the second mutation is acquired. Blue rubber bleb nevus syndrome, which is a non-hereditary condition, presents as multifocal VMs. This syndrome is associated with *TIE2* mutations [34]. Cerebral cavernous malformations (CCMs) are characterized by enlarged capillary cavities in the central nervous system. In 9% of CCM patients, cutaneous lesions are also found. CCMs, which are associated with mutations in *CCM1/KRIT1*, *CCM2/malcavernin*, and *CCM3/PDCD10*, can be sporadic or familial [5,35].

Arteriovenous malformations

AVMs are anomalous connections between arteries and veins through a nidus or fistula, bypassing high-resistance capillary beds [36]. AVMs occur sporadically, and are associated with a mutation in the *MAP2K1* gene [37]. Inherited AVMs can occur in the context of other conditions, such as hereditary hemorrhagic telangiectasia (HHT), and combined diseases such as CM-AVM (see CM) and Parkes Weber syndrome [10,15,24].

Hereditary hemorrhagic telangiectasia

HHT is an autosomal dominant vascular dysplasia that can cause epistaxis, mucocutaneous telangiectasias, and/or visceral AVMs. Ninety percent of HHT cases are associated with a loss-of-function mutation of one of three identified genes. HHT1 is associated with mutations in endoglin (*ENG*), a co-receptor for activin-like receptor; HHT2 with mutations in activin receptor-like kinase 1 (*ACVRL1*); and juvenile polyposis/HHT syndrome with mutations in *MADH4*, which encodes the downstream effector SMAD4. HHT is associated with germline mutations in genes involved in the TGF- β /BMP signaling pathway [5,38,39].

Vascular malformations associated with other anomalies

Vascular malformations are one of the major components in various syndromes that cause enlargement of soft tissues or bones. Klippel-Trenaunay syndrome (KTS) presents with a

classic triad of port-wine stains, asymmetric extremity overgrowth, and underlying VMs or LMs [40,41]. In 19 of 21 KTS patients, *PIK3CA* mutations were found to play a role in the pathogenesis of the condition [42]. Macrocephaly-CM usually causes neurological abnormalities, and patients typically have CM on the upper lip, back, and/or limbs. These patients also have *PIK3CA* mutations [43]. CLOVES syndrome is characterized by congenital lipomatosis, overgrowth, vascular malformations, epidermal nevi, and skeletal anomalies. Mutations in *PIK3CA* were identified in 36 of 38 patients [44]. Proteus syndrome, which features asymmetric growth of skeletal and connective tissue, cerebriform nevi of the hands or feet, epidermal nevi, and underlying vascular malformations, results from a somatic activating mutation in *AKT1* [45]. Maffucci syndrome

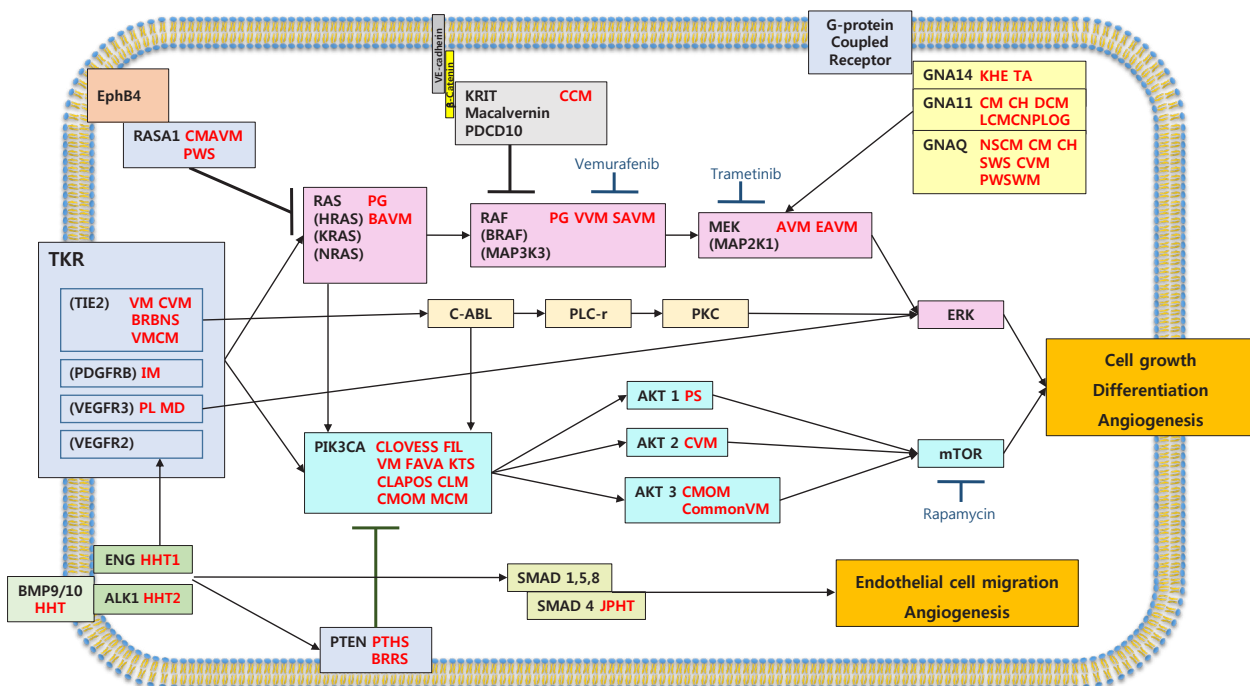
features several enchondromas and soft-tissue VMs. This condition results from somatic mutations of isocitrate dehydrogenase (IDH), with 98% of cases caused by *IDH1* mutations and 2% by *IDH2* mutations [46].

ABNORMAL SIGNALING PATHWAYS IN VASCULAR ANOMALIES

These genetic mutations directly change the activities of intracellular signaling pathways, thereby influencing various downstream actions. The pathways most involved in vascular anomalies are the PI3K/AKT/mTOR and RAS/MAPK signaling pathways. Another important signaling mechanism is the TGF-β/SMAD signaling pathway, which plays a role in HHT (Fig. 1).

Fig. 1. Mutations and signaling pathways in vascular anomalies

Mutations in vascular abnormalities affect genes involved in tyrosine kinase signaling via the RAS or PIK3CA pathways. This figure is a schematic diagram of key genetic mutations related to signal transduction and vascular malformations in endothelial cells. Proteins mutated in other vascular disorders are indicated. Mutations in *GNAQ/GNA11/GNA14*, *RASA1*, and *KRIT* lead to constitutive activation of RAS/RAF/MEK/ERK signaling. Mutations in *TIE2/TEK* lead to permanent activation of the PIK3CA/AKT/mTOR pathway. AVM, arteriovenous malformation; BAVM, brain arteriovenous malformation; BRBNS, blue rubber bleb nevus syndrome; BRRS, Bannayan-Riley-Ruvalcaba syndrome; CCM, cerebral cavernous malformation; CH, congenital hemangioma; CLAPOS, CLAPO syndrome; CLM, cystic lymphatic malformation; CLOVSS, CLOVES syndrome; CM, capillary malformation; CommonVM, common venous malformation; CMAVM, capillary malformation-arteriovenous malformation 1,2; CMOM, capillary malformation of macrocephaly; CVM, cutaneous mucosal venous malformation; CH DCM, diffuse capillary malformation; EAVM, extracranial arteriovenous malformation; FIL, facial infiltrating lipomatosis; FAVA, fibroadipose vascular anomaly; VMCM, Familial venous malformation cutaneous and mucosal; HHT, hereditary hemorrhagic telangiectasia; IM, infantile myofibroma; JPHT, juvenile polyposis hemorrhagic telangiectasia; KHE, kaposiform hemangioendothelioma; KTS, Klippel-Trenaunay syndrome; LCMCNPLOG, limb capillary malformation with congenital nonprogressive limb overgrowth; MD, Milroy's disease; MCM, megalencephaly capillary malformation; NSCM, non-syndromic capillary malformation; PL, primary lymphedema; PS, Proteus syndrome; PTHS, PTEN hamartoma syndrome; PG, pyogenic granuloma; PWS, Parkes Weber syndrome; PWSWM, port wine stain with macrocheilia; SVAM, spinal arteriovenous malformation; SWS, Surge-Weber syndrome; TA, tufted angioma; VM, venous malformation; VVM, verrucous venous malformation.



CONCLUSIONS

Advances in DNA sequencing have yielded extensive knowledge regarding the etiological molecular mechanisms involved in the development of vascular anomalies. NGS is a very effective method of analyzing germline and somatic mutations of vascular anomalies, which have various phenotypes, and their associated dysfunctions. An important point to be emphasized is that somatic mutations and their mechanisms for vascular anomalies, which mainly are sporadic and unifocal, should be further studied in the future. Although many downstream effects remain unknown, it is clear that normalization of the affected signaling pathways is an important target for treatment. Mutation-specific targeted therapies are also being studied, which may result in a paradigm shift in therapeutic approaches to vascular anomalies. Further research into the cellular effects of mutations is expected to yield insights into the underlying pathophysiology that will enable new therapies to be developed.

NOTES

Conflict of interest

No potential conflict of interest relevant to this article was reported.

Author contribution

Conceptualization: JS Kim, SK Hwang, HY Chung. Data curation: JS Kim, SK Hwang, HY Chung. Formal analysis: HY Chung. Funding acquisition: HY Chung. Methodology: HY Chung. Project administration: HY Chung. Visualization: JS Kim, HY Chung. Writing - original draft: JS Kim, HY Chung. Writing - review & editing: JS Kim, SK Hwang, HY Chung.

ORCID

Jong Seong Kim <https://orcid.org/0000-0002-4725-9277>
 Su-Kyeong Hwang <https://orcid.org/0000-0001-8294-7094>
 Ho Yun Chung <https://orcid.org/0000-0001-7359-3044>

REFERENCES

- Mulliken JB, Glowacki J. Hemangiomas and vascular malformations in infants and children: a classification based on endothelial characteristics. *Plast Reconstr Surg* 1982;69:412-22.
- Mulliken JB, Burrows PE, Fishman DJ. Mulliken and Young's vascular anomalies: hemangiomas and malformations. 2nd ed. New York: Oxford University Press; 2013.
- Greene AK, Goss JA. Vascular anomalies: from a clinicohistologic to a genetic framework. *Plast Reconstr Surg* 2018;141:709e-717e.
- Lee JW, Chung HY. Vascular anomalies of the head and neck: current overview. *Arch Craniofac Surg* 2018;19:243-7.
- Queisser A, Boon LM, Vikkula M. Etiology and genetics of congenital vascular lesions. *Otolaryngol Clin North Am* 2018;51:41-53.
- Collins FS, Morgan M, Patrinos A. The Human Genome Project: lessons from large-scale biology. *Science* 2003;300:286-90.
- Sohn J. Next generation sequencing and anti-cancer therapy. *J Korean Med Assoc* 2019;62:119-29.
- Koboldt DC, Steinberg KM, Larson DE, et al. The next-generation sequencing revolution and its impact on genomics. *Cell* 2013;155:27-38.
- Wetzel-Strong SE, Detter MR, Marchuk DA. The pathobiology of vascular malformations: insights from human and model organism genetics. *J Pathol* 2017;241:281-93.
- Adams DM. Practical genetic and biologic therapeutic considerations in vascular anomalies. *Tech Vasc Interv Radiol* 2019;22:100629.
- International Society for the Study of Vascular Anomalies (ISSVA). ISSVA classification of vascular anomalies [Internet]. Milwaukee, WI: ISSVA; c2018 [cited 2020 May 11]. Available from: issva.org/classification.
- North PE, Waner M, Brodsky MC. Are infantile hemangiomas of placental origin? *Ophthalmology* 2002;109:633-4.
- Khan ZA, Boscolo E, Picard A, et al. Multipotential stem cells recapitulate human infantile hemangioma in immunodeficient mice. Version 2. *J Clin Invest* 2008;118:2592-9.
- Jinnin M, Medici D, Park L, et al. Suppressed NFAT-dependent VEGFR1 expression and constitutive VEGFR2 signaling in infantile hemangioma. *Nat Med* 2008;14:1236-46.
- Uebelhoefer M, Boon LM, Vikkula M. Vascular anomalies: from genetics toward models for therapeutic trials. *Cold Spring Harb Perspect Med* 2012;2:a009688.
- Nasseri E, Piram M, McCuaig CC, et al. Partially involuting congenital hemangiomas: a report of 8 cases and review of the literature. *J Am Acad Dermatol* 2014;70:75-9.
- Ayturk UM, Couto JA, Hann S, et al. Somatic activating mutations in GNAQ and GNA11 are associated with congenital hemangioma. *Am J Hum Genet* 2016;98:789-95.
- Groesser L, Peterhof E, Evert M, et al. BRAF and RAS mutations in sporadic and secondary pyogenic granuloma. *J Invest Dermatol* 2016;136:481-6.
- Lim YH, Bacchiocchi A, Qiu J, et al. GNA14 somatic mutation causes congenital and sporadic vascular tumors by

- MAPK activation. *Am J Hum Genet* 2016;99:443-50.
20. Ji Y, Chen S, Yang K, et al. Kaposiform hemangioendothelioma: current knowledge and future perspectives. *Orphanet J Rare Dis* 2020;15:39.
 21. Lee JW, Chung HY. Capillary malformations (Portwine Stains) of the head and neck: natural history, investigations, laser, and surgical management. *Otolaryngol Clin North Am* 2018;51:197-211.
 22. Shirley MD, Tang H, Gallione CJ, et al. Sturge-Weber syndrome and port-wine stains caused by somatic mutation in *GNAQ*. *N Engl J Med* 2013;368:1971-9.
 23. Couto JA, Ayturk UM, Konczyk DJ, et al. A somatic *GNA11* mutation is associated with extremity capillary malformation and overgrowth. *Angiogenesis* 2017;20:303-6.
 24. Couto JA, Huang L, Vivero MP, et al. Endothelial cells from capillary malformations are enriched for somatic *GNAQ* mutations. *Plast Reconstr Surg* 2016;137:77e-82e.
 25. Eerola I, Boon LM, Mulliken JB, et al. Capillary malformation-arteriovenous malformation, a new clinical and genetic disorder caused by *RASA1* mutations. *Am J Hum Genet* 2003;73:1240-9.
 26. Amyere M, Revencu N, Helaers R, et al. Germline loss-of-function mutations in *EPHB4* cause a second form of Capillary Malformation-Arteriovenous Malformation (CM-AVM2) deregulating RAS-MAPK signaling. *Circulation* 2017;136:1037-48.
 27. Cho BC, Kim JB, Lee JW, et al. Cervicofacial lymphatic malformations: a retrospective review of 40 cases. *Arch Plast Surg* 2016;43:10-8.
 28. Boscolo E, Coma S, Luks VL, et al. AKT hyper-phosphorylation associated with *PI3K* mutations in lymphatic endothelial cells from a patient with lymphatic malformation. *Angiogenesis* 2015;18:151-62.
 29. Osborn AJ, Dickie P, Neilson DE, et al. Activating *PIK3CA* alleles and lymphangiogenic phenotype of lymphatic endothelial cells isolated from lymphatic malformations. *Hum Mol Genet* 2015;24:926-38.
 30. Park H, Kim JS, Park H, et al. Venous malformations of the head and neck: a retrospective review of 82 cases. *Arch Plast Surg* 2019;46:23-33.
 31. Uebelhoer M, Natynki M, Kangas J, et al. Venous malformation-causative *TIE2* mutations mediate an AKT-dependent decrease in PDGFB. *Hum Mol Genet* 2013;22:3438-48.
 32. Couto JA, Vivero MP, Kozakewich HP, et al. A somatic *MAP3K3* mutation is associated with verrucous venous malformation. *Am J Hum Genet* 2015;96:480-6.
 33. Brouillard P, Boon LM, Mulliken JB, et al. Mutations in a novel factor, glomulin, are responsible for glomuvenous malformations ("glomangiomas"). *Am J Hum Genet* 2002;70:866-74.
 34. Soblet J, Kangas J, Natynki M, et al. Blue Rubber Bleb Nevus (BRBN) syndrome is caused by somatic *TEK* (*TIE2*) mutations. *J Invest Dermatol* 2017;137:207-16.
 35. Cavalcanti DD, Kalani MY, Martirosyan NL, et al. Cerebral cavernous malformations: from genes to proteins to disease. *J Neurosurg* 2012;116:122-32.
 36. Kim JB, Lee JW, Choi KY, et al. Clinical characteristics of arteriovenous malformations of the head and neck. *Dermatol Surg* 2017;43:526-33.
 37. Couto JA, Huang AY, Konczyk DJ, et al. Somatic *MAP2K1* mutations are associated with extracranial arteriovenous malformation. *Am J Hum Genet* 2017;100:546-54.
 38. Bayrak-Toydemir P, McDonald J, Akarsu N, et al. A fourth locus for hereditary hemorrhagic telangiectasia maps to chromosome 7. *Am J Med Genet A* 2006;140:2155-62.
 39. Cole SG, Begbie ME, Wallace GM, et al. A new locus for hereditary haemorrhagic telangiectasia (*HHT3*) maps to chromosome 5. *J Med Genet* 2005;42:577-82.
 40. Sung HM, Chung HY, Lee SJ, et al. Clinical experience of the Klippel-Trenaunay syndrome. *Arch Plast Surg* 2015;42:552-8.
 41. Jacob AG, Driscoll DJ, Shaughnessy WJ, et al. Klippel-Trenaunay syndrome: spectrum and management. *Mayo Clin Proc* 1998;73:28-36.
 42. Luks VL, Kamitaki N, Vivero MP, et al. Lymphatic and other vascular malformative/overgrowth disorders are caused by somatic mutations in *PIK3CA*. *J Pediatr* 2015;166:1048-54.
 43. Mirzaa GM, Riviere JB, Dobyns WB. Megalencephaly syndromes and activating mutations in the *PI3K-AKT* pathway: *MPPH* and *MCAP*. *Am J Med Genet C Semin Med Genet* 2013;163C:122-30.
 44. Kurek KC, Luks VL, Ayturk UM, et al. Somatic mosaic activating mutations in *PIK3CA* cause *CLOVES* syndrome. *Am J Hum Genet* 2012;90:1108-15.
 45. Lindhurst MJ, Sapp JC, Teer JK, et al. A mosaic activating mutation in *AKT1* associated with the Proteus syndrome. *N Engl J Med* 2011;365:611-9.
 46. Amary MF, Damato S, Halai D, et al. Ollier disease and Maffucci syndrome are caused by somatic mosaic mutations of *IDH1* and *IDH2*. *Nat Genet* 2011;43:1262-5.