

Pediatric/Craniomaxillofacial/Head&Neck  
Image

## Application of nasal septal cartilage in a combined transorbital and transnasal approach for orbital wall reconstruction

Akinori Iwakami<sup>1</sup>, Goro Takada<sup>2</sup>, Norio Fukuda<sup>1</sup>, Hiroataka Asato<sup>3</sup>

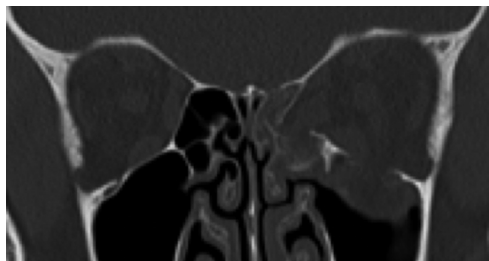<sup>1</sup>Division of Plastic and Reconstructive Surgery, Yamagata University Hospital, Yamagata; <sup>2</sup>Department of Plastic Surgery, Ashikaga Red Cross Hospital, Tochigi; <sup>3</sup>Department of Plastic and Reconstructive Surgery, Dokkyo Medical University, Tochigi, Japan

**Correspondence:** Akinori Iwakami  
Division of Plastic and Reconstructive Surgery, Yamagata University Hospital,  
2-2-2, Iidanishi, Yamagata 990-2331, Japan  
Tel: +81-23-628-5413, Fax: +81-23-628-5416, E-mail: aiwakami@dokkyomed.ac.jp

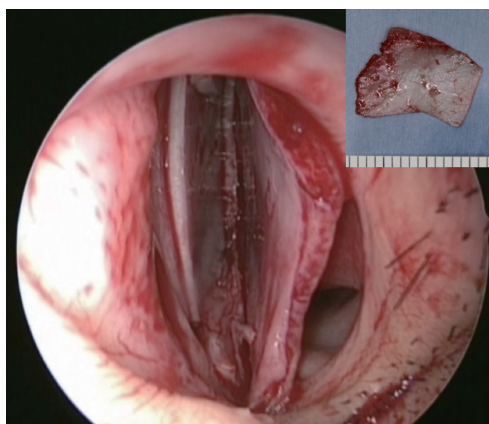
Received: June 23, 2020 • Revised: October 13, 2020 •  
Accepted: October 14, 2020  
pISSN: 2234-6163 • eISSN: 2234-6171  
<https://doi.org/10.5999/aps.2020.01312> • Arch Plast Surg 2021;48:217-218

Copyright © 2021 The Korean Society of Plastic and Reconstructive Surgeons  
This is an Open Access article distributed under the terms of the Creative Commons  
Attribution Non-Commercial License (<https://creativecommons.org/licenses/by-nc/4.0/>)  
which permits unrestricted non-commercial use, distribution, and reproduction in any  
medium, provided the original work is properly cited.

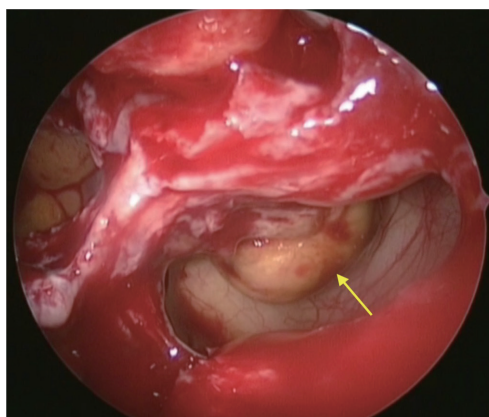
The combination of the transorbital and endoscopic transnasal approach for the reconstruction of orbital wall fractures has been modified to be less invasive after the introduction of functional endoscopic sinus surgery. Artificial materials or iliac bone was used as graft material in past studies [1-3]. Instead, we use nasal septal cartilage as the graft material; herein, we describe its usefulness with a representative case. A 25-year-old woman had a blunt orbital injury. Restriction of upward and downward movement of the left eyeball was accompanied by double vision. Computed tomography (CT) revealed herniated orbital tissue due to inferior and medial wall fractures (Fig. 1). Under general anesthesia, nasal septal cartilage was first harvested via endoscopy (Fig. 2). The orbital wall fractures were examined via an endoscopic transnasal and transconjunctival approach (Fig. 3). The herniated tissue was repositioned back into the orbit, and the bony defects were covered with the graft (Fig. 4). Postoperative eye movements were normal and double vision



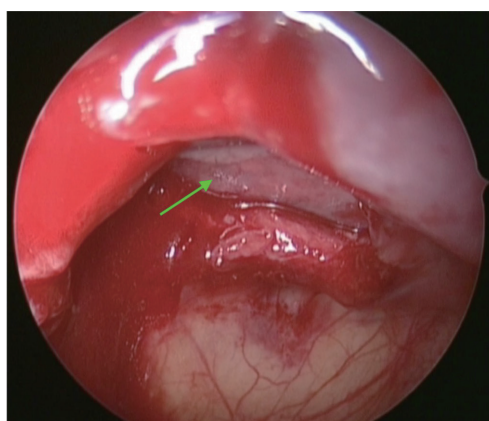
**Fig. 1.**  
Preoperative computed tomography.



**Fig. 2.**  
Nasal septal cartilage was harvested maximally with endoscopy.



**Fig. 3.**  
The fractures of the orbital walls and the herniated tissue (yellow arrow) were examined through the endoscopic transnasal approach.



**Fig. 4.**  
The herniated tissue was repositioned back into the orbit, and the bony defects were covered with the nasal septal cartilage (green arrow).

disappeared. An optimal cosmetic result was obtained without scarring or enophthalmos. Postoperative CT

showed no evidence of recurrence. Nasal septal cartilage can be the first choice as a graft material for orbital wall reconstruction in the combined approach. First, it can be easily harvested to its maximum size under clear endoscopic vision at the start of the transnasal approach. Second, the morbidity is minimal and no additional incision is necessary. Third, it is a thin, flexible, and tractable autologous graft. However, it is necessary to use another graft material for a considerably large defect since the size of the nasal septal cartilage is limited.

## Notes

### Conflict of interest

No potential conflict of interest relevant to this article was reported.

### Ethical approval

The study was performed in accordance with the principles of the Declaration of Helsinki. Written informed consent was obtained.

### Patient consent

The patient provided written informed consent for the publication and the use of her images.

### Author contribution

Writing original draft, data collection, reference review: A Iwakami. Review: G Takada. Final editing: N Fukuda, H Asato. Approval of final manuscript: all authors.

### ORCID

Akinori Iwakami

<https://orcid.org/0000-0001-9460-1509>

Goro Takada <https://orcid.org/0000-0002-3293-6212>

Norio Fukuda <https://orcid.org/0000-0003-1159-7677>

Hirota Asato <https://orcid.org/0000-0002-1880-1450>

## References

1. Woog JJ, Hartstein ME, Gliklich R. Paranasal sinus endoscopy and orbital fracture repair. *Arch Ophthalmol* 1998;116:688-91.
2. Kakibuchi M, Fukazawa K, Fukuda K, et al. Combination of transconjunctival and endonasal-transantral approach in the repair of blowout fractures involving the orbital floor. *Br J Plast Surg* 2004;57:37-44.
3. Lim NK, Kang DH, Oh SA, et al. Orbital wall restoring surgery in pure blowout fractures. *Arch Plast Surg* 2014;41:686-92.