

Giant cystadenoma of the floor of the mouth: A case report

Victor Labres da Silva Castro¹, Tiago Fernando Aires Corrêa², Valeriana de Castro Guimarães³, Gustavo Vasconcelos Nery², João Batista Ferreira⁴.

1) Doctor, Otolaryngology resident.

2) Otolaryngologist.

3) Health Science PhD student, Speech Therapist, Clinical Hospital - UFG.

4) Postdoctoral Fellow in Otolaryngology. Associate Professor, Department of Surgery, Faculty of Medicine-UFG. Head of Clinical Otorhinolaryngology-UFG.

Institution: Hospital of the Federal University of Goiás.
Goiânia / GO - Brazil.

Mailing address: Otorrinolaringologia - Hospital das Clínicas da Universidade Federal do Goiás - Primeira Avenida, s/n - Setor Leste Universitário - Zip code: 74605-020 - Goiânia / GO - Brazil - Telephone: (+55 62) 3269-8387 - E-mail: vlabres@hotmail.com

Article received August 25, 2010. Article accepted February 5, 2011.

SUMMARY

Introduction: Cystadenoma is an uncommon epithelial neoplasia that arises from the salivary glands. The malignancy can affect structures such as the larynx, nasopharynx, buccal mucosa, and palate.

Objective: To describe a case of a giant cystadenoma of the floor of the mouth treated at a public hospital in midwestern Brazil.

Case report: The patient was a 46-year-old woman with complaints of difficulties in articulating words and swallowing solid food and vocal fatigue. The progression of the disease since the initial consultation, the results of clinical examinations, and the outcome of surgery are described.

Finals Comments: Cystadenoma must be considered in the differential diagnosis of cystic injuries in the floor of the mouth if the patient's symptoms are suggestive of this malignancy.

Keywords: salivary glands; minor; mouth; mouth mucosa; exocrine glands.

INTRODUCTION

The salivary glands are formed by a set of exocrine glands that together excrete their secretions into the oral cavity (1). Tumors in this region are rare and of varied etiology, and they account for approximately 3% of all lesions in this region (2,3,4).

Benign tumors represent 75% of the lesions affecting salivary glands. The majority of these disorders (70%) appear in the parotid gland, with 22% appearing in the submandibular gland and 8% appearing in the minor salivary glands (4). There is no association between smoking and benign tumors of the salivary glands (4).

Cystadenoma is an uncommon epithelial neoplasm that arises from the salivary glands (5). The disease appears beginning in the 5th decade of life, with both men and women affected alike (2,3,4). The malignancy may affect structures such as the larynx, nasopharynx, oral mucosa, and palate; however, their manifestations are asymptomatic and painless (4).

This paper presents a relevant and unusual case in otorhinolaryngology distinguished by the rarity of its occurrence and the large size of its lesion.

In this report, we describe the case of a patient with a giant cystadenoma of the floor of the mouth who visited the Hospital of the Federal University of Goiás in Goiânia.

CASE REPORT

The patient was a 46-years-old woman born in Damianópolis (GO) who visited the otorhinolaryngology emergency department of the Hospital of the Federal University of Goiás HC/UFG in June 2006 with the following complaints: difficulty in articulating words, difficulty in swallowing solid foods, and vocal fatigue. No other otorhinolaryngology symptoms were identified.

The patient reported a worsening of the problem in recent months due to the increased volume of the floor of the mouth, which was affecting the swallowing of solid food. She also reported dissatisfaction with her current facial features and iron deficiency anemia due to the undertreatment of hypermenorrhea.

At the initial consultation, the patient had a good general condition with normal vital signs. On inspection and cervicofacial palpation, a volume increase in the submental and sublingual region of elastic-firm consistency that was painless to finger compression was identified. No

alterations in the neck were observed, and the absence of cervical lymphadenomegaly was confirmed. The presence of facial deformity characterized by protrusion of the submental and sublingual region was also identified.

In the previous clinical evaluation, both rhinolaryngoscopy and otoscopy revealed no changes. Via oropharyngoscopy, we observed a large mass of the cystic aspect occupying the entire floor of the mouth (Figure 1), with compression of the tongue toward the craniodorsal direction and without visualization of Wharton's duct papillae.

Nasopharyngolaryngoscopy revealed posterior displacement of the tongue base. No alterations were observed in the right nasal cavity, pharynx, or larynx.

Computed tomography (CT) scanning of the hemiface revealed a benign cystic lesion in the mouth floor with a hypodense, rounded appearance causing the posterior-superior displacement of the tongue. Magnetic resonance imaging (MRI) identified a bulky cystic mass in the supramandibular region (Figure 2).

In 2008, after prolonged hematologic treatment of anemia, the patient underwent surgery. With the diagnosis of a cystic lesion in the mouth floor, we opted for an intraoral surgical approach. After performing an accurate anterior incision in the mucosa of the mouth floor with careful dissection of the cystic capsule and complete excision of the lesion (Figure 3), approximation of the partially separated muscles and suture of the mucosa were performed with the placement of a drain for 24 h and a nasogastric tube for 3 days. In the immediate postoperative period, the patient displayed mild sublingual edema that was treated with prednisone 20 mg/day for 5 days.

Histopathological examination identified a cystic lesion lined by ciliated, cylindrical, flattened epithelium with atrophic areas separated by seromucous glands and papillary intracystic extensions. The benign cystic lesion originating in the minor salivary glands was comparable to a cystadenoma.

DISCUSSION

The interest in the description of this case is evidenced by the rarity of its occurrence as well as the conduct and outcome of the same. Several studies of cystadenoma have been performed in various areas of health. However, no studies similar to this study have been published.

The floor of the mouth can be compromised by a variety of injuries; many are major challenges to

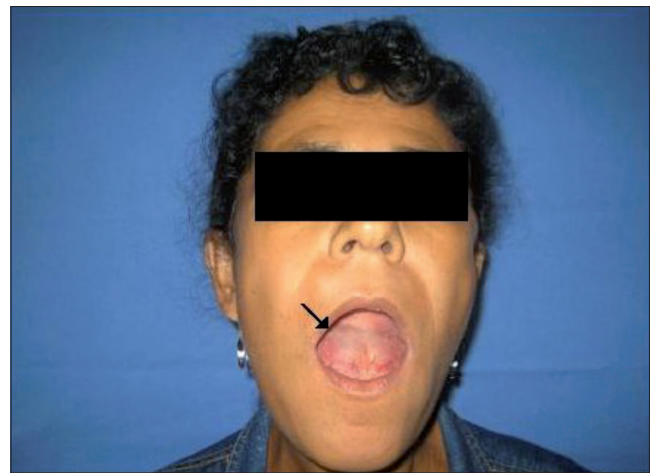

Figure 1. Patient with bulky lesion bulging floor of the mouth HC / UFG 2006.

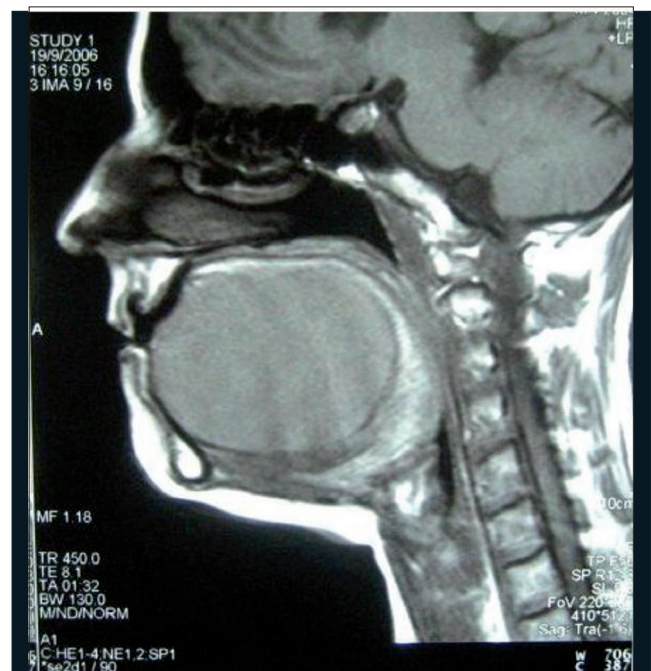


Figure 2. Nuclear Magnetic Ressonância. 2006.

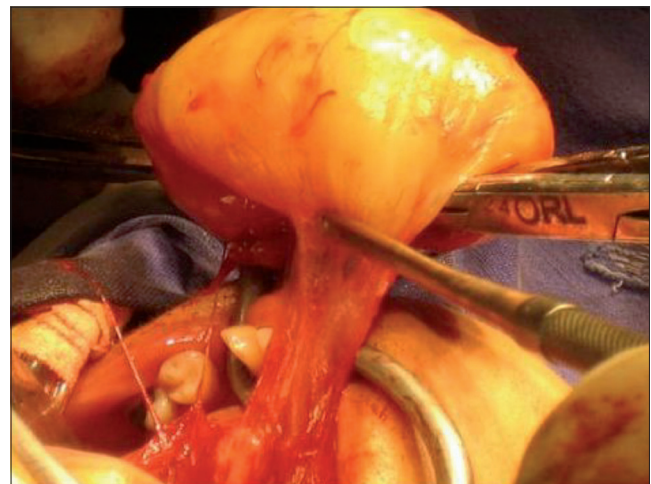

Figure 3. Surgical removal of the cyst. Capsule integrates. HC / UFG 2008.

professionals, leading to misdiagnosis and incorrect treatment (6).

Usually, cystic lesions located in this region are benign, and they arise from the salivary glands and are of varied origin, ranging from embryologic to neoplastic. They are characterized by insidious and progressive growth, and symptoms occur late in the pathogenesis when lesions reach a high volume (3,4,7). Similar to findings described in the literature, the patient sought medical attention years after the lesion developed, probably owing to the absence of symptoms.

Lesions in this region should be submitted to differential diagnosis to exclude the presence of other diseases such as ranula, neoplasms of the major and minor salivary glands, cystic hygroma, dermoid cysts, lipoma, and cellulite (7).

Cystadenoma is a rare benign epithelial neoplasm that commonly occurs in the parotid and minor salivary glands and affects the oral and labial mucosa (5). In our case, the tumor appeared on the floor of the mouth. In this region, the slow growth of tumors may delay medical care, which can lead to significant injuries resulting in the appearance of anatomical and functional changes such as alterations in speech, swallowing disorders, dyspnea, and cosmetic deformities, similar to the presented case.

Although the average age of patients diagnosed with cystadenoma is approximately 50 years, the literature also includes cases of patients with congenital cystadenomas (5,8). In this case, the patient reported that the cystadenoma had been present since childhood, which reinforces the hypothesis of a congenital cyst.

The diagnosis of the disease is based on the clinical evaluation of the lesion; however, imaging tests are useful for determining differences between cysts and solid tumors and demonstrating the location and extent of lesions, assisting in defining the clinical and surgical approach. However, these tests do not differentiate between benign and malignant lesions (9,10).

CT and MRI have similar sensitivity and specificity for assessing the location and infiltration of the tumor mass, and they can be performed to assess the involvement of deep spaces or contralateral glands (10). Prior knowledge of the boundaries and dimensions of the cyst in relation to the anatomy of the mouth floor are important aspects to be considered when planning surgery (7). In the present case, MRI identified a bulky, rounded, hypodense mass compatible with cystic lesions that caused posterior-superior displacement of the tongue. Thus, the proposed

surgery considered the results of imaging tests performed preoperatively.

Benign tumors of the salivary glands are treated by surgical excision of the lesion, the purpose of which is to correct cosmetic deformities and prevent complications such as nerve compression or malignant progression (4,5,8). The intraoral surgical approach is recommended for all cases of tumors in this region (7). In our patient, intraoral surgery was performed with careful and complete dissection of the lesion without damage to adjacent structures.

FINAL COMMENTS

Cystadenoma should be considered in the distinguishing diagnosis of cystic lesions in the floor of the mouth if the clinical findings are suggestive of this disease. The participation and cooperation of the patient, including attending all consultations and adhering to treatment, contribute to successful treatment.

REFERENCES

1. Barcellos KSA, Andrade LEC. Histopatologia e imunopatologia de glândulas salivares menores de pacientes com síndrome de Sjögren (SSj). *Rev Bras Reumatol.* 2005;45(4):215-223.
2. Santos GC, Martins MR, Pellacani LB, Vieira ACT, Nascimento LA, Abrahão M. Neoplasias de glândulas salivares: estudo de 119 casos. *J Bras Patol Med Lab.* 2003;39(4):371-375.
3. Lima SS, Soares AF, Amorim RFB, Freitas RA. Perfil epidemiológico das neoplasias de glândulas salivares: análise de 245 casos. *Rev Bras Otorrinolaringol.* 2005;71(3):335-340.
4. Ximenes Filho JA, Imamura R, Sennes LU. Neoplasias Benignas das Glândulas Salivares. *Rev Arq Int Otorrinolaringol.* 2002;6(3):225-32.
5. Takahashi Y, Kawano K, Yanagisawa S, Yokoyama S. Cystadenoma Arising from the Retromolar Region: A Case Report. *Oral science international.* 2008;5(1):61-64.
6. Tan MS, Singh B. Difficulties in diagnosing lesions in the floor of the mouth—report of two rare cases. *Ann Acad Med Singapore.* 2004 Jul;33(4 Suppl):72-6
7. DAntonio WEPA, Ikno CMY, Murakami MS, Sennes LU, Tsuji Domingos H. Cisto epidermóide gigante de assoalho de boca. *Rev Bras Otorrinolaringol.* 2000;66(1):63-6.

8. Pons Vicente O, Almendros Marqués N, Berini Aytés L, Gay Escoda C. Minor salivary gland tumors: A clinicopathological study of 18 cases. *Med Oral Patol Oral Cir Bucal*. 2008 Sep 1;13(9):E582-8.

9. Oh YS, Eisele DW. Salivary Glands Neoplasms. Em: Bailey BJ, Johnson JT, Newlands SD. *Head & Neck Surgery -*

Otolaryngology. 4th ed. Philadelphia: Lippincott Williams & Wilkins. 2006; pp. 1516-33.

10. Lee SC, Johnson JT. Salivary Glands Neoplasms. Disponível em <http://www.emedicine.com/ent/topic679.htm>.