Article published online: 2024-02-09

Surgical Treatment of Scaphoid Fractures: Recommendations for Management

Richard Samade, MD, PhD[1] Hisham M. Awan, MD[2]

[1] Department of Orthopaedic Surgery, Division of Hand and Upper Extremity Surgery, The University of Texas Southwestern Medical Center, Dallas, Texas
[2] Division of Hand and Upper Extremity Surgery, The Ohio State University Wexner Medical Center, Columbus, Ohio

Address for correspondence Hisham M. Awan, MD, Department of Orthopaedics, Division of Hand and Upper Extremity Surgery, Hand and Upper Extremity Center, The Ohio State University Wexner Medical Center, 915 Olentangy River Road, Columbus, OH 43212 (e-mail: hisham.awan@osumc.edu).

J Wrist Surg 2024;13:194–201.

Abstract

Background: Several operative treatments exist for scaphoid fractures, varying by approach (e.g., ercutaneous, volar, or dorsal), implant type (e.g., screw or Kirschner wire), and bone raft choice (e.g., none, nonvascularized, or vascularized). Many previous systematic eviews and meta-analyses have investigated outcomes following different surgicalÚpproaches, the use of vascularized versus nonvascularized bone graft for scaphoidßracture nonunions, and treatment for specific fracture patterns. However, given the advancements n scaphoid fracture treatment in recent years, there is a need for updated treatment recommendations hat would be beneficial to hand surgeons.

Purpose: We present a comprehensive review of the operative treatment of scaphoid fractures based on recent literature and propose a unified treatment algorithm for managing these fractures.

Methods: The English-language literature was searched from 2002 to 2023 for high evidence level (e.g., randomized trials), review, and meta-analysis articles with the following search terms: “scaphoid, ”u8220“scaphoid” AND “nonunion, ” and “scaphoid” AND “malunion. ” Each article was creened by the authors to determine the scaphoid fracture scenario addressed and ubsequent treatment recommendations. The findings from article reviews were then rganized by scaphoid fracture types in this manuscript.

Results: A total of 95 pertinent articles were ultimately selected and used as the basis for reviewing different scaphoid fracture scenarios. A treatment algorithm was then proposed based on literature review.

Conclusion: This summary of the recent literature can guide hand surgeons in addressing scaphoidßractures. Future research in scaphoid fracture treatment, particularly for nonunions, would be most beneficial n the form of systematic review, meta-analysis, or multicenter prospective randomized clinical trials.

Level of Evidence: IV

Keywords
- avascular necrosis
- bone graft
- humpback deformity
- nonunion
- scaphoid fracture

This document was downloaded for personal use only. Unauthorized distribution is strictly prohibited.

received
February 13, 2023
accepted
July 20, 2023
article published online
February 9, 2024

© 2024. Thieme. All rights reserved.
Thieme Medical Publishers, Inc., 333 Seventh Avenue, 18th Floor, New York, NY 10001, USA

DOI https://doi.org/10.1055/s-0043-1772689.
ISSN 2163-3916.

The retrograde blood supply to the scaphoid from the dorsal radial artery places proximal scaphoid fractures at a high risk of nonunion.[1] Specific patient risk factors have been implicated in fracture nonunion, such as delay in appropriate treatment[2] and current smoking status.[3,4] Fracture characteristics such as comminution at the fracture site and volar flexion (humpback) deformity can also heighten the risk of nonunion.[5] A large payer database study including data on 7,149 scaphoid fractures estimated an overall nonunion rate of 15.5%.[6] Left untreated, a persistent ununited scaphoid fracture progresses to scaphoid nonunion advanced collapse (SNAC) and arthrosis in 56% of patients after a mean follow-up of 36 years after injury.[7] Although surgical treatments for specific scaphoid fracture scenarios exist in the literature, an updated treatment algorithm, to our knowledge, has not been proposed.

We present a concise update of the treatment of various scaphoid fracture scenarios synthesized from a literature review, incorporating key findings from high-quality studies, systematic reviews, and meta-analyses. Our subsequent goal is to propose an algorithm for scaphoid fracture management, incorporating knowledge obtained from the literature review.

Materials and Methods

The authors searched the PubMed database (https://pubmed.ncbi.nlm.nih.gov/) for articles relevant to the surgical treatment of scaphoid fractures. Search terms used in the literature review included "scaphoid," "scaphoid AND nonunion," and "scaphoid AND malunion."

After this was performed, the titles and abstracts of retrieved articles were first assessed in order to ensure they were recent and pertinent. Thus, the following criteria for article inclusion in our literature view were applied: (1) articles must be in the English language; (2) publication dates were in the years 2002 to 2023; (3) full-text versions of the articles needed to be available for review; and (4) articles were high-evidence level (e.g., prospective randomized clinical trials [RCTs] representing level 1 evidence) or pertinent to a very specific scaphoid fracture scenario, meta-analysis, or review articles. If there was uncertainty regarding the suitability of an article after reviewing the title and abstract, the authors obtained and reviewed the full-text version of the article. A total of 95 articles were ultimately selected and used as the basis of the literature review in the following sections.

Results of Literature Review and Fracture Scenarios

Acute Nondisplaced Scaphoid Waist Fractures

When treated nonoperatively with casting less than 3 weeks after injury, acute nondisplaced scaphoid waist fractures exhibited union rates of 88 to 95%.[8] Siotos et al found no difference in nonunion rates between long and short arm casts and casts with and without thumb immobilization.[9] Grewal et al studied 172 patients treated with casting, showing a 99.4% union rate and a mean time to union (MTU) of 53 ± 37 days.[10]

Several investigations have compared casting to operative management of scaphoid waist fractures, such as a randomized comparison by Bond et al demonstrating an average time to union of 7 ± 0.5 weeks (following percutaneous screw fixation in 11 patients) versus 12 ± 0.7 weeks (after cast immobilization in 14 patients) for screw and cast treatments, respectively.[11] In the same study, time to return to work was 7 ± 0.7 versus 15 ± 0.7 weeks following screw fixation and casting, respectively.[11] Dias et al described a randomized comparison of casting (44 patients) and open reduction and internal fixation (ORIF) via a volar approach with screw fixation (44 patients) and found similar clinical outcomes.[12] Union was achieved in all 39 ORIF-treated patients followed to study completion and in 34 of the 44 cast-treated patients.[12] McQueen et al conducted a later randomized comparison of 30 patients treated with casting and 30 patients treated with percutaneous screw fixation and found no difference in union rate (97 vs. 87% for screw and cast treatment, respectively), grip, pinch, or range of motion (ROM) at 1 year.[13] However, the MTU was lower (9.2 vs. 13.9 weeks) and the mean time to return to full employment was also less (3.8 vs. 11.4 weeks) in those treated with screw fixation.[13] In the Scaphoid Waist Internal Fixation for Fractures Trial (SWIFFT) RCT studies, 219 patients with nondisplaced or minimally displaced (i.e., <2 mm) waist fractures were randomized to surgery and 220 to cast immobilization: by 12 weeks, 47% of those treated with surgery fully united in imaging compared to 22% treated with casting, but no difference in functional outcomes at 1 year was noted.[14–16] Other structured analyses of the literature have confirmed no clear difference in functional outcomes between surgical and nonsurgical treatment of these scaphoid fracture types.[17–20]

Displaced Scaphoid Waist Fractures (Aside from Nonunions)

Displacement of scaphoid waist fractures, by greater than 1 mm, has been associated with high rates of nonunion (55%) and avascular necrosis (AVN; 50%).[21] Thus, operative intervention is advised for displaced scaphoid waist fractures, which is supported by a meta-analysis reporting an odds ratio of 16.8 for nonunion following casting versus surgery.[22] Scaphoid fractures in these situations require attention to reduction and maintenance of fragments during fixation, which was accomplished with ORIF (using a volar approach and cannulated screw fixation) in a series of 35 patients and produced a 100% union rate within 4.0 ± 1.2 months.[23] Another series of acute displaced waist fractures, in 14 patients using ORIF with a Herbert screw or Kirschner wires and distal radius nonvascularized bone graft (NVBG), reported a 93% union rate with an MTU of 11.5 weeks.[24] Closed reduction and percutaneous screw fixation has also been used as a treatment for displaced waist fractures, with a 93% union rate and an MTU of 2.8 months in 14 patients successfully treated with this method.[25]

This document was downloaded for personal use only. Unauthorized distribution is strictly prohibited.

Scaphoid Waist Fracture Nonunions

Ununited scaphoid waist fractures have been typically treated by ORIF with bone grafting, which attained a 95% union rate in 26 patients (in a median time of 4 months) by utilizing an iliac crest BG (ICBG) wedge technique.[26] A later study on 22 patients treated with a volar approach, cannulated 3.5-mm screws, and ICBG achieved 100% union treating delayed unions (with an MTU of 19 weeks) and a 91% union rate treating nonunions.[27] A prospective RCT by Hegazy et al comparing 49 patients treated with ICBG to 49 patients with cancellous BG only found similar union rates, pain, and functional outcomes between the two groups.[28] Recent orthobiologic therapies utilizing mesenchymal stem cells[29] and bone morphogen proteins[30] have shown promise in scenarios with scaphoid fracture nonunions or revision operations.

In the last decade, VBGs have become an attractive option for facilitating the healing of fracture nonunions, with VBG based on the palmar carpal artery (PCA) achieving 100% union.[31] A different VBG, based on the pronator quadratus pedicle, achieved 100% union in 27 waist fracture nonunions, with an MTU of 11.5 weeks.[32] Despite these results with VBG, 100% union rates have been reported in 12 nonunions with an MTU of 14 weeks utilizing only limited debridement and distal radius cancellous BG.[33] Although a comparison of several VBGs in the literature have demonstrated union rates from 86 to 94%,[34] other reviews of studies have cast doubt on clear superiority in union rates and functional outcomes of VBGs over NVBGs.[35–38]

Volar flexion (humpback) deformity is usually associated with significant bone loss and malalignment leading to dorsal intercalated segment instability (DISI), which requires correction to decrease pain, increase wrist mobility, facilitate union, and arrest progression to arthritis.[39] Furthermore, the presence of DISI can pose a risk of failure to VBGs.[40] Volar plate fixation has been used to stabilize these humpback deformity fractures: in 20 patients treated with plating and volar distal radius VBG, a 90% union rate was achieved with an MTU of 4.7 ± 4.5 months.[41] In contrast, screw fixation with cancellous distal radius BG achieved 100% union in 12 patients.[42] Despite these encouraging results with NVBG methods, a meta-analysis of 5,246 cases of nonunions demonstrated an 80% union rate with NVBG alone, 84% union rate with NVBG and fixation, and 91% with VBG.[43] Moreover, VBG has been demonstrated as a successful primary procedure (98.2% union rates with waist nonunions with an MTU of 9.2 weeks).[44]

Despite the aforementioned success rates of most VBGs, the often-utilized distal radius VBGs experience a 50% failure rate in situations where waist nonunion, proximal AVN, and humpback deformity are present together.[45] In these scenarios, a meta-analysis of 48 articles by Pinder et al showed that medial femoral condyle (MFC) VBG could achieve 100% union rates,[46] with a later systematic review demonstrating 93% united at a mean time of 15.6 weeks.[47] A similar union rate (94%) is seen in the recently described medial femoral trochlear graft.[48]

Proximal Pole Scaphoid Fractures

Operative treatment has typically been advised for proximal pole scaphoid fractures due to the decreased vascularity of the proximal portion.[49] In 17 patients with an acute proximal scaphoid fracture (with 4 being displaced), Rettig and Raskin performed ORIF with a single screw (using distal radius BG in 14 cases) and achieved 100% union with an MTU of 10 weeks.[50] Displacement of proximal pole fractures can significantly delay healing, with Brogan et al showing 70% union for nondisplaced fractures and only 23% union for displaced fractures (at 14 weeks postoperatively).[51] As suggested by Chong et al, inconsistencies in studies describing the location of the fracture may underlie many of these heterogenous outcomes with union.[52]

Before treating a scaphoid fracture proximal pole nonunion (PPNU), it is important to determine if AVN is present. Lim et al evaluated distal radius VBG for small proximal pole fragments (mean size 21% of the scaphoid) with AVN and achieved an 86% union rate with an MTU of 14 weeks.[53] With these findings, dorsal ORIF with VBG (based on the 1,2-intercompartmental supraretinacular artery) has been advocated as a treatment for PPNU with AVN,[54] although cancellous BG has been examined as well.[55]

When AVN is not present, PPNUs have been treated successfully with NVBG, with a study by Luchetti et al highlighting a 90% union rate in 20 PPNUs using distal radius BG and screw fixation.[56] Using a capsular-based VBG, in contrast to NVBG, has been found to achieve an 85% union rate (with an MTU of 12.3 weeks) in an 89-patient series of PPNUs.[57]

Salvage Options

When persistent scaphoid fractures with nonunion and findings of SNAC are present, several salvage options are available and guided by the degree of bone loss and arthritis.[58] For SNAC affecting the radioscaphoid joint alone, radial styloidectomy with scaphocapitolunate arthrodesis is one option, shown to decrease pain and Disabilities of the Arm, Shoulder, and Hand (DASH) scores (without progressive arthrosis), in 20 patients.[59] Distal scaphoid resection is another option: 19 patients treated with this option exhibited a mean visual analog scale (VAS) score for pain of 0.9, grip strength of 83% of the contralateral wrist, wrist ROM of 79% of the contralateral wrist, and no development of radiolunate arthritis,[60] with a meta-analysis demonstrating 93% of patients returning to work in a mean time of 6.9 weeks.[61]

Once SNAC progresses beyond the radioscaphoid joint, other treatment options, such as proximal row carpectomy (PRC) and four-corner arthrodesis (4CF), should be considered. Mulford et al reviewed 52 articles, finding that both PRC and 4CF improve pain.[62] However, greater postoperative ROM, fewer complications, and less risk of subsequent arthritis were found following PRC compared to 4CF.[62]

Role of Arthroscopic Techniques in Treating Scaphoid Fractures

In the 1990s, Dr. Terry Whipple reviewed the use of arthroscopy to guide the placement of a cannulated Herbert screw to

This document was downloaded for personal use only. Unauthorized distribution is strictly prohibited.

fixate scaphoid fractures and allow contact athletes to return to sport 1 week postoperatively.[63,64] Taras et al also described arthroscopic-assisted fixation as an option in athletes, but cautioned that the technique be employed only in select cases[65] Gupta et al recommended percutaneous fixation with arthroscopic-assisted reduction for minimally displaced scaphoid fractures,[66] with all 15 acute fractures having healed in a study by Shih et al.[67] Slade et al proposed a dorsal approach for percutaneous screw fixation, achieving 100% union in 27 cases at an average of 12 weeks.[68] Further details of the Slade technique and a comparison to the other techniques were provided by Geissler and Hammit,[69] Geissler,[70] and Monaghan.[71] This dorsal approach was used in more challenging injury patterns, such as scaphoid fractures associated with perilunate injuries, with encouraging results.[72–75] Only one randomized trial comparing nondisplaced scaphoid waist fractures treated with either casting or arthroscopic-assisted fixation was done (with a minimum follow-up of 4 years); it demonstrated potential improved function in the short term, but with a risk of radioscaphoid arthritis, with surgery.[76,77] Arthroscopy has also been described in assisting fixation of scaphoid fracture nonunions, described by Ruch et al in a case series for proximal pole fractures[78] and then explicated in more detail.[79] Scaphoid fracture nonunion treatment was further explored by Slade et al using a dorsal approach.[80] Arthroscopy with different grafts have achieved high union rates: using BG substitute (93%),[81] distal radius autograft (94%),[82] iliac crest autograft (96%),[83] and olecranon autograft (100%).[84] Numerous review articles are available for further review dedicated to arthroscopic scaphoid fracture treatment along with other wrist pathologies[85–88] and toward scaphoid fractures specifically[89] with discussions of treating nonunion scenarios.[90–92] A recent detailed review of the history and technique of arthroscopic-assisted scaphoid nonunion repair was outlined by Nakamura et al.[93]

Proposed Treatment Algorithm and Discussion

By synthesizing the aforementioned data from the literature and case series, we propose an algorithm for managing scaphoid fractures, as depicted in ►**Fig. 1**. The preceding diagnostic workup could utilize the algorithm detailed by Kawamura and Chung.[8] Initially, radiographs would be screened for signs of SNAC: if an advanced stage of SNAC is present, one should consider salvage procedures such as PRC and 4CF.

For acute nondisplaced waist fractures, information on the patient's activities of daily living and occupational needs (such as the need to facilitate return to sport[94]) should be gathered, and the surgeon should thoroughly review the risks and benefits of cast immobilization versus percutaneous screw fixation with the patient. Arthroscopy or three-dimensional printed guides[95,96] may be useful fixation adjuncts, per surgeon familiarity and preference. Nondisplaced waist

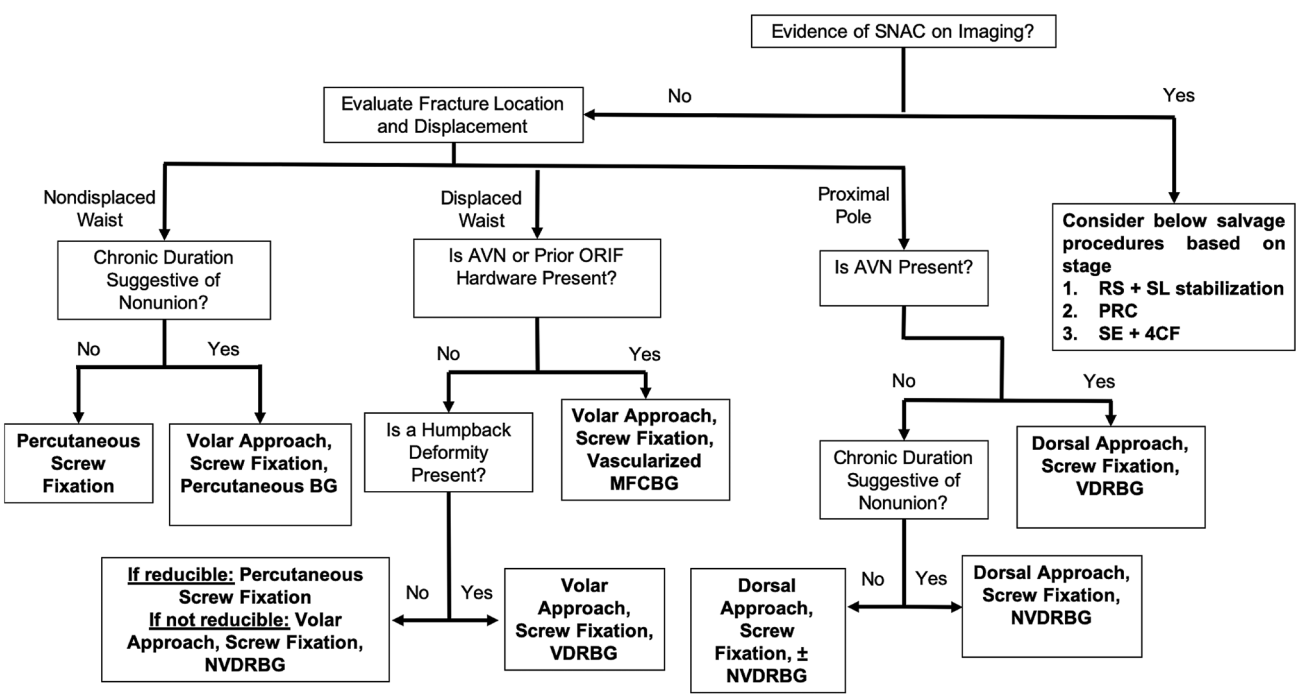

Fig. 1 Treatment algorithm summarizing recommendations based on data from our literature review. Course of treatment is dependent on the presence of scaphoid nonunion advanced collapse, fracture location, fracture displacement, injury chronicity suggestive of nonunion or delayed union, presence of avascular necrosis, and presence of volar flexion (humpback) deformity. AVN, avascular necrosis; MFCBG, medial femoral condyle bone graft; NVDRBG, nonvascularized distal radius bone graft; ORIF, open reduction and internal fixation; RS + SL stabilization, radial styloidectomy + scapholunate stabilization; PRC, proximal row carpectomy; SE + 4CF, scaphoid excision and four-corner arthrodesis; SNAC, scaphoid nonunion advanced collapse; VDRBG, vascularized distal radius bone graft.

 © 2024. Thieme. All rights reserved.

This document was downloaded for personal use only. Unauthorized distribution is strictly prohibited.

nonunions would undergo a limited volar approach to visualize the fracture site, debrided as appropriate, and fixation with a single screw with ipsilateral distal radius NVBG applied if there is concern about stability.[97] Other possible fixation constructs in this scenario include bioabsorbable screws,[98] multiple Kirshner wires,[99] and plate–screw combinations.[100]

An MFC VBG with screw fixation would be advantageous for displaced waist fractures with AVN (diagnosed on radiographs or magnetic resonance imaging [MRI]), via a volar approach, to visualize and correct any humpback deformity that is present as well as revascularize the proximal pole. If AVN is not present, but humpback deformity is, then a volar approach with distal radius VBG or NVBG (based on surgeon preference) and screw fixation would be used. Acute and chronic (i.e., nonunion) displaced waist fractures without AVN or humpback deformity could be adequately treated with either closed reduction and percutaneous screw fixation (if reducible under fluoroscopy) or a volar approach with screw fixation and NVBG from the distal radius (if it is irreducible under fluoroscopy).

Proximal pole fractures with AVN would benefit from a VBG and screw fixation, but a dorsal approach could provide adequate visualization and distal radius VBG should provide a high rate of successful union while preserving MFC VBG if subsequent nonunion occurs. For PPNU, ipsilateral distal radius NVBG should be strongly considered, but acute cases could utilize NVBG if significant comminution is noted intraoperatively.

Ideally, a future set of multicenter randomized clinical trials assessing the efficacy of different approaches, fixation methods, BGs, and postoperative protocols would inform a future and comprehensive treatment algorithm with high-level evidence. Certainly, the aforementioned recommendations reflect a compilation of findings reported on the treatment of scaphoid fractures in a methodical review of the literature. Furthermore, it is supplemented by the cumulative experience of the co-authors, who are fellowship-trained hand and upper extremity surgeons. A systematic reappraisal of the evidence summarized in this article by convened expert panels of hand surgeons could be a logical next step toward adopting clinical practice guidelines, similar to what was done for distal radius fractures.[101] We concur with Pinder et al[46] that it would be difficult to obtain the large patient numbers necessary for these trials. In lieu of this route, we recommend continued high-quality surgical technique descriptions and cohort studies (ideally prospective) of novel scaphoid fracture treatments, with detailed data collection of patient demographics, fracture characteristics, and fixation and bone grafting used as proposed by Ferguson et al.[102] Subsequent meta-analyses and systematic reviews of those enhanced primary studies can then provide further guidance on optimal scaphoid fracture treatments.

Statement of Human and Animal Rights

All procedures followed were in accordance with the ethical standards of the responsible committee on human experimentation (institutional and national) and with the Helsinki Declaration of 1975, as revised in 2008.

Statement of Informed Consent

Informed consent was not required for this study.

Ethical Committee Statement

This manuscript did not require the approval of the Biomedical Institutional Review Board of The Ohio State University.

Funding

None declared.

Conflict of Interest

None declared.

References

1 Lee S. Fractures of the carpal bones. In: Wolfe S, Pederson W, Hotchkiss R, Kozin S, Cohen M, eds. Green's Operative Hand Surgery. 7th ed. Philadelphia, PA: Elsevier; 2017
2 Wong K, von Schroeder HP. Delays and poor management of scaphoid fractures: factors contributing to nonunion. J Hand Surg Am 2011;36(09):1471–1474
3 Little CP, Burston BJ, Hopkinson-Woolley J, Burge P. Failure of surgery for scaphoid non-union is associated with smoking. J Hand Surg [Br] 2006;31(03):252–255
4 Konstantinidis I, Christidis P, Konstantinou P, et al. The influence of smoking on healing of scaphoid non-union after a vascularized pedicle bone flap operation: a review and meta-analysis. Orthop Rev (Pavia) 2022;14:35446
5 Grewal R, Suh N, MacDermid JC. The missed scaphoid fracture-outcomes of delayed cast treatment. J Wrist Surg 2015;4(04): 278–283
6 Zura R, Xiong Z, Einhorn T, et al. Epidemiology of fracture nonunion in 18 human bones. JAMA Surg 2016;151(11):e162775
7 Düppe H, Johnell O, Lundborg G, Karlsson M, Redlund-Johnell I. Long-term results of fracture of the scaphoid. A follow-up study of more than thirty years. J Bone Joint Surg Am 1994;76(02): 249–252
8 Kawamura K, Chung KC. Treatment of scaphoid fractures and nonunions. J Hand Surg Am 2008;33(06):988–997
9 Siotos C, Asif M, Lee J, et al. Cast selection and non-union rates for acute scaphoid fractures treated conservatively: a systematic review and meta-analysis. J Plast Surg Hand Surg 2023;57(1–6):16–21
10 Grewal R, Suh N, MacDermid JC. Is casting for non-displaced simple scaphoid waist fracture effective? A CT based assessment of union. Open Orthop J 2016;10:431–438
11 Bond CD, Shin AY, McBride MT, Dao KD. Percutaneous screw fixation or cast immobilization for nondisplaced scaphoid fractures. J Bone Joint Surg Am 2001;83(04):483–488
12 Dias JJ, Wildin CJ, Bhowal B, Thompson JR. Should acute scaphoid fractures be fixed? A randomized controlled trial. J Bone Joint Surg Am 2005;87(10):2160–2168
13 McQueen MM, Gelbke MK, Wakefield A, Will EM, Gaebler C. Percutaneous screw fixation versus conservative treatment for fractures of the waist of the scaphoid: a prospective randomised study. J Bone Joint Surg Br 2008;90(01):66–71
14 Dias JJ, Brealey SD, Fairhurst C, et al. Surgery versus cast immobilisation for adults with a bicortical fracture of the scaphoid waist (SWIFFT): a pragmatic, multicentre, open-label, randomised superiority trial. Lancet 2020;396(10248):390–401
15 Dias J, Brealey S, Cook L, et al. Surgical fixation compared with cast immobilisation for adults with a bicortical fracture of the scaphoid waist: the SWIFFT RCT. Health Technol Assess 2020;24 (52):1–234

 © 2024. Thieme. All rights reserved.

This document was downloaded for personal use only. Unauthorized distribution is strictly prohibited.

16 Hinde S, Richardson G, Fairhurst C, et al. Cost-effectiveness of surgery versus cast immobilization for adults with a bicortical fracture of the scaphoid waist: an economic evaluation of the SWIFFT trial. Bone Joint J 2021;103-B(07):1277–1283
17 Li H, Guo W, Guo S, Zhao S, Li R. Surgical versus nonsurgical treatment for scaphoid waist fracture with slight or no displacement: a meta-analysis and systematic review. Medicine (Baltimore) 2018;97(48):e13266
18 Al-Ajmi TA, Al-Faryan KH, Al-Kanaan NF, et al. A systematic review and meta-analysis of randomized controlled trials comparing surgical versus conservative treatments for acute undisplaced or minimally-displaced scaphoid fractures. Clin Orthop Surg 2018;10(01):64–73
19 Chen S, Zhang C, Jiang B, Mi Y, Zhu Y, Jia X. Comparison of conservative treatment and surgery treatment for acute scaphoid fracture: a meta-analysis of randomized controlled trials. World J Surg 2023;47(03):611–620
20 Johnson NA, Fairhurst C, Brealey SD, et al. One-year outcome of surgery compared with immobilization in a cast for adults with an undisplaced or minimally displaced scaphoid fracture: a meta-analysis of randomized controlled trials. Bone Joint J 2022;104-B(08):953–962
21 Szabo RM, Manske D. Displaced fractures of the scaphoid. Clin Orthop Relat Res 1988;(230):30–38
22 Singh HP, Taub N, Dias JJ. Management of displaced fractures of the waist of the scaphoid: meta-analyses of comparative studies. Injury 2012;43(06):933–939
23 Trumble TE, Gilbert M, Murray LW, Smith J, Rafijah G, McCallister WV. Displaced scaphoid fractures treated with open reduction and internal fixation with a cannulated screw. J Bone Joint Surg Am 2000;82(05):633–641
24 Rettig ME, Kozin SH, Cooney WP. Open reduction and internal fixation of acute displaced scaphoid waist fractures. J Hand Surg Am 2001;26(02):271–276
25 Matson AP, Garcia RM, Richard MJ, Leversedge FJ, Aldridge JM, Ruch DS. Percutaneous treatment of unstable scaphoid waist fractures. Hand (N Y) 2017;12(04):362–368
26 Daly K, Gill P, Magnussen PA, Simonis RB. Established nonunion of the scaphoid treated by volar wedge grafting and Herbert screw fixation. J Bone Joint Surg Br 1996;78(04):530–534
27 Inaparthy PK, Nicholl JE. Treatment of delayed/nonunion of scaphoid waist with Synthes cannulated scaphoid screw and bone graft. Hand (N Y) 2008;3(04):292–296
28 Hegazy G, Massoud AH, Seddik M, et al. Structural versus nonstructural bone grafting for the treatment of unstable scaphoid waist nonunion without avascular necrosis: a randomized clinical trial. J Hand Surg Am 2021;46(06):462–470
29 Toosi S, Naderi-Meshkin H, Moradi A, et al. Scaphoid bone nonunions: clinical and functional outcomes of collagen/PGA scaffolds and cell-based therapy. ACS Biomater Sci Eng 2023;9 (04):1928–1939
30 Polmear MM, Anderson AB, Lanier PJ, Orr JD, Nesti LJ, Dunn JC. Bone morphogenetic protein in scaphoid nonunion: a systematic review. J Wrist Surg 2021;10(03):184–189
31 Dailiana ZH, Malizos KN, Zachos V, Varitimidis SE, Hantes M, Karantanas A. Vascularized bone grafts from the palmar radius for the treatment of waist nonunions of the scaphoid. J Hand Surg Am 2006;31(03):397–404
32 Lee SK, Park JS, Choy WS. Scaphoid fracture nonunion treated with pronator quadratus pedicled vascularized bone graft and headless compression screw. Ann Plast Surg 2015;74(06): 665–671
33 McInnes CW, Giuffre JL. Fixation and grafting after limited debridement of scaphoid nonunions. J Hand Surg Am 2015;40 (09):1791–1796
34 Tsantes AG, Papadopoulos DV, Gelalis ID, Vekris MD, Pakos EE, Korompilias AV. The efficacy of vascularized bone grafts in the treatment of scaphoid nonunions and Kienbock disease: a systematic review in 917 patients. J Hand Microsurg 2019;11 (01):6–13
35 Fujihara Y, Yamamoto M, Hidaka S, Sakai A, Hirata H. Vascularised versus non-vascularised bone graft for scaphoid nonunion: meta-analysis of randomised controlled trials and comparative studies. JPRAS Open 2022;35:76–88
36 Testa G, Lucenti L, D'Amato S, et al. Comparison between vascular and non-vascular bone grafting in scaphoid nonunion: a systematic review. J Clin Med 2022;11(12):3402
37 Zhang H, Gu J, Liu H, Yuan C. Pedicled vascularized versus non-vascularized bone grafts in the treatment of scaphoid nonunion: a meta-analysis of comparative studies. ANZ J Surg 2021;91(11):E682–E689
38 Duncumb JW, Robinson PG, Williamson TR, et al. Bone grafting for scaphoid nonunion surgery: a systematic review and meta-analysis. Bone Joint J 2022;104-B(05):549–558
39 Mathoulin CL, Arianni M. Treatment of the scaphoid humpback deformity - is correction of the dorsal intercalated segment instability deformity critical? J Hand Surg Eur Vol 2018;43 (01):13–23
40 Rancy SK, Wolfe SW, Jerome JTJ. Predictors of failure for vascularized and nonvascularized bone grafting of scaphoid nonunions: a systematic review. J Hand Microsurg 2021;14(04): 322–335
41 Dodds SD, Williams JB, Seiter M, Chen C. Lessons learned from volar plate fixation of scaphoid fracture nonunions. J Hand Surg Eur Vol 2018;43(01):57–65
42 Cohen MS, Jupiter JB, Fallahi K, Shukla SK. Scaphoid waist nonunion with humpback deformity treated without structural bone graft. J Hand Surg Am 2013;38(04):701–705
43 Munk B, Larsen CF. Bone grafting the scaphoid nonunion: a systematic review of 147 publications including 5,246 cases of scaphoid nonunion. Acta Orthop Scand 2004;75(05): 618–629
44 Gras M, Mathoulin C. Vascularized bone graft pedicled on the volar carpal artery from the volar distal radius as primary procedure for scaphoid non-union. Orthop Traumatol Surg Res 2011;97(08):800–806
45 Chang MA, Bishop AT, Moran SL, Shin AY. The outcomes and complications of 1,2-intercompartmental supraretinacular artery pedicled vascularized bone grafting of scaphoid nonunions. J Hand Surg Am 2006;31(03):387–396
46 Pinder RM, Brkljac M, Rix L, Muir L, Brewster M. Treatment of scaphoid nonunion: a systematic review of the existing evidence. J Hand Surg Am 2015;40(09):1797–1805.e3
47 Zhou KJ, Graham DJ, Stewart D, Lawson RD, Sivakumar BS. Free medial femoral condyle flap for reconstruction of scaphoid nonunion: a systematic review. J Reconstr Microsurg 2022;38 (08):593–603
48 Sivakumar B, Lawson R, Graham DJ. The medial femoral trochlea osteochondral flap for scaphoid reconstruction: a systematic review. Hand (N Y) 2023:15589447231151430
49 Xiao Z, Xiong G, Zhang W. New findings about the intrascaphoid arterial system. J Hand Surg Eur Vol 2018;43(10):1059–1065
50 Rettig ME, Raskin KB. Retrograde compression screw fixation of acute proximal pole scaphoid fractures. J Hand Surg Am 1999;24 (06):1206–1210
51 Brogan DM, Moran SL, Shin AY. Outcomes of open reduction and internal fixation of acute proximal pole scaphoid fractures. Hand (N Y) 2015;10(02):227–232
52 Chong HH, Kulkarni K, Shah R, Hau MYT, Athanatos L, Singh HP. A meta-analysis of union rate after proximal scaphoid fractures:

This document was downloaded for personal use only. Unauthorized distribution is strictly prohibited.

terminology matters. J Plast Surg Hand Surg 2022;56(05): 298–309
53 Lim TK, Kim HK, Koh KH, Lee HI, Woo SJ, Park MJ. Treatment of avascular proximal pole scaphoid nonunions with vascularized distal radius bone grafting. J Hand Surg Am 2013;38(10): 1906–12.e1
54 Kakar S, Shin AY. Ununited fracture of the proximal pole of the scaphoid with avascular necrosis. J Hand Surg Am 2011;36(09): 1522–1524, quiz 1525
55 Putnam JG, DiGiovanni RM, Mitchell SM, Castañeda P, Edwards SG. Plate fixation with cancellous graft for scaphoid nonunion with avascular necrosis. J Hand Surg Am 2019;44(04):339. e1–339.e7
56 Luchetti TJ, Rao AJ, Fernandez JJ, Cohen MS, Wysocki RW. Fixation of proximal pole scaphoid nonunion with non-vascularized cancellous autograft. J Hand Surg Eur Vol 2018;43(01): 66–72
57 Papatheodorou LK, Sotereanos DG. Treatment for proximal pole scaphoid nonunion with capsular-based vascularized distal radius graft. Eur J Orthop Surg Traumatol 2019;29(02):337–342
58 Buijze GA, Ochtman L, Ring D. Management of scaphoid nonunion. J Hand Surg Am 2012;37(05):1095–1100, quiz 1101
59 Klausmeyer M, Fernandez D. Scaphocapitolunate arthrodesis and radial styloidectomy: a treatment option for posttraumatic degenerative wrist disease. J Wrist Surg 2012;1(02):115–122
60 Malerich MM, Catalano LW III, Weidner ZD, Vance MC, Eden CM, Eaton RG. Distal scaphoid resection for degenerative arthritis secondary to scaphoid nonunion: a 20-year experience. J Hand Surg Am 2014;39(09):1669–1676
61 Mayfield CK, Gould DJ, Dusch M, Mostofi A. Distal scaphoid excision in treatment of symptomatic scaphoid nonunion: systematic review and meta-analysis. Hand (N Y) 2019;14(04): 508–515
62 Mulford JS, Ceulemans LJ, Nam D, Axelrod TS. Proximal row carpectomy vs four corner fusion for scapholunate (SLAC) or scaphoid nonunion advanced collapse (SNAC) wrists: a systematic review of outcomes. J Hand Surg Eur Vol 2009;34(02): 256–263
63 Whipple TL. The role of arthroscopy in the treatment of wrist injuries in the athlete. Clin Sports Med 1992;11(01):227–238
64 Whipple TL. The role of arthroscopy in the treatment of wrist injuries in the athlete. Clin Sports Med 1998;17(03):623–634
65 Taras JS, Sweet S, Shum W, Weiss LE, Bartolozzi A. Percutaneous and arthroscopic screw fixation of scaphoid fractures in the athlete. Hand Clin 1999;15(03):467–473
66 Gupta R, Bozentka DJ, Osterman AL. Wrist arthroscopy: principles and clinical applications. J Am Acad Orthop Surg 2001;9 (03):200–209
67 Shih JT, Lee HM, Hou YT, Tan CM. Results of arthroscopic reduction and percutaneous fixation for acute displaced scaphoid fractures. Arthroscopy 2005;21(05):620–626
68 Slade JF III, Gutow AP, Geissler WB. Percutaneous internal fixation of scaphoid fractures via an arthroscopically assisted dorsal approach. J Bone Joint Surg Am 2002;84-A(Suppl 2):21–36
69 Geissler WB, Hammit MD. Arthroscopic aided fixation of scaphoid fractures. Hand Clin 2001;17(04):575–588, viii
70 Geissler WB. Arthroscopic management of scaphoid fractures in athletes. Hand Clin 2009;25(03):359–369
71 Monaghan BA. Uses and abuses of wrist arthroscopy. Tech Hand Up Extrem Surg 2006;10(01):37–42
72 Park MJ, Ahn JH. Arthroscopically assisted reduction and percutaneous fixation of dorsal perilunate dislocations and fracture-dislocations. Arthroscopy 2005;21(09):1153
73 Caloia MF, Gallino RN, Caloia H, Rivarola H. Incidence of ligamentous and other injuries associated with scaphoid fractures during arthroscopically assisted reduction and percutaneous fixation. Arthroscopy 2008;24(07):754–759
74 Kim JP, Lee JS, Park MJ. Arthroscopic reduction and percutaneous fixation of perilunate dislocations and fracture-dislocations. Arthroscopy 2012;28(02):196–203.e2
75 Oh WT, Choi YR, Kang HJ, Koh IH, Lim KH. Comparative outcome analysis of arthroscopic-assisted versus open reduction and fixation of trans-scaphoid perilunate fracture dislocations. Arthroscopy 2017;33(01):92–100
76 Jørgsholm P, Thomsen NO, Björkman A, Besjakov J, Abrahamsson SO. The incidence of intrinsic and extrinsic ligament injuries in scaphoid waist fractures. J Hand Surg Am 2010;35(03):368–374
77 Clementson M, Jørgsholm P, Besjakov J, Thomsen N, Björkman A. Conservative treatment versus arthroscopic-assisted screw fixation of scaphoid waist fractures: a randomized trial with minimum 4-year follow-up. J Hand Surg Am 2015;40(07): 1341–1348
78 Ruch DS, Chang DS, Poehling GG. The arthroscopic treatment of avascular necrosis of the proximal pole following scaphoid nonunion. Arthroscopy 1998;14(07):747–752
79 Ruch DS, Chang DS, Yang CC. Arthroscopic evaluation and treatment of scaphoid nonunion. Hand Clin 2001;17(04): 655–662, x
80 Slade JF III, Geissler WB, Gutow AP, Merrell GA. Percutaneous internal fixation of selected scaphoid nonunions with an arthroscopically assisted dorsal approach. J Bone Joint Surg Am 2003; 85-A(Suppl 4):20–32
81 Chu PJ, Shih JT. Arthroscopically assisted use of injectable bone graft substitutes for management of scaphoid nonunions. Arthroscopy 2011;27(01):31–37
82 Kim JP, Seo JB, Yoo JY, Lee JY. Arthroscopic management of chronic unstable scaphoid nonunions: effects on restoration of carpal alignment and recovery of wrist function. Arthroscopy 2015;31(03):460–469
83 Oh WT, Kang HJ, Chun YM, Koh IH, Lee YJ, Choi YR. Retrospective comparative outcomes analysis of arthroscopic versus open bone graft and fixation for unstable scaphoid nonunions. Arthroscopy 2018;34(10):2810–2818
84 Waitayawinyu T, Lertcheewanan W, Boonyasirikool C, Niempoog S. Arthroscopic treatment of scaphoid nonunion with olecranon bone graft and screw fixation leads to union and improved outcomes. Arthroscopy 2022;38(03):761–772
85 Bain GI, Munt J, Turner PC. New advances in wrist arthroscopy. Arthroscopy 2008;24(03):355–367
86 Wolf JM, Dukas A, Pensak M. Advances in wrist arthroscopy. J Am Acad Orthop Surg 2012;20(11):725–734
87 Slutsky DJ. Current innovations in wrist arthroscopy. J Hand Surg Am 2012;37(09):1932–1941
88 Kakar S, Burnier M, Atzei A, Ho PC, Herzberg G, Del Piñal F. Dry wrist arthroscopy for radial-sided wrist disorders. J Hand Surg Am 2020;45(04):341–353
89 Slutsky DJ, Trevare J. Use of arthroscopy for the treatment of scaphoid fractures. Hand Clin 2014;30(01):91–103
90 Jegal M, Kim JS, Kim JP. Arthroscopic management of scaphoid nonunions. Hand Surg 2015;20(02):215–221
91 Ecker J. Scaphoid union: the role of wrist arthroscopy. Hand Clin 2017;33(04):677–686
92 Wong WC, Ho PC. Arthroscopic management of scaphoid nonunion. Hand Clin 2019;35(03):295–313
93 Nakamura T, Cheong Ho P, Atzei A, Corella F, Haugstvedt JR. Revolutions in arthroscopic wrist surgeries. J Hand Surg Eur Vol 2022;47(01):52–64
94 Goffin JS, Liao Q, Robertson GA. Return to sport following scaphoid fractures: a systematic review and meta-analysis. World J Orthop 2019;10(02):101–114
95 Guo Y, Tian G, Zlotolow DA, Tian W, Zhong W, Sun L. A cadaveric study on the accuracy of an individualized guiding template to assist scaphoid fixation using computed tomography and 3-dimensional printing. J Hand Surg Am 2019;44(03):251.e1–251.e6

This document was downloaded for personal use only. Unauthorized distribution is strictly prohibited.

96 Guo Y, Ma W, Zlotolow D, Wang C, Tong D, Liu K. A comparison between robotic-assisted scaphoid screw fixation and a freehand technique for acute scaphoid fracture: a randomized, controlled trial. J Hand Surg Am 2022;47(12):1172–1179
97 Elgayar L, Elmajee M, Aljawadi A, Abdelaal A, Khan S, Pillai A. A systematic review of mechanical stabilization by screw fixation without bone grafting in the management of stable scaphoid non-union. J Clin Orthop Trauma 2021;17:112–117
98 Feeley A, Feeley I, Ni Fhoghlú C, Sheehan E, Kennedy M. Use of biomaterials in scaphoid fracture fixation, a systematic review. Clin Biomech (Bristol, Avon) 2021;89:105480
99 Hegazy G, Alshal E, Abdelaal M, et al. Kirschner wire versus Herbert screw fixation for the treatment of unstable scaphoid waist fracture nonunion using corticocancellous iliac bone graft: randomized clinical trial. Int Orthop 2020;44(11): 2385–2393
100 Morgan SDJ, Sivakumar BS, Graham DJ. Scaphoid plating for recalcitrant scaphoid fractures: a systematic review. J Hand Surg Eur Vol 2021;46(06):616–620
101 Watters WC, Sanders JO, Murray J, Patel NMembers of the Writing, Review, and Voting Panels of the AUC on the Treatment of Distal Radius Fractures. The American Academy of Orthopaedic Surgeons Appropriate Use Criteria on the treatment of distal radius fractures. J Bone Joint Surg Am 2014;96(02):160–161
102 Ferguson DO, Shanbhag V, Hedley H, Reichert I, Lipscombe S, Davis TR. Scaphoid fracture non-union: a systematic review of surgical treatment using bone graft. J Hand Surg Eur Vol 2016;41 (05):492–500

This document was downloaded for personal use only. Unauthorized distribution is strictly prohibited.

 © 2024. Thieme. All rights reserved.